Supplement to

May 2014

Cataract & Refractive Surgery TODAY

EUROPE

Sponsored by AcuFocus, Inc.

EXTENDING DEPTH OF FOCUS

Corneal Inlay Experts Discuss Best Practices for Achieving Reliable, Long-Lasting Presbyopia Correction

Contributors

Waleed Al-Tuwairqi, MD, *is a Senior Ophthalmology Consultant at Elite Hospital in Riyadh, Saudi Arabia. Dr. Al-Tuwairqi has implanted about 70 KAMRA inlays to date. He states that he has no financial interest in the products or companies mentioned. He may be reached at e-mail: wstelite@hotmail.com.*

Perry S. Binder, MS, MD, *is a volunteer faculty member at the Gavin Herbert Eye Institute at the University of California, Irvine, Medical School, and the Medical Monitor for AcuFocus. Dr. Binder may be reached at e-mail: garrett23@aol.com.*

John Blaylock, MD, FRCSC, *is Medical Director of Valley Laser Eye Centre in Abbotsford, British Columbia, Canada. Dr. Blaylock has implanted approximately 40 KAMRA inlays. He states that he has no financial interest in the products or companies mentioned. Dr. Blaylock may be reached at e-mail: jfblaylock@vlec.ca.*

Francesco Carones, MD, *is Medical Director of the Centro Oftalmo-Chirurgico Carones in Milan, Italy. Dr. Carones has implanted about 200 KAMRA inlays since 2010 and states that he is an advisor to AcuFocus. He may be reached at e-mail: fcarones@carones.com.*

Wayne Crewe-Brown, MD, *is Clinical Director of the Optilase Group in Belfast, Ireland. Dr. Crewe-Brown has performed more than 500 KAMRA Vision procedures and serves on the AcuFocus Global Medical Advisory Board. He may be reached at e-mail: waynecrewebrown@gmail.com.*

Günther Grabner, MD, *is Professor and Director of the University Eye Clinic at Paracelsus Medical University in Salzburg, Austria. Dr. Grabner was one of the first surgeons in the world to implant the AcuFocus inlay and has performed about 150 cases to date. He states that he has no financial interest in the products or companies mentioned. He may be reached at e-mail: G.Grabner@salk.at.*

Jong Ho Lee, MD, *is CEO of BalGeunSeSang Eye Clinic in Seoul and Busan, South Korea. Dr. Lee has implanted more than 200 KAMRA inlays. He states that he has no financial interest in the products or companies mentioned. He may be reached at e-mail: ljh2355@gmail.com.*

Joon Hyun Kim, MD, PhD, *is co-owner of the Shine & Bright Eye Center in South Korea. Dr. Kim has implanted more than 120 KAMRA inlays since they became commercially available in Korea. He states that he has no financial interest in the products or companies mentioned. He may be reached at e-mail: joshua0219@hotmail.com.*

David Kent, MD, *is in private practice at Fendalton Eye Clinic in Christchurch, New Zealand. Dr. Kent served as an international clinical investigator in the IDE clinical trial, beginning in 2009, and has implanted the inlay commercially since its approval in New Zealand in 2011. He may be reached at e-mail: david@lasik.co.nz.*

Richard L. Lindstom, MD*, is Adjunct Professor Emeritus of the Department of Ophthalmology at the University of Minnesota, Minneapolis, and the Founder of Minnesota Eye Consultants in Minneapolis. Dr. Lindstrom states that he is a member of the AcuFocus Board of Directors and Scientific Advisory Board. He may be reached at e-mail: rllindstrom@mneye.com.*

Jeffery J. Machat, MD, FRCSC, *is the Founder and Chief Medical Director of Crystal Clear Vision in Toronto, Canada. Dr. Machat has a KAMRA inlay in his own eye (implanted by Minoru Tomita, MD, PhD) and has performed the procedure for more than 160 patients in his presbyopia-focused practice. He states that he has no financial interest in the products or companies mentioned. Dr. Machat may be reached at e-mail: jeff.machat@crystalclearvision.com.*

Jay S. Pepose, MD, PhD, *is Director of the Pepose Vision Institute and Professor of Clinical Ophthalmology at Washington University School of Medicine in St. Louis, Missouri. Dr. Pepose has implanted 25 inlays as an investigator in the US clinical trial and states that he is a member of the AcuFocus Global Medical Advisory Board. He may be reached at e-mail: jpepose@peposevision.com.*

Wolfgang Riha, MD, *is in practice at Sehkraft Eye Center in Cologne, Germany. Dr. Riha has been involved in clinical trials of small-aperture inlays since 2007 and has implanted about 250 inlays in his current refractive practice. He also trains new KAMRA surgeons around the world. He is a member of the AcuFocus Medical Advisory Board. Dr. Riha may be reached at e-mail: riha@sehkraft.de.*

Guillermo Rocha, MD, FRCSC, *is Medical Director of Ocular Microsurgery and Laser Center in Brandon, and Attending Surgeon at Image Plus Laser Center in Winnipeg, both in Manitoba, Canada. Dr. Rocha has been implanting KAMRA inlays commercially since approval in Canada in late 2012. He states that he has no financial interest in the products or companies mentioned. Dr. Rocha may be reached at e-mail: rochag@me.com.*

Marco Rossi, MD, *practices at VistaMonza Vision Laser Center in Monza, Italy. In the past year, Dr. Rossi has implanted nearly 100 KAMRA inlays. He states that he has no financial interest in the products or companies mentioned. He may be reached at e-mail: marcorossi0558@gmail.com.*

Minoru Tomita, MD, PhD, *is Medical Director of the Minoru Tomita Eye Clinic Ginza in Tokyo. Dr. Tomita has implanted more than 10,000 KAMRA inlays and has helped to refine both the inlay technology and techniques for implantation. He serves on the AcuFocus Global Medical Advisory Board and may be reached at e-mail: harvardmedical1972@gmail.com.*

Richard von Volkmann, MD, *is in private practice at the Åsane Eye Clinic in Ulset, Norway. Dr. von Volkmann has been implanting the KAMRA inlay commercially for about 1 year. He states that he has no financial interest in the products or companies mentioned. He may be reached at e mail: Volkmann@online.no.*

John A. Vukich, MD, *is Surgical Director at the Davis Duehr Dean Center for Refractive Surgery in Madison, Wisconsin, and Chair of the AcuFocus Global Medical Advisory Board. He may be reached at e-mail: javukich@gmail.com.*

Roger Zaldivar, MD, *is President and Scientific Director of Instituto Zaldivar in Mendoza, Argentina. Dr. Zaldivar has implanted about 50 KAMRA inlays and states that he serves as a member of the AcuFocus Global Medical Advisory Board. He may be reached at e-mail: zaldivar@zaldivar.com.*

The KAMRA Inlay: A Global Perspective

BY RICHARD L. LINDSTROM, MD

By 2020, there will be 2.1 billion presbyopes worldwide, many of whom are eager to improve their near vision and reduce their spectacle dependence. The KAMRA inlay (AcuFocus) provides an excellent option for this population.

Corneal inlays are additive technologies that do not remove tissue; implantation is minimally invasive and they are also removable.

The KAMRA inlay relies on the principle of small-aperture optics to increase the eye's depth of focus (Figure 1). It is implanted in the nondominant eye to improve near and intermediate visual acuity with minimal compromise to distance vision.

The current-generation inlay, just 5 µm thin, is the culmination of years of significant technological advancements. The inlay has now been studied in a wide range of patients, including natural emmetropes, post-LASIK emmetropes, ametropes (in conjunction with a LASIK correction) and pseudophakes after implantation of a monofocal IOL. Results from many of these studies have been peer-reviewed and published.

Because the KAMRA inlay is commercially available in 50 countries, we also now have extensive registry data of real-world outcomes for thousands of commercial procedures performed worldwide.

As with any novel ophthalmic technology, both the device and techniques for implanting it have evolved considerably over the years. The small-aperture inlay has progressed along this iterative continuum even faster than many other technologies on which we all rely, from IOLs and phacoemulsification systems to excimer and femtosecond lasers.

Today's state-of-the-art KAMRA procedure includes inlay implantation into a lamellar pocket at or deeper than 200 µm, created with a femtosecond laser using 6 X 6 spot/line separation (or the equivalent). When combined with LASIK, the procedure should be done using a dual-interface technique, where the excimer correction is performed under a thin flap and the inlay is implanted at least 100 µm below in a pocket interface. Surgeons should aim for a postoperative refraction in the inlay eye of -0.75 D and plano in the fellow eye and use an appropriate postoperative topical steroid and dry eye regimen.

When these guidelines are followed, patients achieve J2 for near and 20/20 to 20/25 for distance, with a high level of satisfaction. Current approaches have increased the speed of visual recovery and reduced complications and the rate of inlay removal to levels comparable with presbyopia-correcting IOLs.

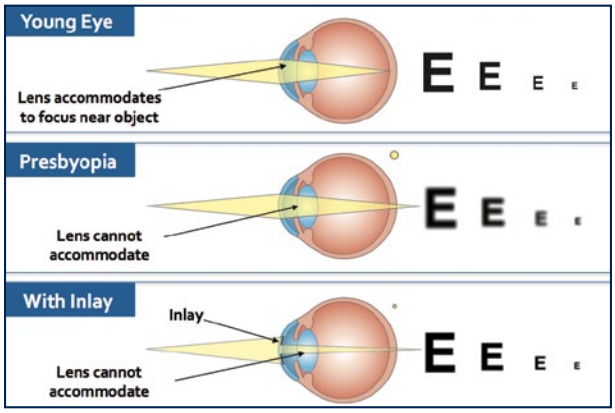

Figure 1. The small-aperture design allows central paraxial light to reach the retina without interference from competing focal points or defocused light. This effect results in an uninterrupted extended depth of focus.

Physicians implanting the inlay must understand that this is a unique procedure to LASIK, with different postoperative findings and potential complications. The presbyopic patient population is an older one, with a higher incidence of dry eye and lenticular changes; these patients must be managed accordingly. One should not jump to conclusions from any one data point but take all elements of the exam into consideration when evaluating an individual's response to and visual gains from an inlay.

In this supplement, we have gathered the expert opinions and collective wisdom of surgeons from around the world who have extensive experience implanting the KAMRA inlay. I hope you will find it to be a roadmap for success, providing important insights into best practices for patient selection, intraoperative considerations, and effective postoperative management. ■

Richard L. Lindstom, MD, is Adjunct Professor Emeritus of the Department of Ophthalmology at the University of Minnesota, Minneapolis, and the Founder of Minnesota Eye Consultants in Minneapolis. Dr. Lindstrom states that he is a member of the AcuFocus Board of Directors and Scientific Advisory Board. He may be reached at e-mail: rllindstrom@mneye.com.

An Elegant Solution to Presbyopia

KAMRA inlay implantation reliably extends depth of focus.

BY JOHN A. VUKICH, MD

The KAMRA corneal inlay is an elegant solution for the ubiquitous problem of presbyopia. The current-generation inlay, which is commercially available in 50 countries, is 5 µm thin, with a 1.6-mm aperture and a total diameter of 3.8 mm. Through the well-known principle of small-aperture optics, it increases depth of focus to enhance near vision (Figure 1).

Near acuity can be further enhanced with a slightly myopic refractive target of -0.75 D in the inlay eye. This shifts the defocus curve to optimize it for near vision, and the small aperture eliminates distance blur from this amount of myopia. The inlay does not split light between near, intermediate, and distance focal points, and patients maintain binocular summation despite monocular implantation in the nondominant eye. The result is good near vision with minimal compromise in distance vision.

VISUAL RESULTS

Recent data suggest that patients enjoy a wider range of functional vision and better contrast sensitivity with the inlay than with an accommodating or diffractive multifocal IOL (Figure 1).[1]

In the Investigational Device Exemption (IDE) clinical trial, the inlay was implanted monocularly in 507 naturally emmetropic patients, either in a corneal pocket or under a thick corneal flap. Near, intermediate, and distance mean uncorrected monocular acuity at 3 years was J2, 20/25, and 20/20, respectively. Binocular uncorrected distance acuity was 20/16.

From this study and from a global registry of procedures performed commercially, we have gained valuable experience in preoperative patient selection, surgical technique, and postoperative management. One key lesson is that the best results are achieved with a high-quality lamellar pocket created with a femtosecond laser.

Results from nearly 9,000 commercial pocket procedures demonstrate that patients gain an average of 3 lines at 1 week and an additional line at 1 month, resulting in an average near UCVA of 20/28. The mean distance UCVA was 20/20 (Figure 2). These results are maintained over time, and there was no change in distance BCVA.

CONCLUSION

Although there is no perfect solution to presbyopia, the KAMRA inlay is an excellent option for our presbyopic patients, as it closely approximates the effortless range of near and distance vision that young emmetropes enjoy. ■

John A. Vukich, MD, is Surgical Director at the Davis Duehr Dean Center for Refractive Surgery in Madison, Wisconsin, and Chair of the AcuFocus Global Medical Advisory Board. He may be reached at e-mail: javukich@gmail.com.

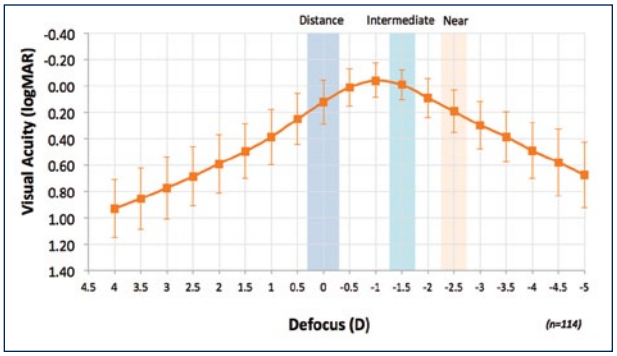

Figure 1. The small-aperture extends depth of focus, resulting in continuous functional vision across all distances. This result is enhanced when paired with a small amount of myopia, as demonstrated in this image.

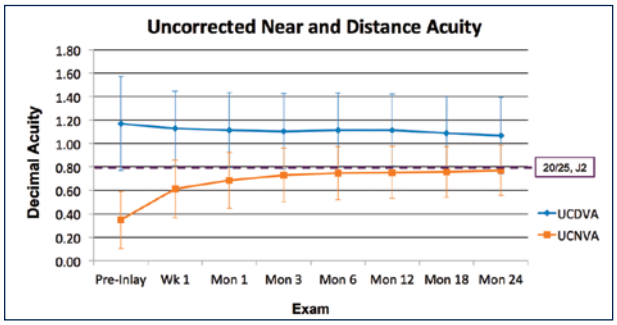

Figure 2. The global KAMRA Data Registry shows that patients implanted with the KAMRA inlay achieve an average result of 0.8 decimal (J2) for near UCVA and 1.1 decimal (20/25) distance UCVA, which is maintained over time. The registry includes more than 8,000 eyes at month 1, more than 6,000 eyes at month 6, nearly 4,000 eyes at month 12, and more than 700 eyes at month 24.

EXPERT ROUNDTABLE: BEST PRACTICES IN CORNEAL INLAY SURGERY

Moderator: John A. Vukich, MD
Panelists: Perry S. Binder, MS, MD; Günther Grabner, MD; and Guillermo Rocha, MD

John A. Vukich, MD: How do today's technology and implantation techniques compare with your earlier experience with small-aperture inlays?

Perry S. Binder, MS, MD: I have been involved with corneal inlay development since the 80s. The KAMRA small-aperture inlay has, by far, the largest numbers and longest follow-up of any inlay technology to date. There is robust data available, much of it already in the published literature. The company has been able to use the power of that data to continuously improve the technology and guidelines for its use.

Günther Grabner, MD: Since I began implanting small-aperture inlays 7 years ago, we have learned a lot about the ideal implantation depth for the inlay, the best target refraction, and the implantation methods that result in better outcomes.

> With the current pocket implantation technique, we see much less postoperative dry eye and have better refractive predictability and stability.
> – Guillermo Rocha, MD

Guillermo Rocha, MD: The move to pocket implantation has been particularly beneficial. Although well-selected patients did fine with the inlay positioned under a 200-µm flap, I was never comfortable with the concept of a thick flap. With the current pocket implantation technique, we see much less postoperative dry eye and have better refractive predictability and stability.

Vukich: What near and distance visual performance do you expect to provide to your KAMRA patients?

Rocha: After surgery, patients have between J1 and J2 near vision with minimal compromise to distance acuity. Using eye models, Artal et al[2] demonstrated that the combination of a small-aperture inlay with some residual myopia provides the greatest range of vision. This is reflected in my experience: There is a slight decrease in distance UCVA in the implanted eye, but patients do not typically note any change in binocular distance vision.

Grabner: We did not know that early on. Some patients whom we thought were emmetropic and had the procedure years ago were actually mild hyperopes (±0.50 D). Targeting slight myopia in the inlay eye makes this a long-lasting solution to presbyopia (Figure 1) . With the current guidelines for surgery, we expect patients to end up with 20/25 distance and J2 near vision.

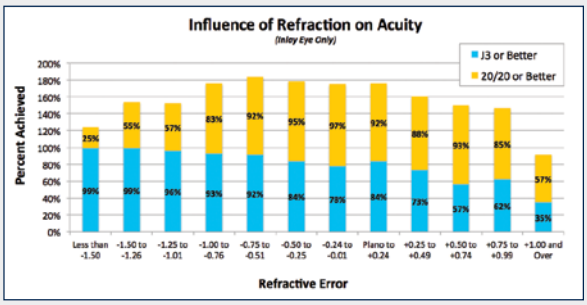

Figure 1. The best simultaneous near and distance vision is achieved when inlay implantation is paired with a small amount of myopia in the inlay-implanted eye.
Source: Global KAMRA Data Registry.

What is also nice is how broadly applicable this procedure is. Because we can combine it with LASIK, it is suitable for emmetropes, hyperopes, myopes, and even for post-LASIK presbyopes or pseudophakes who want better near vision.

Vuckich: What is the long-term viability of this technology?

Grabner: We now have 5- to 7-year follow-up on our initial series of 32 patients. Although patients received an earlier version of the inlay and did not benefit from the technique refinements made in the past few years, their vision remains stable as a result of the novel small-aperture design.

Binder: The polyvinylidene difluoride material of the KAMRA inlay is highly biocompatible and stable in the eye. I have performed scanning electron microscopy on removed inlays. Beyond a normal coating of proteoglycans, there were few fibroblasts or keratocytes on the anterior surface and none at all on the posterior, concave smooth surface of the inlays. There also have not been any cases of corneal thinning or melting with the 5-µm technology. These facts suggest the inlay is relatively inert, which bodes well for its long-term viability.

Vukich: How does the KAMRA inlay compare with other options you can offer presbyopes?

Grabner: What sets the inlay apart is that it can be easily removed. We will never achieve 100% success with any procedure. When a patient is dissatisfied with refractive lens exchange, presbyopic LASIK, or monovision LASIK, he or she is either stuck with the unsatisfactory outcome or must undergo additional invasive intraocular or tissue removal surgery to correct it. I have not removed many inlays, but it is reassuring to me—and my patients—to know that I can remove it if necessary.

1. Pepose J. Comparison of depth of focus and mesopic contrast sensitivity in small-aperture inlay, accommodating IOL, and multifocal IOL patients. Poster presented at: the 2014 Annual Symposium, American Society of Cataract and Refractive Surgery; Boston; April 25–29, 2014.
2. Tabernero J, Artal P. Optical modeling of a corneal inlay in real eyes to increase depth of focus: Optimum centration and residual defocus. *J Cataract Refract Surg.* 2012;38(2):270–277.

Perfecting the KAMRA Procedure

Implantation techniques have rapidly evolved.

BY WAYNE CREWE-BROWN, MD

Techniques for implanting the KAMRA inlay have rapidly evolved as surgeons gain more experience with this technology. We know now that a small amount of myopia in the inlay eye combined with plano in the fellow eye is ideal (Figure 1). To achieve this, many patients require an additional LASIK procedure. At first, the combined LASIK-KAMRA (CLK) procedures were performed simultaneously, under a 200-µm lamellar flap; however, many of us disliked operating under a thick flap.

Today, the AcuFocus Global Medical Advisory Board recommends that the inlay always be implanted in a corneal pocket.

If excimer laser correction is also required, it should be performed under a thin femtosecond laser flap and the inlay inserted into a lamellar pocket at least 100 µm below the LASIK interface. This dual-interface approach allows us to fine tune patients' refractions and capitalize on the advantages of thin-flap LASIK and deep-pocket implantation.

The AcuFocus Global Medical Advisory Board recommends that the inlay always be implanted in a corneal pocket. If excimer laser correction is also required, it should be performed under a thin femtosecond laser flap and the inlay inserted into a lamellar pocket at least 100 µm below the LASIK interface.

ADVANTAGES

The advantages of the pocket procedure over a thick flap include simplified centration, improved refractive stability and predictability, lower incidence of dry eye, and faster visual recovery for greater patient satisfaction. Visual outcomes are better, and the rate of inlay removal is significantly lower.

Femtosecond laser developments have contributed to the success of inlay surgery. Specifically, we have found that laser settings should be adjusted to 6 X 6 or tighter spot/line separation (or equivalent) for the smoothest beds and best outcomes.

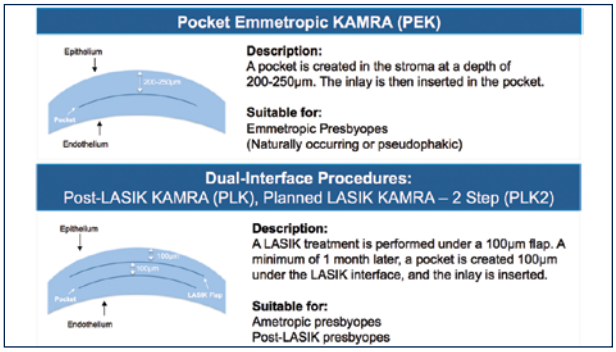

Figure 1. Pocket procedures for KAMRA inlay implantation.

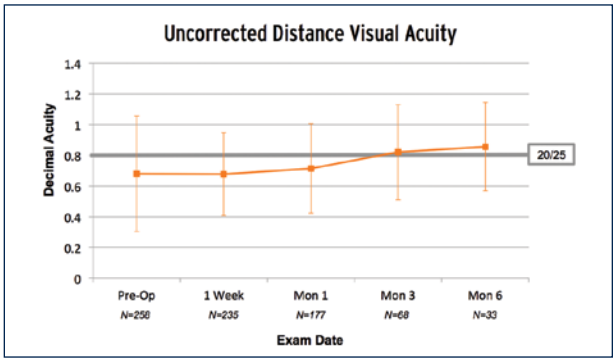

Figure 2. Mean distance UCVA remains constant in the early postoperative period and shows improvement over time.

RETROSPECTIVE CHART REVIEW

In a recent retrospective chart review of my results in 162 patients undergoing monocular pocket implantation of the KAMRA inlay with LASIK, mean near UCVA in the implanted eye improved 4 lines from preoperative to 1 week postoperative. Mean distance UCVA and BCVA remained unchanged at 20/25 and 20/20, respectively, at all time points (Figure 2).

These are the outcomes we can expect to achieve with today's state-of-the-art inlay technology and techniques. ■

Wayne Crewe-Brown, MD, is Clinical Director of the Optilase Group in Belfast, Ireland. Dr. Crewe-Brown has performed more than 500 KAMRA Vision procedures and serves on the AcuFocus Global Medical Advisory Board. He may be reached at e-mail: waynecrewebrown@gmail.com.

EXPERT ROUNDTABLE: STATE-OF-THE-ART INLAY SURGERY

Moderator: Wayne Crewe-Brown, MD
Panelists: David Kent, MD; Minoru Tomita, MD, PhD; and Waleed Al-Tuwairqi, MD

Wayne Crewe-Brown, MD: What was your experience in transitioning from flap to pocket with the KAMRA inlay?

Minoru Tomita, MD, PhD: Combined LASIK and KAMRA (CLK) under a 200-µm flap greatly expanded the range of patients suitable for the inlay, with good results.[1,2] However, by moving to all-pocket inlay implantation and separating the two procedures into a planned two-step process (pocket implantation plus thin-flap LASIK; PLK-2), the results are even better. Our removal rate has decreased from 5% with flaps to 1.5% with pockets.

> My rate of complications dropped dramatically after moving to pockets, and I have not had a single case in the past year that required removal or enhancement. Patients are happy, and so am I.
> – David Kent, MD

David Kent, MD: Surgeons who began with the single-step CLK procedure grew frustrated with the prolonged recovery and high incidence of dry eye. My experience was that these patients did not do as well as the emmetropes in whom I implanted the inlay in a corneal pocket. They were more likely to have a hyperopic shift or lose BCVA.

My removal rate with flaps was significant. Based on Dr. Tomita's experience, I changed in February 2012 to PLK-2, and I also began using a femtosecond laser with dedicated pocket software and a tight spot/line separation.

My rate of complications dropped dramatically after moving to pockets, and I have not had a single case in the past year that required removal or enhancement. Patients are happy, and so am I.

Waleed Al-Tuwairqi, MD: The pocket cuts fewer corneal nerves and, in many eyes, can be made even deeper than 200 µm, which is a metabolically quieter level of the cornea. Implanting an inlay under a flap is not ideal for either inlay positioning or for ablating the cornea with the excimer laser; I am more satisfied with pocket surgery.

Crewe-Brown: How do you center the inlay during the pocket implantation procedure?

Al-Tuwairqi: After assessing the centration information provided by the AcuTarget HD instrument (AcuFocus), I mark my target centration location using a PTK spot with the excimer laser and ink marking. This technique can be seen in my 2013 ASCRS Film Festival Champion video (http://youtube/LPseUwsyLy8).

Kent: Centering accurately under a flap was challenging and likely contributed to some of the loss of BCVA we saw. I find centration in a pocket much easier, as you can visualize the first Purkinje and pupil throughout the inlay insertion process, with superior results.

Crewe-Brown: With a planned two-step procedure, how long do you wait between performing LASIK and implanting the inlay?

Tomita: We wait 1 month in order to give us the best control over the achieved refraction.

Kent: We also do them 1 month apart. Although not a requirement, I think it is worthwhile to measure the flap with anterior segment optical coherence tomography or an excimer laser system that measures flap thickness intraoperatively. Even though today's femtosecond lasers are good, there is still some variation in flap thickness. I like to have a precise measurement so that I can plan for at least 100 µm between the flap interface and the pocket.

Crewe-Brown: Besides pocket implantation, what else do you consider part of a state-of-the-art KAMRA procedure?

Al-Tuwairqi: Patient selection is key. This procedure works remarkably well when surgeons do a comprehensive exam and adhere to the preoperative criteria. You must be strict about ruling out anyone with severe dry eye, central lens opacity, or abnormal topgography. You must also follow the guidelines for pocket surgery with thin flaps, use an advanced femtosecond laser with high-quality pocket capability, and use appropriate steroids postoperatively. When you do all this, you will have happy patients.

1. Tomita M, Kanamori T, Waring GO 4th, et al. Simultaneous corneal inlay implantation and laser in situ keratomileusis for presbyopia in patients with hyperopia, myopia, or emmetropia: Six-month results. *J Cataract Refract Surg.* 2012;38(3):495-506.
2. Tomita M, Kanamori T, Waring GO 4th, et al. Small-aperture corneal inlay implantation to treat presbyopia after laser in situ keratomileusis. *J Cataract Refract Surg.* 2013;39(6):898-905.

Targeting Excellent Near and Distance UCVA

It is important to pay close attention to the method of refraction.

BY WOLFGANG RIHA, MD

Presbyopic patients seeking a corneal inlay are motivated primarily by a desire for better near vision. As surgeons, we want to help them meet that goal without compromising their distance vision. Thanks to two important technique modifications in recent years, the KAMRA small-aperture inlay, in my experience, does this effectively.

The important modifications include targeting mild myopia in the inlay eye (combined with emmetropia in the distance eye) and pocket implantation.

A recent analysis of commercial (ie, nonstudy) pocket procedures with the KAMRA inlay showed that 99.6% of patients had a distance BCVA of 20/25 or better at 12 and 24 months (Figure 1) and that only 1.03% lost 2 or more lines at 24 months. This excellent result can give surgeons confidence that distance vision is maintained in real-world practice.

When I first began implanting corneal inlays 7 years ago, we selected emmetropes in the -0.75 to +0.50 D range. Over time, we have learned that patients obtain the best possible vision when the inlay eye is between -0.50 and -1.00 D. This provides an average near UCVA of 20/28 by 1 month.

With more than -1.00 D of defocus, patients lose some distance acuity; any less and near vision is not as satisfactory. Fortunately, combining thin-flap LASIK and pocket inlay implantation allows us to correct refractive error to the ideal range while the inlay treats the patient's presbyopia.

With this latest procedure, postoperative vision is stable. At 1-year postoperative, 90% of patients worldwide who had undergone pocket implantation of the KAMRA inlay were within ±1.00 D of their intended refractive correction (Figure 2), compared with 71% who had the inlay implanted under a flap. Compared with the previous inlay implantation method that required a thick flap, the pocket reduces the healing response and dry eye, allowing vision to stabilize quickly.

In assessing refractive outcomes with the KAMRA inlay, it is important to pay close attention to the method of refraction. Autorefraction is unreliable in an inlay eye and will bias the measurement hyperopically. A midpoint or red/green refraction is the most accurate given the increased depth of focus. It is helpful to view the subjective refraction in the context of the patient's satisfaction with near and distance acuity. ■

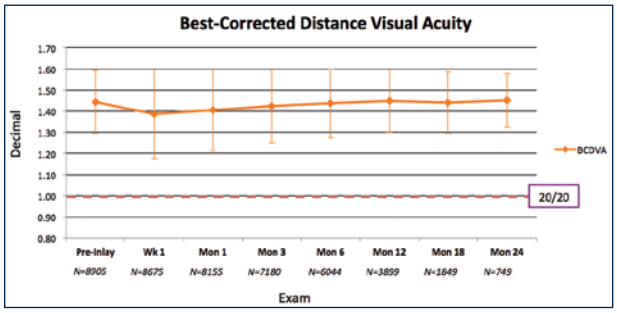

Figure 1. At 12 and 24 months, 99.6% of patients undergoing commercial pocket implantation of the KAMRA inlay had a distance BCVA of 20/25 or better, and only 1.03% lost 2 or more lines of distance BCVA at 24 months.

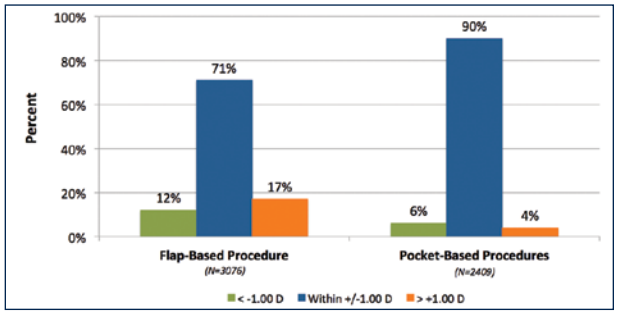

Figure 2. One year after surgery, 90% of patients worldwide who underwent pocket implantation of the KAMRA inlay (vs 71% with an inlay implanted under a flap) were within ±1.00 D of intended refractive correction.

Wolfgang Riha, MD, is in practice at Sehkraft Eye Center in Cologne, Germany. Dr. Riha has been involved in clinical trials of small-aperture inlays since 2007 and has implanted about 250 inlays in his current refractive practice. He also trains new KAMRA surgeons around the world. He is a member of the AcuFocus Medical Advisory Board. Dr. Riha may be reached at e-mail: riha@sehkraft.de.

EXPERT ROUNDTABLE: REFRACTION AND REFRACTIVE STABILITY

Moderator: Wolfgang Riha, MD
Panelists: David Kent, MD; Jong Ho Lee, MD; and Richard von Volkmann, MD

Wolfgang Riha, MD: What refractive targets do you aim for in each eye with the KAMRA inlay?

Jong Ho Lee, MD: Patient satisfaction has greatly improved with a -0.75 D target in the inlay eye. It works well with the principle of small-aperture optics to increase the patient's depth of focus for better near vision.

David Kent, MD: I agree. Since I began aiming for -0.75 D, my patients have achieved at least J2 near vision, and about half are J1. I have not needed to do any enhancements in the past year.

Richard von Volkmann, MD: At first, I did not like the idea of such a large discrepancy between the two eyes, so I aimed for -0.75 D in the inlay eye and -0.25 D in the dominant eye. But I quickly learned that patients did not like this. The noninlay eye must be truly emmetropic.

It is not unusual for patients to come in wearing only reading glasses and claim to not need distance correction. Once you implant the inlay, you realize they are actually latent hyperopes and need an excimer correction in the other eye.

I now make sure to treat even minor amounts of error in order to get both eyes within the ideal target range. With the combination of -0.75 D in the inlay eye and emmetropia in the noninlay eye, my patients typically have distance vision of 0.8 UCVA in the KAMRA eye and 1.0 or 1.2 binocularly.

Riha: How do you obtain reliable, post-inlay refractions in your practice?

von Volkmann: You must do a midpoint refraction. Initially, I was pushing patients too much to the plus side with a standard refraction.

When I compared my results with others, I had the same excellent near UCVA results, but my subjective refractions were closer to +1.00 D, which is impossible if the patient can read 1.0 uncorrected. Once I began doing midpoint refractions, the results make much more sense.

Riha: At what point do patients achieve refractive stability?

von Volkmann: With any presbyopia procedure, neural adaption is required. Some patients adapt quickly and they are happy the day after surgery, but others may take several months. For the latter group, it is not as much a problem of unstable or fluctuating vision but simply a longer process of adapting to their vision after presbyopia correction.

Riha: I agree. After 1 month, it is the brain—not the eye—that is still adjusting. In my experience, patients with strong eye dominance may struggle more to adapt than those with weaker ocular dominance. Patients can help the process by not using glasses and not comparing one eye to the other postoperatively.

Kent: At 1 month, most patients are stable and happy. If there are problems with stability of the refraction, it may be that the patient has dry eye or stopped using the prescribed drops.

PEARLS FOR POSTOPERATIVE OPTIMIZATION

- ✓ Target -0.75 D refraction in the inlay eye and plano in the fellow eye
- ✓ Treat even minor amounts of refractive error
- ✓ To accurately assess refraction after inlay implantation, use either a midpoint or red/green refraction technique
- ✓ If refractive changes are noted, check against acuity results
- ✓ Treat dry eye aggressively
- ✓ Strong ocular dominance can influence neural adaption

> I now make sure to treat even minor amounts of error in order to get both eyes within the ideal target range.
> – Richard von Volkmann, MD

Riha: Is refractive stability better with pocket implantation than with flaps?

Kent: Yes. Most patients in this age group, especially postmenopausal women, have preexisting dry eye. When we created thick flaps, we severed a lot of corneal nerves, made their dry eye worse, and prolonged visual recovery. Additionally, the uncertainties of ablation in the deeper stroma, flap repositioning problems, and the challenges of correctly centering inlays under flaps increased the likelihood of BCVA loss.

Implanting the inlay in a deep corneal pocket and performing LASIK (if needed) under a thin flap is a better strategy.

Postop Findings in Inlay Patients

Pocket implantation has simplified postoperative management.

BY FRANCESCO CARONES, MD

In my experience, presbyopes who are motivated to get rid of their reading glasses are overwhelmingly happy with a KAMRA inlay, and their results justify the time spent on postoperative management.

Mild corneal steepening over the inlay or minor changes in refraction are normal postoperative findings that generally do not require treatment. Healing time is typically 1 month, with patients gaining 3 lines by 1 week and an additional line by 1 month postoperatively. Minimizing surgical time may reduce edema and healing time.

Near and distance vision with the inlay is dependent on refractive error. Patients who do not achieve the target refraction of -0.75 ±0.25 D in the inlay eye and plano in the fellow eye may not have the UCVA they desire. Regression and the method of assessment can affect the postoperative refraction. Autorefraction is unreliable in an inlay eye; a midpoint refraction should be performed. Fluctuations in vision are usually due to dry eye and associated with poor compliance with the postoperative drop regimen.

Pocket implantation, even in patients who also require LASIK, has simplified postoperative management. Global registry data show that the incidence of wound healing response has declined from 17% with the combined LASIK-KAMRA procedure under a thick flap to 4% when the inlay is implanted in a corneal pocket.

LOOK AT THE AXIAL MAP

For the most accurate view of any areas of elevation on topography, surgeons should look at the axial map, rather than the instantaneous or tangential radius of curvature map. It is fairly common to see a red ring of mild, mid-perhipheral steepening over the inlay. This is statistically significantly correlated with inlay depth, time since surgery, and ablation type.[1] The red ring is most obvious in the eye with the shallowest implantation (Figure 1).

By itself, a red ring is of no consequence and does not require therapy. However, when accompanied by central flattening, haze formation, and a hyperopic shift, corticosteroid treatment is needed.

A blue ring or area of flattening over the inlay is also not necessarily cause for concern. In most cases, this is due to tear film irregularity, which can result in a myopic shift and central steepening. Aggressive ocular surface treatment will resolve the problem (Figure 2). When accompanied by corneal haze and stromal thinning noticeable on optical coherence tomography (OCT), one might consider removal, but I have never seen this, nor has this been reported commercially. In fact, I have removed only one inlay out of 200, and that one was due to dissatisfaction rather than complication.

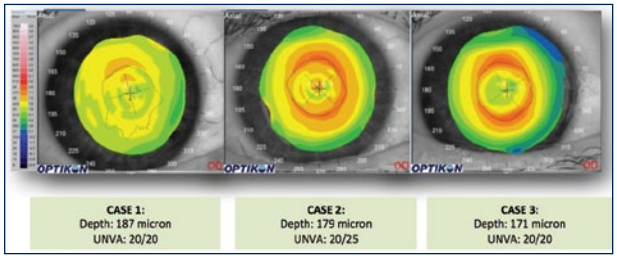

Courtesy of Francesco Carones, MD

Figure 1. Presence of a red ring on topography can be influenced by implant depth. These three patients had their inlay implanted at different depths. The deeper implant had no ring, whereas the shallower implant has an obvious ring.

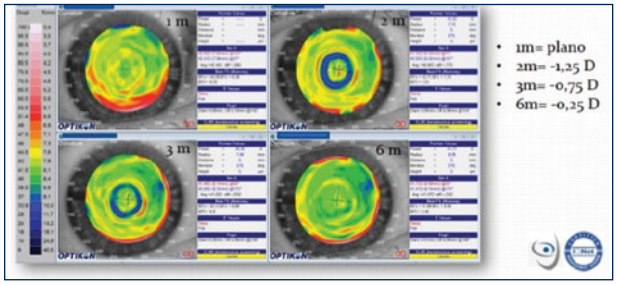

Courtesy of Francesco Carones, MD

Figure 2. This patient had a good result at 1 month, but, at the 2- and 3-month visits, there appeared to be a myopic shift and a blue ring was seen on the topography axial map. Dry eye treatment resolved the problem.

My recent OCT studies suggest that when postoperative refractive shifts occur, they are related to changes in epithelial thickness rather than a stromal response. In the majority of eyes, appropriate management with topical steroids or dry eye therapies will reduce steepening and reverse a refractive shift so that patients achieve the target refractive result. ■

Francesco Carones, MD, is Medical Director of the Centro Oftalmo-Chirurgico Carones in Milan, Italy. Dr. Carones has implanted about 200 KAMRA inlays since 2010 and states that he is an advisor to AcuFocus. He may be reached at e-mail: fcarones@carones.com.

EXPERT ROUNDTABLE: EFFECTIVE POSTOPERATIVE MANAGEMENT

Moderator: Francesco Carones, MD
Panelists: Günther Grabner, MD; Joon Hyun Kim, MD, PhD; Jeffery J. Machat, MD, FRCSC; and Jay S. Pepose, MD, PhD

Francesco Carones, MD: What has been your experience with topographic assessment following KAMRA inlay surgery?

Jay S. Pepose, MD, PhD: As you noted in your article, some patients develop a wound healing response, but they generally respond nicely to a course of topical steroids. In the Investigational Device Exemption (IDE) clinical trial, we rarely saw a wound healing response requiring an additional course of steroids in eyes in which the pocket was created with a femtosecond laser using a spot/line separation of 6 X 6 or less.

Jeffery J. Machat, MD, FRCSC: I have only seen this once, and I do not think a red ring with hyperopic shift is common with the current technique. The most important thing is that we are treating the patient, not the topography, as the imaging only tells part of the story. We must look at topography in the context of visual acuity, ocular surface conditions, and other results.

Carones: What is the typical healing time for your patients?

Machat: About 20% of my patients experience incredibly fast visual recovery and are able to read J1 or J2 the next day. The majority take 3 to 4 weeks to heal and adapt to the inlay, and only about 5% experience a longer recovery of 3 to 4 months. Although it is hard to predict who will fall into this last category, we can improve their chances of faster recovery with a long, slow, steroid taper and aggressive treatment of dry eye.

Kim: I agree. Although many patients are satisfied within the first month or two, I set expectations by telling patients to expect 3 months for complete healing. Once they reach that point, patients continue to enjoy good vision indefinitely, unlike other procedures that become less effective as presbyopia advances.

Carones: If the refraction is off or the patient experiences fluctuations in vision, is that an indication for inlay removal?

Pepose: The biggest source of fluctuations in vision is the tear film. In the clinical trial, we learned that we must be aggressive on the front end in diagnosing and treating ocular surface problems and continue treatment postoperatively.

Grabner: These are not young LASIK patients. The reality is that almost all of them have dry eye, and that has a major impact on quality of vision, especially near vision. I now put punctal plugs in all my inlay patients and recommend the use of artificial tears for 6 to 9 months after surgery.

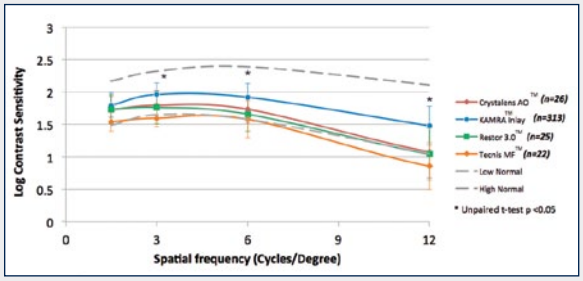

Figure 1. KAMRA inlay patients had statistically significantly better mesopic contrast sensitivity (CS) at 3, 6, and 12 spatial frequencies, without glare, when compared with commercially available accommodating and diffractive multifocal IOLs.

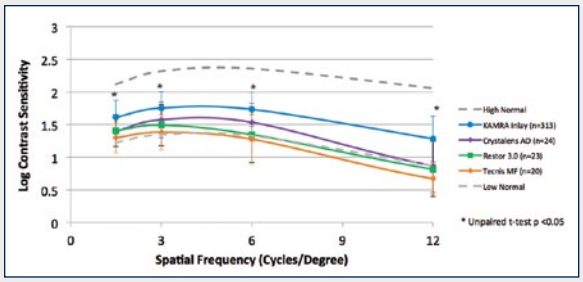

Figure 2. Inlay patients had significantly better binocular mesopic contrast sensitivity at all spatial frequencies, when compared to all three IOLs for the glare condition.

Kim: If the problem is a missed refractive target, we can perform an enhancement.

Carones: Do you see reduction in contrast sensitivity postoperatively?

Grabner: Any perceptible loss occurs only in dark situations, such as driving in a tunnel at night. Our published results demonstrate that binocular mesopic vision continues to be excellent.[2]

Pepose: There is some reduction in monocular mesopic contrast sensitivity in the inlay eye, but it remains within normal limits. To put this in perspective: There is less loss of contrast than with presbyopia-correcting IOLs (Figures 1 and 2).[3] With a small-aperture inlay, we are not inducing aberrations, so the result is high-quality vision.

1. Carones F. Assessment of the KAMRA inlay using videokeratography and corneal OCT: 2-year results. Paper presented at: the ESCRS Annual Meeting; October 5–9, 2013; Amsterdam, Netherlands.
2. Seyeddain O, Bachernegg A, Riha W, et al. Femtosecond laser-assisted small-aperture corneal inlay implantation for corneal compensation of presbyopia: two-year follow-up. *J Cataract Refract Surg.* 2013;39(2):234–241.
3. Pepose J. Comparison of depth of focus and mesopic contrast sensitivity in small-aperture inlay, accommodating IOL, and multifocal IOL patients. Poster presented at: the 2014 Annual Symposium, American Society of Cataract and Refractive Surgery; April 25–29, 2014; Boston.

Addressing and Minimizing Postoperative Complications

Following best practices for inlay implantation can help to maximize success rates.

BY MINORU TOMITA, MD, PHD

Surgical complications with small-aperture corneal inlays are relatively rare and have been decreasing with advances in surgical technique. By following best practices for inlay implantation, surgeons can maximize their chances of success and minimize the chance of a complication or removal.

Best practices include adequate patient selection and counseling. The primary reasons for removal are dissatisfaction with vision and/or failure to adapt to vision with the inlay (Figure 1). Therefore, it is important to hit the desired refractive targets and educate patients about what to expect.

REPORTED COMPLICATIONS AND PATIENT COMPLAINTS

Some reported complications are related to shallow implantation or complications with a thick flap. Pocket implantation at 200 to 250 µm in the stroma is the best way to avoid these problems.

Even with pocket implantation, a small percentage of patients may still develop an aggressive wound healing response characterized by stromal thickening over the inlay, central flattening, haze over the inlay annulus, and hyperopic shift. However, the reaction occurs in only 4% of patients and, in the vast majority, it can be resolved with another round of steroid therapy. In the rare instance when the eye either does not respond or rebounds after steroid therapy, inlay removal should be considered.

> Today, complications with the inlay are exceedingly low and continue to decline as surgeons develop their surgical skill and technology advances.
> – Minoru Tomita, MD, PhD

Dry eye can result in fluctuations in vision. Care should be taken preoperatively to address any preexisting ocular surface problems. Lubrication with artificial tears and/or therapeutic measures can resolve most vision problems related to postoperative dryness. Patients may also report shadows and/or double vision if their inlay is not centered correctly. However, recentration results in almost immediate improvement.[1]

Removal Rate Comparison*

	% Removal after Flap-Based Procedures	% Removal after Pocket-Based Procedures	Removal Rate Improvement
Global	6.07%	1.20%	80% decrease

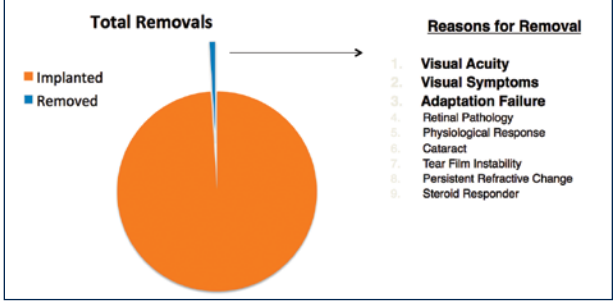

Figure 1. The KAMRA inlay removal rate has declined to 1.2% after surgeons moved from flap-based procedures to pocket implantation. ***Data from Global KAMRA Data Registry.***

Globally, the removal rate has decreased from 6% with flap procedures to 1.2% with pocket-based procedures (Figure 2). This mirrors my own removal rate, which has declined from 5% to 1.5% with pocket procedures. Even at the peak, the removal rate was similar to the rate of surgical monovision reversal[2,3] and it is now approaching the rate of IOL exchange,[4] which carries greater surgical risk.

When removal is indicated, it should be done promptly to ensure faster return and stabilization of vision. Both distance and near UCVA recovered by 1 month and stabilized by 3 months, and 97% recovered their preoperative distance BCVA by 6 months. The remaining 3% only lost 1 line of distance BCVA at 6 months.[5]

Today, complications with the inlay are exceedingly low and continue to decline as surgeons develop their surgical skill and technology advances. ■

Minoru Tomita, MD, PhD, is Medical Director of the Minoru Tomita Eye Clinic Ginza in Tokyo. Dr. Tomita has implanted more than 10,000 KAMRA inlays and has helped to refine both the inlay technology and techniques for implantation. He serves on the AcuFocus Global Medical Advisory Board and may be reached at e-mail: harvardmedical1972@gmail.com.

EXPERT ROUNDTABLE: MANAGING INLAY COMPLICATIONS

Moderator: Minoru Tomita, MD, PhD
Panelists: Wayne Crewe-Brown, MD; Jong Ho Lee, MD; Wolfgang Riha, MD; and Roger Zaldivar, MD

Minoru Tomita, MD, PhD: What is your personal inlay removal rate, and how has it changed over time?

Wayne Crewe-Brown, MD: My overall explant rate is 2%. This includes the early flap procedures, which I moved away from rather quickly. For pocket procedures only, my removal rate is 1.1%.

Wolfgang Riha, MD: During previous work with Günther Grabner, MD, which included some of the earliest patients implanted with the inlay, our removal rate was more like 5%. It has declined significantly with advancements in the past 7 or 8 years. In my refractive practice, our explant rate has dropped from 4% with flaps to 1.3% with pockets.

I had one patient treated with a thick flap procedure in whom the inlay was removed due to a wound healing response. I have not removed any from a pocket to date. We want to get the removal rate as low as possible, but it will never be zero. The relative ease of removal in case of dissatisfaction is one advantage of the KAMRA inlay.

> We want to get the removal rate as low as possible, but it will never be zero. The relative ease of removal in case of dissatisfaction is one advantage of the KAMRA inlay.
> – Wolfgang Riha, MD

Jong Ho Lee, MD: I have performed only pocket procedures. In more than 250 cases, my explant rate is 0.8%.

Roger Zaldivar, MD: With the pocket procedure, I have not removed a single inlay. This is a big improvement over implanting an inlay under a thick flap.

I have done enhancements on some patients and found that PRK works well in inlay-implanted eyes. In post-LASIK patients, I lift the flap to perform an enhancement if needed prior to inlay implantation. As I continue to refine my treatment nomograms, I anticipate that the enhancement rate will decrease.

Tomita: What postoperative complications have you encountered, and how were they managed?

Zaldivar: With the pocket procedure, the only complication I have seen is dry eye, which can be easily managed.

Lee: I agree. I treat dry eye aggressively with punctal plugs, artificial tears, cyclosporine, lid scrubs and compresses, and autologous serum.

	Value	Pre-Op	1M	3M	6M	12M
POCKETS	n/N	5/508	25/505	29/499	13/487	16/479
	%	1%	5%	4.2%	5.8%	3.3%
FLAPS	n/N	4/185	19/184	12/177	9/169	12/160
	%	2.2%	2.8%	10.3%	6.8%	7.5%

Figure 1. Based on clinical trial results, there appears to be a lower incidence of dry eye after a pocket-based procedure than a flap procedure. LASIK was not performed in the flap cases presented here. *Data on file, AcuFocus.*

Crewe-Brown: I have seen fewer problems with dry eye (Figure 1) and wound healing response than we had with the flap procedures. Epithelial ingrowth occurred occasionally with flap procedures, particularly if one needed to relift the flap. Although epithelial ingrowth into a pocket is possible, it is highly unlikely, especially if you use a secondary instrument to open the pocket for inlay insertion. The rate of early complications with the inlay is lower than with many other well-accepted technologies. We have learned from the complications and improved the procedure to minimize them.

Tomita: What do you consider a sign that the inlay should be removed rather than continuing to treat the complication?

Lee: It is important to follow the patients carefully and move quickly to treat with corticosteroids if indicated. Proper steroid treatment at an early stage will substantially decrease the need for removal. I would consider removing the inlay if there is an aggressive wound healing reaction that is uncontrolled or recurs as soon as steroids are stopped.

Crewe-Brown: I agree. If steroids do not resolve the situation, I would remove the inlay. It is also important to ensure that what one believes to be a refractive shift is not simply regression of the excimer laser treatment.

Tomita: When you have removed an inlay, has the end result been satisfactory?

Riha: Yes. In my experience, the earlier you remove it, the faster the patient can return to his or her preoperative state. When you remove the inlay within the first year, recovery takes just a few days.

1. Gatinel D, El Danasoury A, Rajchles S, Saad A. Recentration of a small-aperture corneal inlay. *J Cataract Refract Surg.* 2012;38:2186-891.
2. Reilly CD, Lee WB, Alvarenga L, et al. Surgical monovision and monovision reversal in LASIK. *Cornea.* 2006;25(2):136-138.
3. Braun EH, Lee J, Steinert RF. Monovision in LASIK. *Ophthalmology.* 2008;115(7):1196-1202.
4. Marketscope 2012 IOL Report.
5. Vilupuru S, Tomita M. Visual recovery following removal of small aperture intra-corneal inlay. Poster presented at: the 2014 Association for Research and Vision in Ophthalmology; May 4-8, 2014; Orlando, Florida.

Set Patients Up to Succeed

The pocket procedure has been a game-changer for the patient experience.

BY ROGER ZALDIVAR, MD

The ideal KAMRA patient is a presbyope between 45 and 65 years of age with preoperative manifest refractive spherical equivalent between -5.00 and +3.00 D with less than 3.00 D of cylinder. The eye should have sufficient central corneal thickness to accommodate the inlay at a depth of 200 to 250 µm and leave at least 250 µm between the inlay pocket and the endothelium. Post-LASIK patients and pseudophakes with monofocal IOLs are also great candidates.

CLEAR OPTICAL PATH

Patients must also have generally good ocular health, good binocularity, a healthy and stable tear film, and a low degree of optical scatter. For small-aperture optics to function as intended, a clear optical path through the center of the inlay is required.

The AcuTarget HD instrument is an excellent tool for evaluating the patient's quality of vision pre- and postoperatively. It uses double-pass retinal imaging technology to assess the amount of forward light scatter and assigns an objective scatter index (OSI) score in order to quantify visual quality. For example, patients with an OSI score below 1.0 have good quality of vision and may be a good candidate for the KAMRA inlay. For patients with an OSI score above 1.0, they may be developing a cataract or have dry eye and may require another therapy, such as cataract surgery (Figure 1).

I also look for candidates with a positive outlook and realistic expectations. There is no fountain of youth, but I know through experience that KAMRA patients achieve great optical quality with minimal compromise in their range of vision. Furthermore, data indicate that, at 1 year, 95% of patients are satisfied and only 8% occasionally or sometimes use reading glasses.

The pocket procedure has been a game-changer for the patient experience. We see less dry eye postoperatively, and visual recovery is much faster—often, patients do not even feel like they had an operation the day before.

IMMEDIATE IMPROVEMENTS, FOLLOWED BY FURTHER IMPROVEMENTS

It is important to talk to patients about their visual recovery in order to ensure they understand they will see immediate improvement on day 1 and further improvement over the first month. Those with strong eye dominance should also understand that they may take a little longer to adapt.

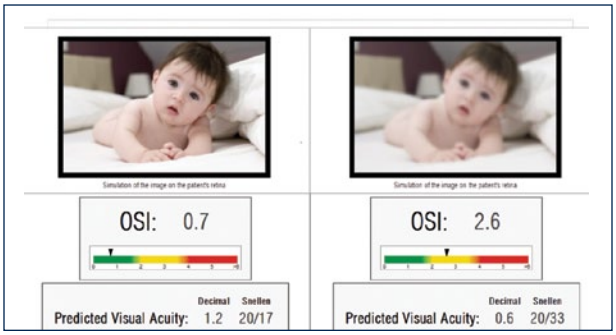

Figure 1. Using the objective scatter index (OSI) and double-pass technology, the AcuTarget HD instrument quantifies quality of vision. A presbyopic patient presenting with an OSI score below 1.0 preoperatively indicates a clear optical system and that patient may be a good candidate for a KAMRA inlay.

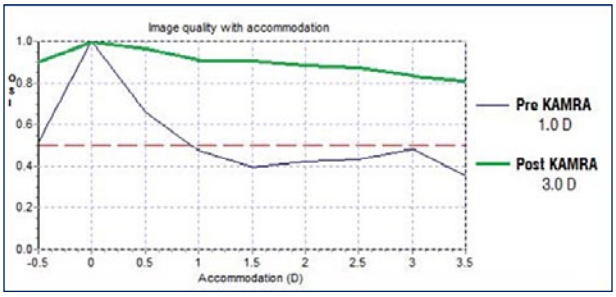

Figure 2. The AcuTarget HD instrument shows the change in depth of focus with and without the inlay. In this example, the patient's depth of focus improved from 1.00 D preoperatively to 3.00 D postoperatively with implantation of a KAMRA inlay.

I find this helps to set an appropriate expectation that it will take time to achieve their optimal functional near vision. Distance vision is well maintained during this time (Figure 2).

CONCLUSION

With the selection criteria outlined here combined with pocket implantation, appropriate refractive targeting, and postoperative management, surgeons can expect a high rate of success with the KAMRA inlay. ■

Roger Zaldivar, MD, is President and Scientific Director of Instituto Zaldivar in Mendoza, Argentina. Dr. Zaldivar has implanted about 50 KAMRA inlays and states that he serves as a member of the AcuFocus Global Medical Advisory Board. He may be reached at e-mail: zaldivar@zaldivar.com.

EXPERT ROUNDTABLE: PATIENT SATISFACTION WITH CORNEAL INLAYS

Moderator: Roger Zaldivar, MD
Panelists: John Blaylock, MD, FRCSC; Jeffery J. Machat, MD, FRCSC; and Marco Rossi, MD

Roger Zaldivar, MD: What patient selection pearls have helped your success with the KAMRA inlay?

John Blaylock, MD, FRCSC: We have gotten excellent results by adhering closely to the company's recommended selection criteria and not pushing the technology on patients who are not good candidates. I think it is also important to ensure that you get patients to an optimum refraction (-0.50 to -1.00 D in the non-dominant eye and plano in the dominant eye) before implanting the inlay.

Jeffery J. Machat, MD, FRCSC: I am quite picky about the tear film. I also try to rule out patients who are extremely intolerant of differences between their two eyes and those who would be better served by binocular vision for extensive near work, such as a graphic artist or a dentist who uses a loupe.

Zaldivar: How do you set expectations for the presbyopic patient?

Marco Rossi, MD: A successful patient experience is directly related to how effective initial counseling is. Beware of the patient with completely unreasonable expectations: People who expect to be able to read newspapers in the dark are not going to be happy with any presbyopic correction.

Blaylock: People who seek refractive surgery tend to be demanding and compulsive or a perfectionist—exactly who many experts say we should stay away from. I am like that myself, so I do not shy away from these patients. I have an honest conversation with patients about what to expect from the technology. I tell them they may still need reading glasses or better light at certain times or for some activities. If you are upfront about those aspects, patients will self-select.

Machat: It is really important to emphasize to patients not to use readers or compare their two eyes during the initial postoperative period. That inhibits the neural adaption that needs to happen and will slow down visual recovery.

Zaldivar: What is your experience with the AcuTarget HD?

Rossi: The device helps me to see how the patient sees and gives me important visual quality data that we can use clinically. The data help to overcome the difficulty some patients have in articulating their visual problems or symptoms, both pre- and postoperatively.

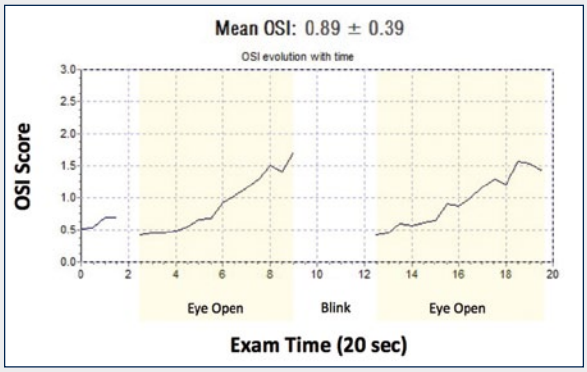

Figure 1. The AcuTarget HD instrument provides an objective measure of the impact of tear film instability on quality of vision. The chart reports objective scatter index (OSI) score over time. This result indicates that when the patient has their eye open that their OSI score increases from 0.5 to more than 1.5 over 6 seconds. This is an example of a patient who could benefit from dry eye therapy.

Machat: It has helped us achieve more precise centration, which I have increasingly focused on in performing this surgery. In addition to centration, the AcuTarget HD instrument (AcuFocus) helps identify barriers to success preoperatively such as visual quality degradation from dry eye or early cataract formation (Figure 1). We now use it routinely on all our cataract patients, too.

Zaldivar: How has adding the inlay impacted your practice?

Blaylock: The visual outcomes for the two-step LASIK and KAMRA procedure have been stellar. I offer a range of procedures, from LASIK to refractive lensectomy, and the small-aperture inlay fits nicely into the mix.

Offering the KAMRA inlay has strengthened our presbyopia practice overall, because it brings in people who want to get rid of their reading glasses. Some are good candidates for the inlay; others have lenticular changes or significant dry eye, and I recommend lens exchange instead.

Machat: I explored every solution to presbyopia that has been suggested in the past decade or more, from scleral implants to thermal keratoplasty to multifocal or intrastromal ablations. Nothing grabbed my attention until the small-aperture inlay came along.

With the KAMRA inlay, we can reliably get patients to 20/25 or 20/20 distance and J1 or J2 near—and that is what it takes to satisfy today's presbyopes.

The KAMRA inlay is an investigational device, limited by federal (US) law to investigational use and not available for sale in the United States.

The KAMRA inlay and AcuTarget HD instrument are trademarks of AcuFocus, Inc.
The AcuTarget HD was developed by Visiometrics in collaboration with AcuFocus. Visometrics is an optical science company, based outside of Barcelona, Spain, and developers of the OQAS technology and HD Analyzer.
The AcuTarget HD is distributed by AcuFocus, Inc.

Distributor Contact Information:
AcuFocus, Inc. • 32 Discovery #200 • Irvine, CA 92618 • Tel: +1 949 585 9511 • www.AcuFocus.com

Manufacturer Contact Information:
Visiometrics, S.L. • Ctra. N-150, Km 15 • Módul TR20, IPCT • E-08227 Terrassa (Spain) • Tel: +34 93 736 3210 • www.visiometrics.com

SC-080 Rev A