Refloating Luxated IOLs Using the Vitreotome

This technique minimizes the risk of causing damage to the retina.

BY PEDRO VÍCTOR DE MIGUEL SIMÓ, MD; ROSANNE GOSALBEZ RAFEL, MD; MIRIAM FERRÁN FUERTES, MD; ENRIQUETA CANTAL PORTABELLA, MD; CARLES BARNÉS RUZ, MD; AND CARLOS LUIS MOSER WÜRTH, MD

The use of IOLs for visual rehabilitation after cataract surgery has led to major improvement in patients' quality of life. However, the few cases in which the IOL luxates into the vitreous cavity require complex surgeries that are fraught with potential complications.[1-5]

The first case of removal of a posteriorly dislocated lens was published in 1977, before the advent of vitrectomy,[6] and it seems to be an approach based on the Barraquer method for the removal of lenses luxated into the vitreous cavity.[7] Surgeons later began using forceps to rescue luxated IOLs after vitrectomy;[8] however, this technique was problematic in that the retina could be injured either directly with the forceps (Figure 1A) or indirectly by twisting the IOL when trying to seize it (Figure 1B). This complication led to the use of ophthalmic viscosurgical devices (OVDs) and perfluorocarbon liquid (PFCL) to protect the adjacent retina during surgery.[9]

Subsequently, new types of lenses were introduced, including silicone one-piece IOLs. These IOLs were difficult to grasp vertically, as they lacked haptics. When they luxated into the vitreous, their removal required the use of PFCL to facilitate presenting the IOL to the forceps. First, the edge of the IOL had to be lifted with the light pipe in one hand while the other hand held the cannula, through which PFCL was being injected.[10] This was a dangerous maneuver, and the retina could be injured in several ways—either with the light pipe, with the edge of the IOL or the haptic when tilted or grasped with the forceps, or by macular phototoxicity while working near the retina with lighted sources (Figure 2).

Several other techniques have been described for repositioning luxated IOLs, including intraocular suturing of the haptics and lifting the IOL by pulling these sutures.[11,12] These approaches were difficult and were associated with major iatrogenic complications, such as frequent macular phototoxicity. Therefore, Santos et al[13] developed a technique that was easy, fast, and cost-efficient: They proposed lifting the IOL by the optic with a silicone-tip aspiration

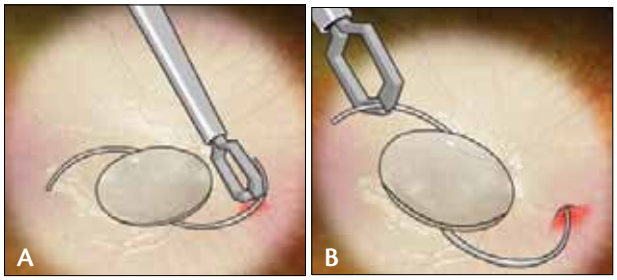

Figure 1. With earlier techniques, the retina could be injured either (A) directly with the forceps or (B) indirectly by twisting the IOL when trying to seize it.

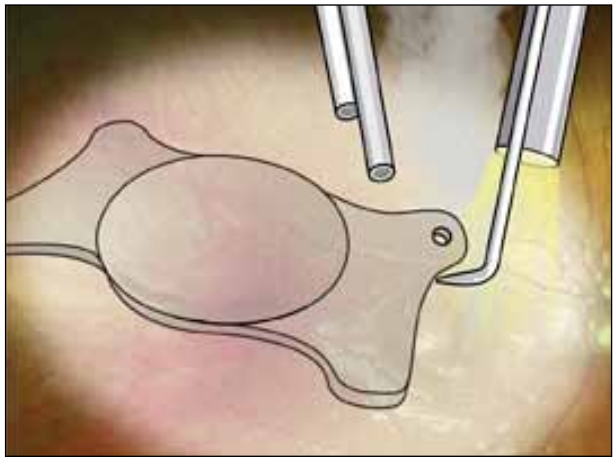

Figure 2. With another technique, the retina could be injured with the light pipe, with the edge of the IOL or the haptic when tilted or grasped with the forceps, or by macular phototoxicity while working near the retina with lighted sources.

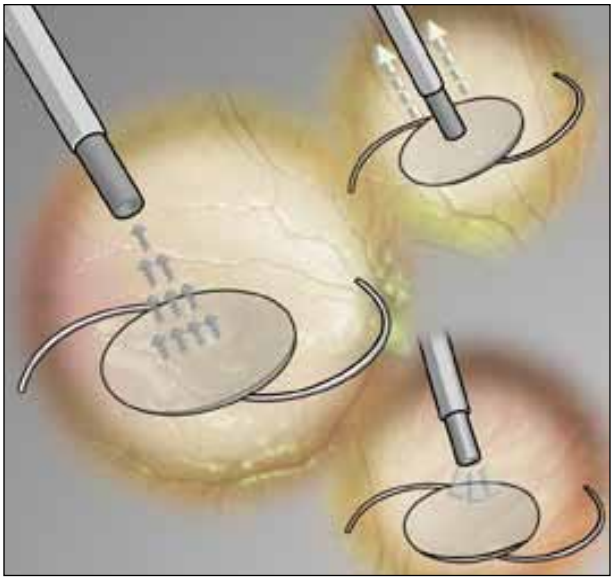

Figure 3. One method proposed lifting the IOL by the optic with a silicone-tip aspiration cannula connected to the vacuum of the vitreotome.

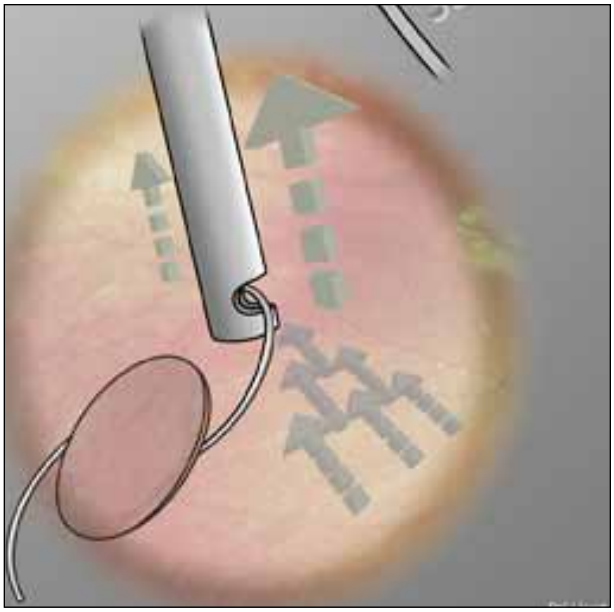

Figure 4. A 23-gauge vitreotome may be used for grasping a three-piece IOL by the haptic.

cannula connected to the vacuum of the vitreotome (Figure 3). Although this technique made it possible to refloat any type of IOL, it could not be used with capsular tension rings (CTRs), and, if vacuum were lost, the IOL would drop to the posterior pole.

TECHNIQUE

Given the results with previous efforts, we proposed using an instrument that had both aspiration properties and a hook-like effect. After several in vitro trials, we confirmed that a 23-gauge vitreotome (Alcon Laboratories, Inc.) was ideal for grasping a three-piece IOL by the haptic (Figure 4) and a 20-gauge vitreotome (Alcon Laboratories, Inc.) was suitable for holding any type of IOL by the optic (Figure 5). Both devices were equally useful for holding CTRs. To optimize suction and decrease flow, we placed some OVD on the tip of the vitreotome. We found that the optimal aspiration rate was 330 mm Hg. With this level of aspiration plus OVD, the IOL would not drop, even without saline infusion.

TAKE-HOME MESSAGE

- The vitreotome has aspiration properties as well as a hook-like effect.
- A 20-gauge vitreotome is suitable for luxated one-piece IOLs, and a 23-gauge vitreotome may be used for luxated three-piece IOLs and CTRs.
- This technique minimizes the risk of causing damage to the retina.

For this technique, a three-port vitrectomy is created to allow instrument access and accessory lighting. We suggest using a 20-gauge vitreotome for luxated one-piece IOLs and a 23-gauge vitreotome for three-piece IOLs and CTRs. Central vitrectomy is performed first. We then administer an injection of diluted triamcinolone in 3 mL of balanced saline solution in front of and behind the luxated IOL. Triamcinolone-assisted vitrectomy is then completed, allowing the IOL to drop to the posterior pole. We avoid grasping the IOL with forceps before completing the vitrectomy to minimize the risk of peripheral retinal breaks due to trapping vitreous in the lumen of the forceps, especially when using 20-gauge instruments.

At this point, we perform partial interchange with air until the anterior chamber is full, then substitute air for sodium hyaluronate. A paracentesis is created at the 8-o'clock meridian. A droplet of OVD is placed on the tip of the vitreotome; membrane forceps are introduced through the left-hand sclerotomy and the vitreotome through the right-hand sclerotomy. The vitreotome aspiration is increased to 330 mm Hg, with the cutting function turned off. Then intraocular pressure (IOP) is raised to 45 mm Hg.

Now we are ready to address the IOL. The vitreotome is placed perpendicular to the retina, with its tip close to the IOL to be grasped, and aspiration is initiated. If the IOL has a three-piece design, it will gently rotate on its haptic, and we can present it vertically to grasp it firmly with the forceps. If it is a one-piece IOL, it will rest flat, so we must rotate the vitreotome to face the

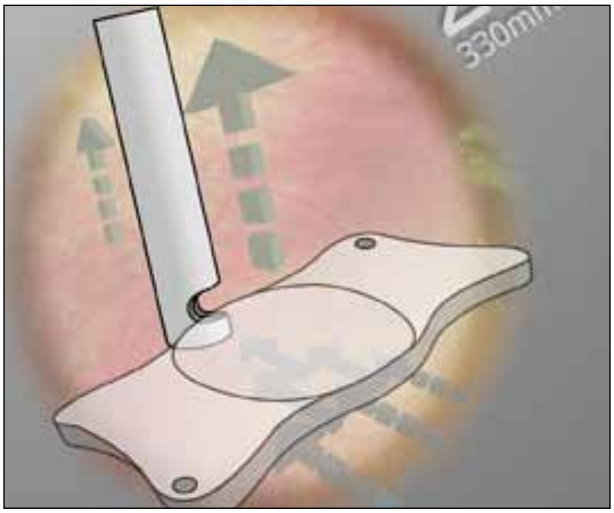

Figure 5. A 20-gauge vitreotome is suitable for holding any type of IOL by the optic.

forceps vertically and allow a firm grasp. We then stop the aspiration and decrease the IOP to 30 mm Hg.

Once the IOL is grasped by the forceps in the center of the eye and under direct visualization through the microscope, we remove the vitreotome and introduce a second forceps through the paracentesis, with which we bring the IOL to the iris plane. OVD is placed over the IOL, deepening the anterior chamber. We check the retinal periphery 360° with scleral indentation to rule out any retinal breaks.

We then proceed to remove, reposition, or exchange the IOL, depending on the status of the eye and the type of IOL in each individual case. For a video demonstration, visit eyetube.net/?v=hisad.

eyetube.net

eyetube.net/?v=hisad

If there is inadequate capsular support, we perform the vitrectomy through two 20-gauge sclerotomies, each under a scleral flap, 180° apart from each other and at 1 mm posterior to the limbus. With our current technique, we then use these same sclerotomies to fixate a three-piece Tecnis ZA9003 IOL (Abbott Medical Optics Inc.; A-constant corrected to 120.1) with fibrin glue. No sutures are needed.

RESULTS

We began using this technique in 2008 and, as of January 2012, we had refloated 12 consecutive cases of IOLs luxated into the vitreous cavity. In this series, UCVA ranged from counting fingers at 1 m to 0.2 (Snellen decimal) preoperatively, and from counting fingers at 1 m to 0.9 postoperatively. No complications due to IOL refloating maneuvers occurred, as there were no cases of posterior retinal breaks, macular phototoxicity, or retained PFCL (which was not used in these cases). One patient had an iatrogenic sector iridectomy during IOL removal.

In three of the 12 cases, an iris-fixated IOL was placed behind the iris. We find this maneuver to be easier than fixating the IOL to the anterior iris surface, and it allows better visualization of the posterior pole during vitrectomy. There was one case of IOL decentration, as one of the iris-claw haptics broke loose. Two cases of cystoid macular edema occurred, one of which resolved after transscleral injection of triamcinolone (visual acuity, 0.7); the second case was associated with a subretinal neovascular membrane 1 year after surgery, and the patient is now receiving antivascular endothelial growth factor therapy (visual acuity, 0.25). In another group's series of 15 surgeries with secondary implantation of a retroiridial iris-fixated IOL,[14] two cases of cystoid macular edema (13%) were reported with visual acuity outcomes of 20/80.

Additionally, one retinal detachment occurred due to a break in the peripheral retina caused by the dominant hand, which was successfully treated with gas. There was one partial detachment of a Descemet-stripping automated endothelial keratoplasty button, which was replaced under air during the same surgery. Corneal decompensation occurred in two patients who had presented with corneal edema prior to vitreous surgery.

We no longer use iris-fixated IOLs in cases in which there is inadequate capsular support. Rather, in the most recent two cases, we performed sutureless sulcus fixation of IOLs using fibrin glue, following the technique described by Amar Agarwal's group,[15] which offers excellent stability and requires no corneal sutures. So far, no other cases of cystoid macular edema have occurred. ■

Miriam Ferrán Fuertes, MD, is a Senior Doctor in the Cornea Section of the Ophthalmology Service at Consorci Sanitari Integral. Dr. Fuertes may be reached at e-mail: miriamferran@hotmail.com.

Carlos Luis Moser Würth, MD, is Head of the Ophthalmology Service at Consorci Sanitari Integral. Dr. Moser Würth may be reached at tel: +34 650431476; e-mail: 20851cmw@comb.cat.

Enriqueta Cantal Portabella, MD, is Chief of the Retina Section in the Ophthalmology Service at Consorci Sanitari Integral. Dr. Portabella may be reached at tel: +34 609962630; e-mail: 20293ecp@comb.cat.

Rosanne Gosalbez Rafel, MD, is a Senior Doctor in the Neuro-Ophthalmology Section of the Ophthalmology Service at Consorci Sanitari Integral. Dr. Gosalbez Rafel may be reached at tel: +34 678589341; e-mail: rosannegosalbez@gmail.com.

Carles Barnés Ruz, MD, is a Senior Doctor in the Retina Section of the Ophthalmology Service at Consorci Sanitari Integral. Dr. Ruz may be reached at tel: +34 646562913; e-mail: carlesbarnes@hotmail.com.

Pedro Víctor de Miguel Simó, MD, is a Senior Doctor in the Retina Section of the Ophthalmology Service at Consorci Sanitari Integral in Barcelona, Spain. Dr. de Miguel Simó may be reached at tel: +34 627192607; e-mail: pvdmiguel@gmail.com.

The authors state that they have no financial interest in the material presented in this article.

1. Steinmetz RL, Brooks HL Jr, Newell CK. Management of posteriorly dislocated posterior chamber intraocular lenses by vitrectomy and pars plana removal. *Retina.* 2004;24(4):556-559.
2. Levy J, Klemperer I, Lifshitz T. Posteriorly dislocated capsular tension ring. *Ophthalmic Surg Lasers Imaging*. 2005;36(5):416-418.
3. Mensiz E, Aytuluner E, Ozerturk Y. Scleral fixation suture technique without lens removal for posteriorly dislocated intraocular lenses. *Can J Ophthalmol*. 2002;37(5):290-294.
4. Flynn HW Jr, Buus D, Culbertson WW. Management of subluxated and posteriorly dislocated intraocular lenses using pars plana vitrectomy instrumentation. *J Cataract Refract Surg*. 1990;16(1):51-56.
5. Smiddy WE, Flynn HW Jr. Management of dislocated posterior chamber intraocular lenses. *Ophthalmology*. 1991;98(6):889-894.
6. Chowdhury AM, Bras JF. Posterior dislocation of an intraocular lens implant and its removal. *Br J Ophthalmol*.1977;61(5):327-328.
7. Adler S. Surgical treatment of dislocated lenses. Report of ten cases using the Barraquer method. *Br J Ophthalmol.* 1967;51(2):73-85.
8. Stark WJ, Michels RG, Bruner WE. Management of posteriorly dislocated intraocular lenses. Ophthalmic Surg. 1980;11(8):495-497.
9. Lewis H, Sanchez G. The use of perfluorocarbon liquids in the repositioning of posteriorly dislocated intraocular lenses. *Ophthalmology*. 1993;100(7):1055-1059.
10. Greve MD, Peyman GA, Mehta NJ, Millsap CM. Use of perfluoroperhydrophenanthrene in the management of posteriorly dislocated crystalline and intraocular lenses. *Ophthalmic Surg*. 1993;24(9):593-597.
11. Maguire AM, Blumenkranz MS, Ward TG, Winkelman JZ. Scleral loop fixation for posteriorly dislocated intraocular lenses. Operative technique and long-term results. *Arch Ophthalmol*. 1991;109(12):1754-1758.
12. Lawrence FC 2nd, Hubbard WA. "Lens lasso" repositioning of dislocated posterior chamber intraocular lenses. *Retina*. 1994;14(1):47-50.
13. Santos A, Roig-Melo EA. Management of posteriorly dislocated introcular lens: a new technique. *Ophthalmic Surg Lasers*. 2001;32(3):260-262.
14. Patil KB, Meleth P, Shanker MP. Pars plana vitrectomy with posterior iris claw implantation for posteriorly dislocated nucleus and intraocular lens. *Indian J Ophthalmol.* 2011;59(6):497-500.
15. Kumar DA, Agarwal A, Prakash G, Jacob S, Saravanan Y, Agarwal A. Glued posterior chamber IOL in eyes with deficient capsular support: a retrospective analysis of 1-year post-operative outcomes. *Eye (Lond)*. 2010;24(7):1143-1148.