Benefits of Toric IOLs in Premium Cataract Surgery

Astigmatism correction at the time of surgery enhances distance UCVA.

BY NIENKE VISSER, MD; NOËL J.C. BAUER, MD, PHD; AND RUDY M.M.A. NUIJTS, MD, PHD

The goal in modern cataract surgery is emmetropia. With today's technology, emmetropia is easily achievable for patients with myopic or hyperopic refractive errors when the appropriate spherical lens power is chosen. In addition to spherical refractive errors, astigmatism should be addressed at the time of cataract surgery so that the patient can achieve the best postoperative visual outcomes.

The reduction or elimination of preexisting corneal astigmatism during or after cataract surgery can be achieved with several surgical strategies, including excimer laser refractive procedures such as PRK and LASIK; limbal relaxing incisions; and opposite clear corneal incisions. However, the refractive changes induced by these procedures are relatively unpredictable, and complications may occur.

Toric IOLs now provide a safe and predictable alternative to reduce or eliminate refractive astigmatism with a cylindrical correction, offering patients with preexisting corneal astigmatism optimal distance visual acuity without the use of spectacles or contact lenses. Approximately 22% of patients undergoing cataract surgery have substantial corneal astigmatism (ie, more than 1.25 D) and would benefit from toric IOL implantation.[1]

ROTATIONAL STABILITY

Two components of toric IOL implantation crucial to the safety and efficacy of the procedure are accurate surgical placement and subsequent rotational stability. As little as 10º of axis misalignment reduces the efficacy of astigmatic correction by 33%; when the misalignment increases to more than 30º, it actually induces astigmatism.[2]

Older toric IOL models were made of silicone, such as the STAAR Toric IOL (STAAR Surgical Company, Monrovia, California) and the MicroSil Toric IOL (HumanOptics AG, Erlangen, Germany).[2,3] Newer toric IOLs are usually made with acrylic materials, which form adhesions with the capsule, leading to rotational stability in the capsular bag within approximately 2 weeks.[4]

TORIC IOL TYPES

AcrySof. The AcrySof IQ Toric (Alcon Laboratories, Inc. Fort Worth, Texas; Figure 1) is currently the most commonly used toric IOL. This one-piece foldable lens is available in spherical powers ranging from 6.00 D to 30.00 D and cylinder powers up to 6.00 D. We performed a pilot study in 53 eyes of 43 patients who underwent cataract extraction and AcrySof Toric IOL implantation. Four months postoperatively, refractive astigmatism was less than 0.75 D in 74% of eyes and less than 1.00 D in 91%.[5] Almost 80% of eyes achieved a distance UCVA of 20/25 or better. No complications occurred, and the mean absolute lens misalignment was 3.5 ±1.9°.

A large randomized, controlled trial[6] showed similar mean misalignment at 6 months (3.4° ±3.0°), with a maximum misalignment of 14° in 250 patients who received the AcrySof IQ Toric. In the control group, 250 patients were implanted with a nontoric lens (model SA60AT). Two eyes (0.8%) in the toric group required surgical intervention to realign the IOL.

Several other noncomparative studies have examined outcomes following AcrySof IQ Toric IOL implantation. Results show UCVA of 20/25 in approximately 70% of eyes and refractive astigmatism of 1.00 D or less in more than 90%. The mean postoperative IOL misalignment in these studies was less than 4°, and surgical repositioning due to

TAKE-HOME MESSAGE

- Toric IOLs provide a cylindrical correction for preexisting corneal astigmatism.
- Approximately 22% of cataract patients have substantial corneal astigmatism and would benefit from a toric IOL.

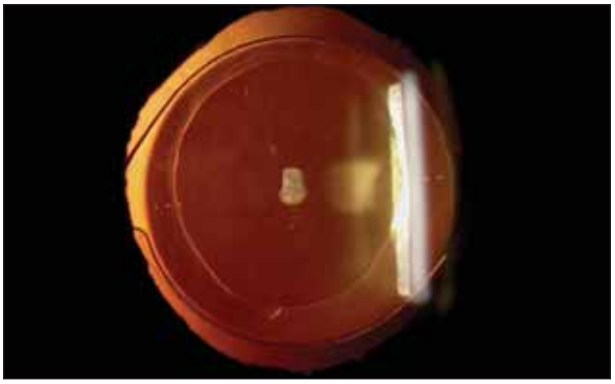

(Image courtesy of Rudy M.M.A. Nuijts, MD, PhD)

Figure 1. Slit-lamp image of the AcrySof IQ Toric in situ.

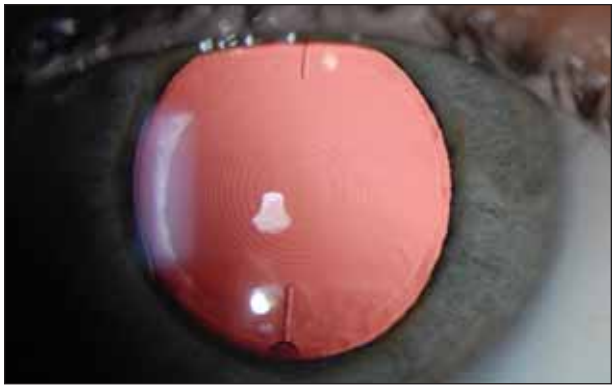

(Image courtesy of Noël J.C. Bauer, MD, PhD)

Figure 2. Slit-lamp image of the multifocal toric AT.LISA in situ.



(Image courtesy of Gerd U. Auffarth, MD)

Figure 3. Slit-lamp image of the Rayner T-flex in situ.

IOL rotation was required in 0% to 1.8% of implanted eyes.[7-10] Overall, these results indicate that AcrySof IQ Toric IOL implantation is a safe, efficient, and predictable method of managing corneal astigmatism in cataract patients.

Weinand et al[11] studied the rotational stability of AcrySof IOLs using digital photographs obtained immediately postoperatively and 6 months after surgery. The mean IOL rotation was 0.9° (range, 0.1°–1.8°). These results indicate that IOL misalignment is largely due to causes other than rotation, including errors during pre- and intraoperative reference markings, errors related to IOL positioning during surgery, and postoperative axis readings. Based on current marking techniques, we believe a mean misalignment of less than 4° is close to optimal.

AT.Comfort/AT.LISA. Previously known as the Acri.Comfort and the multifocal Acri.LISA Toric (Carl Zeiss Meditec, Jena, Germany), these lenses are both one-piece foldable IOLs with optic diameters of 6 mm. The custom-made AT.Comfort and AT.LISA are available in sphere powers ranging from 0.00 to 32.00 D and cylinder powers up to 12.00 D. We began using the multifocal toric AT.LISA in 2008 (Figure 2) and have implanted it in 22 eyes of 12 patients (mean age, 57.2 ±12.3 years). Mean preoperative keratometry value as measured with the IOLMaster (Carl Zeiss Meditec) was 3.10 ±1.20 D. After mean follow-up of 1.5 ±0.7 months, the postoperative Snellen UCVA and BCVA were 0.9 ±0.2 and 1.0 ±0.2, respectively. Binocular near UCVA at 40 cm, measured with the Early Treatment Diabetic Retinopathy Study (ETDRS) chart, was 0.1 ±0.1 logMAR. Mean absolute misalignment was 2.5 ±2.4°, and surgical realignment was required in one eye. Initial experience indicates excellent visual outcomes and good stability of the AT.LISA Toric IOL (personal communication, N. Bauer).

In a recent study, 10 eyes of six patients with ametropia and high corneal astigmatism were implanted with the AT.LISA Toric during refractive lens exchange.[12] Preoperative refractive astigmatism ranged from -1.75 to -5.75 D. After 1 year, the Snellen distance UCVA was 0.8 or better in six eyes and 1.0 or better in five. Mean reduction in refractive astigmatism was more than 90%. The mean IOL misalignment was 1° to 2°.

Rayner Toric. Other toric IOLs currently available in Europe include the T-flex (Figure 3) and the multifocal M-flexT (Rayner Intraocular Lenses Ltd., East Sussex, United Kingdom). Rayner toric IOLs are custom-made and available in cylinder powers ranging from 1.00 to 11.00 D for the T-flex and up to 6.00 D for the M-flexT. Spherical powers are available up to 34.50 D. Initial clinical experiences with the Rayner toric IOL, were promising.[13-15] No study results with this toric IOL have been published so far, and the current authors have no personal experience with these lenses.

(Continued on page 50)

TAKE-HOME MESSAGE

- Limbal relaxing incisions result in less corneal irregularity and more comfort for the patient than corneal incisions, but they induce less astigmatism correction.
- LRIs predictably and effectively correct up to 2.00 D of preexisting corneal astigmatism, but toric IOLs perform even better.

eyes with higher corneal astigmatism (28.7%) required subsequent LASIK for residual refractive error correction.

Postoperative laser vision correction after implantation of presbyopia-correcting IOLs is a viable strategy for patients with significant preoperative corneal astigmatism. However, the main disadvantage is the need for and cost of an additional surgical procedure. It is essential to inform the patient of the possibility of the need for further intervention before cataract surgery. Muftuoglu[5] shows that laser enhancement can successfully be done after previously performed LRIs.

CONCLUSION

LRIs are a predictable and effective means of correcting preexisting corneal astigmatism up to 2.00 D at the time of presbyopia-correcting IOL implantation. However, some eyes may require further laser enhancement. LRIs may increase the percentage of patients who fulfill inclusion criteria for premium IOLs and improve clinical outcomes in these patients. Another option that is worth recommending is postoperative laser enhancement, which can also be done after LRIs. Further development of premium IOLs, such as the recent introduction of toric multifocal lenses, will diminish the need for both LRIs and laser enhancements in the future. ■

Bartlomiej J. Kaluzny, MD, is an Assistant Professor, Department of Ophthalmology, Collegium Medicum, Nicolas Copernicus University, Poland, and Consultant Ophthalmic Surgeon, Oftalmika Eye Hospital, Poland. Dr. Kaluzny states that he has no financial interest in the products or companies mentioned. He may be reached at e-mail: bartka@by.onet.pl.

1. Gills GP. Treating astigmatism at the time of cataract surgery. *Curr Opin Ophthalmol.* 2002;13:2-6.
2. Carvalho MJ, Suzuki SH, Freitas LL, Branco BC, Schor P, Lima AL. Limbal relaxing incisions to correct corneal astigmatism during phacoemulsification. *J Refract Surg.* 2007;23:499-504.
3. Kaluzny BJ. Management of astigmatism at the time of cataract phacoemulsification: limbal relaxing incisions versus Acrysof Toric implantation. Presented at: XXVII Congress of the ESCRS; September 12-16, 2009; Barcelona, Spain.
4. Ferrer-Blasco T, Montés-Micó R, Peixoto-de-Matos SC, González-Méijome JM, Cervino A. Prevalence of corneal astigmatism before cataract surgery. *J Cataract Refract Surg.* 2009;35:70-75.
5. Muftuoglu O, Dao L, Cavanagh HD, McCulley JP, Bowman RW. Limbal relaxing incisions at the time of apodized diffractive multifocal intraocular lens implantation to reduce astigmatism with or without subsequent laser in situ keratomileusis. *J Cataract Refract Surg.* 2010;36:456-464.

(Continued from page 47)

CONCLUSION

Implanting toric IOLs appears to be an efficient, safe, and predictable method for managing corneal astigmatism in cataract patients and a viable product offering for the premium IOL surgeon. Those considering introducing toric IOLs to their practice are encouraged to do so, as these lenses provide the opportunity for patients with astigmatism to achieve excellent distance UCVA and resulting spectacle independence. ■

Noël J.C. Bauer, MD, PhD, practices in the Department of Ophthalmology at the Academic Hospital, Maastricht, Netherlands. Dr. Bauer states that he is a consultant to Acri.Tec (now Carl Zeiss Meditec). He may be reached at e-mail: n.bauer@mumc.nl.

Rudy M.M.A. Nuijts, MD, PhD, is an Associate Professor of Ophthalmology in the Department of Ophthalmology at the Academic Hospital, Maastricht, Netherlands. He is a member of the CRST Europe *Editorial Board. Dr. Nuijts states that he is a consultant to Alcon Laboratories, Inc., Ophtec, and ASICO, and receives research funding from Alcon Laboratories, Inc., and Ophtec. He may be reached at e-mail: rudy.nuijts@mumc.nl.*

Nienke Visser, MD, is a doctoral (PhD) student in the Department of Ophthalmology at the Academic Hospital, Maastricht, Netherlands. Dr. Visser states that she has no financial interest in the products or companies mentioned. She may be reached at tel: +31 43 3877133; e-mail: nienke.visser@mumc.nl.

1. Ferrer-Blasco T, Montes-Mico R, Peixoto-de-Matos SC, et al. Prevalence of corneal astigmatism before cataract surgery. *J Cataract Refract Surg.* 2009;35:70-75.
2. Chang DF. Early rotational stability of the longer STAAR toric intraocular lens: fifty consecutive cases. *J Cataract Refract Surg.* 2003;29:935-940.
3. De Silva DJ, Ramkissoon YD, Bloom PA. Evaluation of a toric intraocular lens with a Z-haptic. *J Cataract Refract Surg.* 2006;32:1492-1498.
4. Linnola RJ, Sund M, Ylonen R, et al. Adhesion of soluble fibronectin, vitronectin, and collagen type IV to intraocular lens materials. *J Cataract Refract Surg.* 2003;29:146-152.
5. Bauer NJ, de Vries NE, Webers CA, et al. Astigmatism management in cataract surgery with the AcrySof toric intraocular lens. *J Cataract Refract Surg.* 2008;34:1483-1488.
6. AcrySof Single-Piece Posterior Chamber Intraocular Lenses with Toric Optic, models SA60T3, SA60T4 and SA60T5. U.S. Food and Drug Administration. Document number P930014/S15, 2005.
7. Chang DF. Comparative rotational stability of single-piece open-loop acrylic and plate-haptic silicone toric intraocular lenses. *J Cataract Refract Surg.* 2008;34:1842-1847.
8. Dardzhikova A, Shah CR, Gimbel HV. Early experience with the AcrySof toric IOL for the correction of astigmatism in cataract surgery. *Can J Ophthalmol.* 2009;44:269-273.
9. Mendicute J, Irigoyen C, Aramberri J, et al. Foldable toric intraocular lens for astigmatism correction in cataract patients. *J Cataract Refract Surg.* 2008;34:601-607.
10. Zuberbuhler B, Signer T, Gale R, et al. Rotational stability of the AcrySof SA60TT toric intraocular lenses: a cohort study. *BMC Ophthalmol.* 2008;8:8.
11. Weinand F, Jung A, Stein A, et al. Rotational stability of a single-piece hydrophobic acrylic intraocular lens: new method for high-precision rotation control. *J Cataract Refract Surg.* 2007;33:800-803.
12. Liekfeld A, Torun N, Friederici L. A new toric diffractive multifocal lens for refractive surgery. *Ophthalmologe.* 2010;107(3):256-261.
13. Peckar C. Rayner Centreflex Toric IOL shows stability in astigmatic eyes. Paper presented at: the XXIV Congress of the ESCRS; September 9-13, 2006; London.
14. Harman F, Sim K, Lee N. Evaluation of the Rayner T-flex toric intraocular lens. Paper presented at: the XXV Congress of the ESCRS; September 8-12, 2007; Stockholm, Sweeden.
15. Borkenstein AF, Reuland A, Limberger IJ, et al. Transscleral fixation of a toric intraocular lens to correct aphakic keratoplasty with high astigmatism. *J Cataract Refract Surg.* 2009;35:934-938.