Capsular Cleaning to Remove Lens Epithelial Cells

Results of Nd:YAG laser photolysis at 3 years are promising.

BY WOLFRAM WEHNER, MD; GEORGE O. WARING III, MD, FACS, FRCOPTH; RUDOLPH WALKER, PHD; AND REINHARDT THYZEL

Cataract surgery has become an almost routine procedure with low complication rates, and postoperative results have improved for a host of reasons, most of which are due to advances in phacoemulsification technology and new IOLs. Additionally, new multifocal and accommodating lens technologies are available to treat presbyopia by providing near, intermediate, and distance vision, which has resulted in an increase in refractive lens exchange (RLE) procedures. Advanced surgical techniques now allow smaller incisions with astigmatically neutral results. Despite such progress, posterior capsular opacification (PCO) continues to occur. This article reviews the use of capsular cleaning of lens epithelial cells to prevent PCO.

The Dodick Nd:YAG laser photolysis instrument (A.R.C. Laser, Nuremberg, Germany) was initially proposed for cataract removal. However, in 2001, Dodick and colleagues pioneered its use to remove lens epithelial cells as a form of PCO prevention in laboratory experiments (Reinhardt Thyzel, personal communication). Based on this work, we began to investigate a clinical technique for inhibiting PCO proliferation using the Dodick laser photolysis instrument in 2006.[1] One of us (WW) now uses the Dodick unit clinically, in addition to the standard ultrasound phaco technology, to disrupt the lens epithelial cells. Although this technology is used in standard cataract patients, it is especially useful in RLE and bimanual small-incision cases for astigmatism-free lens removal.

This technology works with single-use handpieces that deliver ultrafast shock wave pulses. These pulses are generated by laser absorption in the titanium tip of the handpiece, such that the shock wave and plasma emerge from the tip and disrupt the lens epithelial cells. The laser pulse itself remains within the instrument tip.

For our purposes, we had the system modified for lower laser energy. With this modification and using the same handpieces, we started to direct the shock wave pulses first to the inside of the anterior capsule, then to the capsulorrhexis edge, at single locations. After we determined that capsular rupture did not result, we started to clean 180° on the nasal side in a total of 17 patients. Enough pulses—up to 100 in total—were applied to cover an area of approximately 2 to 2.5 mm beside the rhexis edge. A video depiction of this technique is available at http://eyetube.net/v.asp?fofege.

NO SIGNS OF PCO IN TREATED AREAS

During follow-up of these early clinical cases, (3 years for 12 eyes and at least 2 years for 5 eyes), the portion of the anterior capsule treated with shock wave pulses stayed clear; any occurrence of PCO started from the untreated temporal side of the anterior capsule and proliferated over the posterior capsule. Interestingly, the untreated nasal side of the posterior capsule also stayed clear.

Both the nasal anterior and posterior capsule have remained clear in these initial cases up to 3 years. We postulate that the shock wave has a large enough beam

spread to impact and disrupt the lens equator germinal cells, thus preventing PCO in treated areas. We kept the instrument tip under direct visualization behind the anterior capsule, and did not attempt to insert it into the lens equator.

DISCUSSION

One problem we had to solve was protecting the posterior side of the iris. Because the anterior capsule is close to the iris, and the shock waves applied to the capsule pressed it against the iris, some trauma was inevitable. Iris trauma was clearly visible, as depigmentation occurred during the early cleaning procedures. The iris was subsequently protected by placing methylcellulose between it and the capsule.

Other ophthalmic viscosurgical devices \were also investigated with different outcomes. The higher the viscosity, the less suitable the substance was for our purposes. Because Healon (Abbott Medical Optics Inc., Santa Ana, California) blocked the capsule from movement, the shock wave forces caused the capsule to rupture on the Healon surface. We found that a minimally compressible and movable substance is ideal to protect the iris from shock-wave trauma.

With nasal-only cleaning, the temporal lens epithelial cells did not migrate across the posterior capsule nasally; they stopped in the middle of the capsule with a feathered appearance. Donor human eyes treated with the same system and technique by Nick Mamalis, MD, Director of the Ophthalmic Pathology Laboratory at the University of Utah, were studied to determine the cause of this migration pattern.[2] Light and electron microscopy showed absence of lens epithelial cells on intact capsules in treated areas. Immunohistologic studies of the capsular bag carried out at Emory University in Atlanta by Hans E. Grossniklaus, MD, demonstrated an absence of the attachment molecules laminin and fibronectin in the treated areas.[2] This study may explain why the remaining lens epithelial cells in our clinically treated eyes did not slide across the treated areas; they have no attachment carpet on which to move.

After 3 years of follow-up of the initial 180° cases, we now clean 360° of the circumference to overcome proliferation from the untreated areas. Follow-up in these 360° cases now extends more than 8 months and includes 30 eyes. These procedures appeared promising intraoperatively; however, we are now waiting for results from 1- to 2-year follow-up to determine the outcomes for PCO prevention.

CONCLUSION

With the Dodick Nd:YAG laser photolysis instrument, we believe that we have developed an attractive method to enhance the outcome of cataract surgery by preventing PCO. However, longer follow-up is needed to confirm early results. With this technique, new lens designs and developments may gain further importance, especially accommodating IOLs that rely on capsular movement and multifocal IOLs that need perfectly clear capsules for optimal function.

This year, we will conduct a five-center prospective clinical trial in Europe under the sponsorship of A.R.C. Laser and the medical directorship of George O. Waring, III, MD, FACS, FRCOphth. Right and left eyes of the same patients will be randomly assigned to capsular cleaning or control, and retroillumination slit-lamp photographs of the capsules will be taken and graded for clarity. This study will help to further define the technique. ■

TAKE-HOME MESSAGE

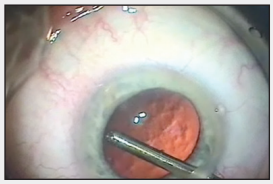

- With the Dodick laser modified for lower laser energy, the authors were able to direct shock wave pulses to the inside of the anterior chamber and the capsulorrhexis edge to clean 180° on the nasal side.
- The shock wave has a large enough beam spread to impact and disrupt the lens equator germinal cells, thus preventing PCO in treated areas.
- Eyetube direct link: http://eyetube.net/v.asp?fofege

Reinhardt Thyzel is the owner of A.R.C. Laser. He may be reached at e-mail: r.thyzel@arclaser.de.

R. Walker, PhD, is a salaried employee of A.R.C. Laser. He may be reached at e-mail: dr.walker@arclaser.de.

George O. Waring III, MD, FACS, FRCOpth, practices with InView Vision, Atlanta. Dr. Waring states that he is a paid consultant to A.R.C. Laser. He may be reached at tel: +1 404 642 2848; e-mail: drgeorge@georgewaring.com.

Wolfram Wehner, MD, is Head of the Operating Surgeons at the Maximilians Eye Clinic, Nuremberg, Germany. Dr. Wehner states that he has no financial interest in the products or companies mentioned. He may be reached at tel: +49 911 235510; e-mail: dr.w.wehner@t-online.de.

1. Pollhammer M, Meiller R, Rummelt C, Thyzel R, Cursiefen C, Kruse FE. In situ ablation of lens epithelial cells in porcine eyes with the laser photolysis system. *J Cataract Refract Surg.* 2007;33:697-701.
2. Mamalis N, Grossnicklaus HE, Waring GO, Werner L, Brubaker J, Davis D, Espandar L, Thyzel R, Walker R. Ablation of lens epithelial cells with a laser photolysis system: histopathology, ultrastructure, and immunochemistry. Accepted for publication in *J Cataract Refract Surg.*