

STEP BY STEP: INNOVATION IN ACTION

A unique alternative to traditionally sutured IOLs in a complicated exchange.

BY WILLIAM F. WILEY, MD



This video shows Brandon Ayres, MD, handling a complicated IOL exchange with an innovative technique that he pioneered. Dr. Ayres begins by removing a three-piece IOL that was captured in the iris after a vitrectomy and ends with an Akreos one-piece IOL (Bausch + Lomb) secured with a Gore-Tex (W.L. Gore & Associates) suture.

STEP BY STEP

Dr. Ayres first injects triamcinolone acetonide to rule out the presence of vitreous in the anterior chamber. He orients the 23-gauge trocar system 3 mm from the limbus and 2 mm lateral to the central mark (Figure 1). He places the CV-8 Gore-Tex suture via handshake through the main incision and out the trocar. When passing sutures via the sclera, it is key to place the more proximal suture through the trocar/sclera first, which helps decrease the risk of tangles (Figure 2). Once both sides of the lens are laced through the sclera, Dr. Ayres removes the trocars, leaving a nice opening

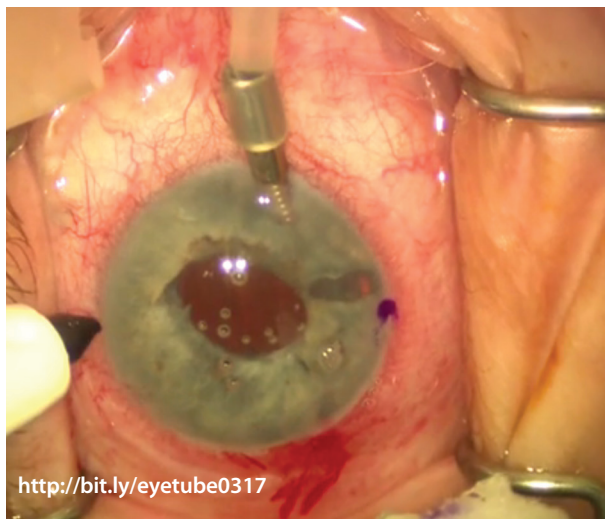


Figure 1. Dr. Ayres orients the 23-gauge trocar system 3 mm from the limbus and 2 mm lateral to the central mark.

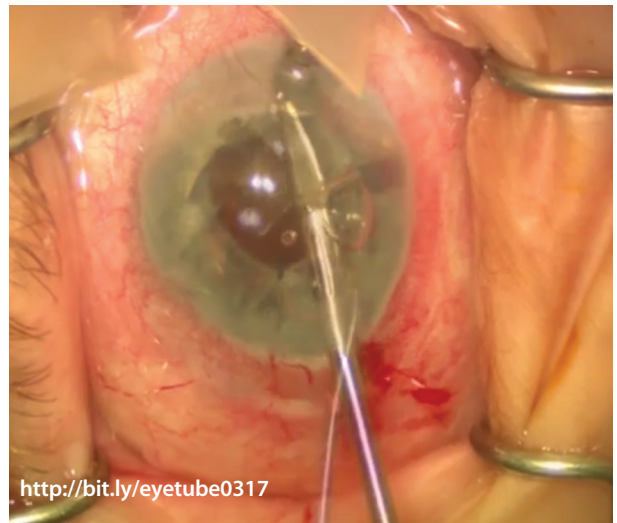


Figure 2. Placing the more proximal suture through the trocar/sclera first helps decrease the risk of tangles.

for burying the knot at the end of the case. He recommends slipknots to tighten the sutures to the lens optic in a balanced fashion, side to side to help ensure IOL centration. Dr. Ayres applies just enough tension to center the optic without folding it.

EYETUBE FOR INNOVATION

This case is a great example of using Eyetube.net to demonstrate a unique and well-accepted alternative to traditionally sutured IOLs. The Gore-Tex suture will not erode or break over time, and the unique design of the Akreos IOL's haptics promote a stable optic that is unlikely to tilt, as can occur with traditional PMMA IOLs secured with polypropylene sutures. ■

William F. Wiley, MD

- Private practice, Cleveland Eye Clinic, Ohio
- drwiley@clevelandeyeclinic.com
- Financial disclosure: None acknowledged