

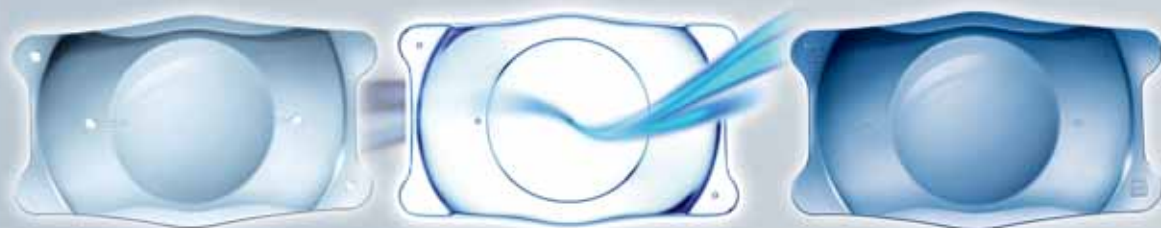Cataract & Refractive Surgery

TODAY

EUROPE

February 2012

VISIAN ICL



Highlights from the 2011 ICL/Toric
ICL Experts Symposium

Nighttime Vision With Low-Diopter ICL

In one measure of visual quality, the ICL outperforms LASIK.

BY GREGORY D. PARKHURST, MD

The armed forces are a unique population of individuals who are exposed to various environments, treacherous war zones, and frequent trauma. Due to the extreme nature of their surroundings and the intense demands placed on them, persons in the military must have excellent vision. The US Army has a conservative approach to adopting new technology; therefore, before any refractive surgery technique is approved for use, it must undergo studies to confirm stability and safety.

Since 2003, more than 160,000 members of the US armed forces have reportedly undergone successful refractive surgery procedures.¹ In 2007, the US Army began studying the use of phakic IOLs to correct refractive errors, specifically the Visian ICL (STAAR Surgical). The procedure was being studied on an investigational basis in soldiers at Army refractive surgery centers who were not candidates for laser vision correction. One of the centers that published results of this study was Fort Hood, Texas, which is home to approximately 42,000 soldiers and is the largest military installation in the world by land area. Approximately 4,000 refractive surgery procedures are performed each year at Fort Hood.

RETROSPECTIVE ANALYSIS

Several studies have been performed to test the safety and efficacy of the Visian ICL. In the first retrospective analysis performed at Fort Hood between June 2008 and July 2009, the preoperative characteristics and short-term postoperative outcomes were analyzed for the first 206 cases of ICL implantation. Preoperatively, the mean sphere, cylinder, and spherical equivalent were -5.86 D (range, -2.50 to -11.00 D), -0.68 D (range, 0.00 to -2.25 D), and -6.20 D (range, -2.63 to -11.50 D), respectively, and the standard deviations were 1.92, 0.51, and 2.04, respectively. A total of 139 eyes were available for 3-month follow-up. At 3 months, 96% of eyes had achieved a UCVA of 20/20 or better, and 67% of eyes had achieved a UCVA of at least 20/15. Only six eyes did not achieve at least 20/20 UCVA, all of which had 1.25 D or more of cylinder before surgery.

At 3 months, the average targeted spherical equivalent was -0.22 D; the average achieved spherical equivalent was -0.17 D. Of the 132 available eyes having postoperative manifest refraction, 89% were within ± 0.50 D of intended

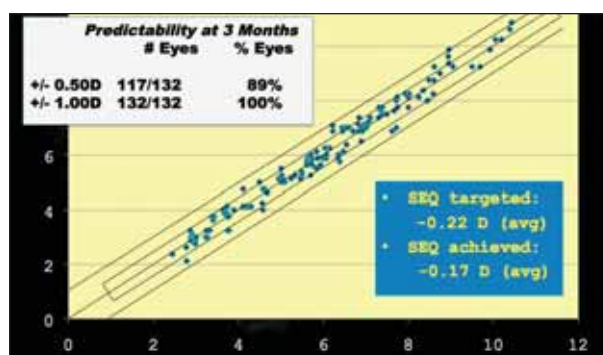


Figure 1. Refractive predictability plot for 13 eyes that underwent ICL implantation.

correction, and 100% were within ± 1.00 D of intended correction (Figure 1).

The safety index for ICL implantation was 1.78, with 34% of patients gaining at least 1 line of BCVA. Thirteen percent of patients gained 2 lines, 21% gained 1 line, and 65% of patients neither lost nor gained lines of BCVA. The efficacy index was 1.15, with 79% of patients achieving the same or better UCVA compared with the preoperative BCVA. Only 4.8% of patients reported occasional glare and halos, which was related to the iridotomy in two cases. In one eye, iritis developed 1 month after surgery. Three ICLs were explanted, one for excessive vault and two for human error in lens power selection. Lastly, one patient experienced new-onset nyctalopia. There was no incidence of postoperative endophthalmitis, retinal detachment, postoperative cystoid macular edema, pigment dispersion, iris chafing, corneal decompensation, or cataract.

From this retrospective study, the authors concluded that early results showed the Visian ICL to be effective in this population when corneal topography or residual bed thickness was in question for LASIK. Between June 2008 and December 2010, we implanted the ICL in 792 of the 9,357 refractive surgery cases performed at Fort Hood.

PROSPECTIVE NIGHT VISION ANALYSIS

The second study we performed was a prospective comparative analysis of 95 eyes that underwent Visian ICL implantation or LASIK. All eyes were matched by degree of myopia (range, -3.00 to -11.50 D) and had no more than

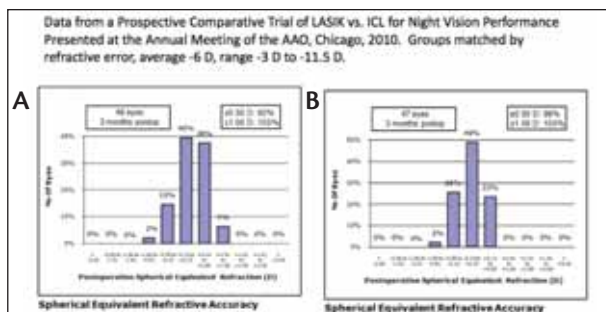


Figure 2. Refractive accuracy in the (A) LASIK and (B) ICL groups.

2.25 D of astigmatism. Visual testing and aberrometry as well as interpretation of the results were performed by individuals who were blinded to the procedure. The study was nonrandomized, as the ICL is still used on an investigational basis in non-LASIK candidates (ie, patients with thin corneas, abnormal topography, corneal scars, etc.).

The LASIK cohort included 24 patients (48 eyes) for whom a surgeon-specific nomogram adjustment (DataLink; Surgivision Consultants) was used to select the treatment profile for the laser ablation (400-Hz Allegretto Wave; Alcon Laboratories, Inc.). Flap creation was performed using a femtosecond laser (IntraLase; Abbott Medical Optics Inc.). In all 24 ICL patients (47 eyes), a laser peripheral iridotomy was performed before lens implantation, and during surgery a primary incision was placed temporally or on the steep axis of corneal cylinder. No astigmatic treatments (limbal relaxing incisions or bioptics) were performed.

Outcome measures included refractive accuracy, photopic visual acuity and contrast sensitivity, aberrometry, and night vision acuity and contrast sensitivity. Preoperatively, the mean spherical equivalent before surgery was -6.04 in the LASIK group and -6.1 in the ICL group ($P=NS$), and the mean preoperative astigmatism and pachymetry were 0.96 D and 0.60 D and 571.3 μ m and 547.3 μ m, respectively, in each group.

Three months after surgery, almost all (98%) eyes in the ICL group were within ± 0.50 D of intended correction, and

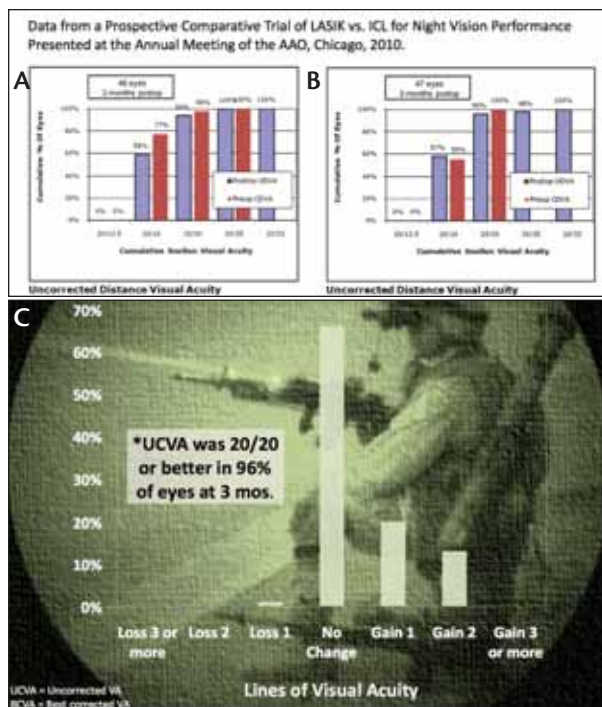


Figure 3. Distance UCVA in (A) LASIK and (B) ICL patients at 3 months. (C) Change in BCVA at 3 months.

92% in the LASIK group were within the same intended correction (Figure 2). In reference to distance UCVA at 3 months, 96% of eyes were 20/20 or better, including cases with up to 1.50 D of astigmatism and/or abnormal corneas, compared with 94% of patients in the LASIK group comprised of normal corneas (Figure 3). Although there was no significant difference in photopic visual acuity between the groups, only eyes in the ICL group experienced a significant improvement in photopic contrast sensitivity at 3 months. Additionally, low luminance visual acuity improved significantly in the ICL group, whereas there was no statistically significant improvement in the LASIK group. Both groups experienced a significant improvement in low luminance contrast sensitivity, and the improvement was statistically significantly greater in the ICL group ($P=.040$). This may be

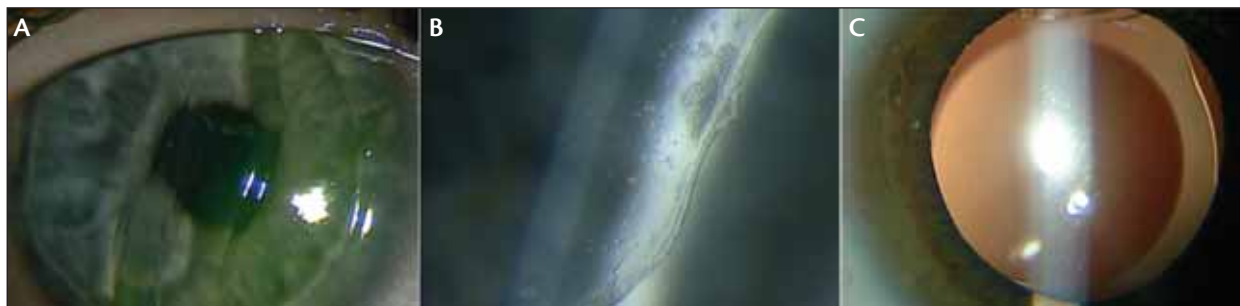

Figure 4. (A) During long-jump training, this patient took a reflector belt to the eye 10 months after LASIK. (B) Epithelial ingrowth was seen 2 weeks after flap repositioning in this case, and the patient's UCVA worsened to 20/50. (C) This patient was hit with an elbow in the eye 8 months after ICL implantation. The ICL was rotated vertically, and the patient's UCVA remained 20/20; no cataract developed.

due to a greater induction of higher-order aberrations that was seen after LASIK as compared with ICL implantation.

CONCLUSION

To date, after more than 1,500 cases of ICL implantation at various Army refractive surgery centers, there have been zero reported cases of retinal detachment, endophthalmitis, postoperative cystoid macular edema, or traumatic lens dislocation. Although there is no way to quantify all types of potential eye trauma, the procedure has seemed to hold up well to trauma in a few known case reports (Figure 4). In studies performed thus far, the ICL has provided sharp vision and excellent low luminance contrast sensitivity, two important aspects for soldiers and other patients who function at night. For these reasons, I consider ICL implantation a viable option for refractive correction in troops. ■

Gregory D. Parkhurst, MD, is a cataract and refractive surgeon at McFarland Eye Centers, Little Rock, Arkansas. Dr. Parkhurst states that he has no financial interest in the products or companies mentioned. He may be reached at e-mail: Gregory.Parkhurst@gmail.com.



The views expressed in this article are those of the authors and do not reflect the official policy or position of the Department of the Army, Department of Defense, or the US Government. Opinions, interpretations, conclusions, and recommendations herein are those of the authors and are not necessarily endorsed by the US Army.

1. Parkhurst GD, Psolka M, Kezirian GM. Phakic intraocular lens implantation in United States military warfighters: A retrospective analysis of early clinical outcomes of the Visian ICL. *J Refract Surg.* 2011.

Revolutions in Refractive Surgery

A review of anterior chamber phakic IOLs.

BY GEORGES BAIKOFF, MD

When I started implanting phakic IOLs many years ago, there was no available device to image the anterior segment. At the time, the small number of us surgeons implanting these lenses were pioneers of the technology. We did not know exactly where the best placement of the lens was, nor could we predict our patients' postoperative results. Over time, we learned that in order to have excellent postoperative results, we needed to respect certain distances in the anterior chamber, including clearance between the lens and the endothelium (Figure 1).

Today, we not only have the necessary tools to image the anterior segment, but we also have state-of-the-art phakic lenses that provide patients with superior visual quality. One of these lenses is the Visian ICL (STAAR Surgical). The V4b, and now the V4c, has an expanded treatment range that allows refractive surgeons to treat all patients—those who are both ineligible and eligible for LASIK. The newest design is the V4c, which includes Centraflow technology with the KS-Aquaport. This revolution in phakic IOL design has simplified the surgical procedure, eliminating the need for a peripheral iridotomy before implantation.

EARLY PHAKIC IOL DESIGNS

The culmination of the V4c lens design is a product of years of trial and error with other phakic IOLs. The first attempt at using an anterior chamber refractive lens to correct high myopia in the phakic eye occurred in the 1950s.

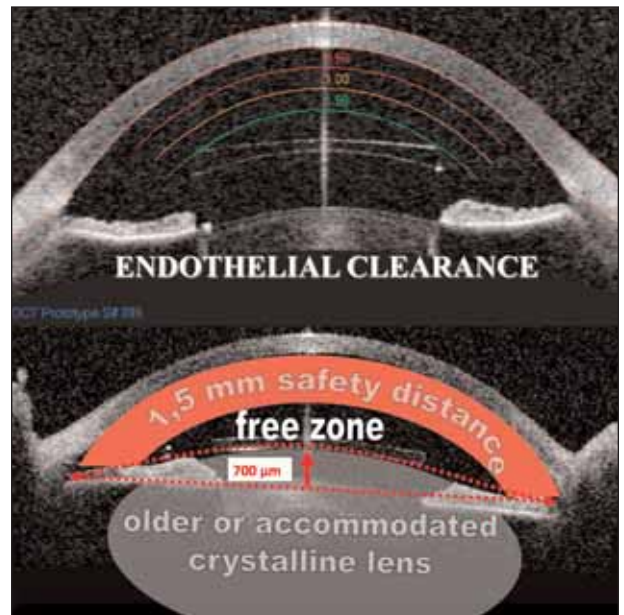


Figure 1. There must be adequate clearance between the edges of the phakic IOL and the endothelium.

Complications including glaucoma, corneal dystrophy, and hyphema were associated with imperfections in the lens design,¹ and these efforts were abandoned. More than 30 years after the initial effort to design a phakic lens, I, along with Svyatoslav N. Fyodorov, MD, of Moscow, and Paul U.

Fechner, MD, of Germany, tried to develop phakic IOLs. Dr. Fyodorov's efforts ultimately led to the development of several phakic IOL concepts that are still in use today, including the design of the Visian ICL. The implant that I designed was an angle-supported implant, the ZB Baikoff Phakic IOL (Domilens GmbH). This one-piece phakic IOL had a PMMA haptic and optic. Because of its rigid design, it was inserted through a 5.5-mm incision. To prevent endothelial loss, at least 1.5 mm was left in between the edges of the optic and the endothelium. To date, many of these lenses have been explanted.

The Artisan phakic IOL (Ophtec BV) is another model that had a rocky beginning. It also has a one-piece lens design with a PMMA haptic and optic that is implanted through a 5.5-mm incision. One of the major differences from the ZB Baikoff implant is that it is an iris-fixated design; this design can cause late considerable endothelial cell loss, and therefore safety in the earlier models was questionable. In our study, this lens had a 6% rate of pigment dispersion.

Other phakic lens designs that enjoyed limited successes include the Vivarte phakic IOL and the Newlife. The Vivarte showed good safety at 3 years, but after this point endothelial cell loss started to occur and was higher than the typically acceptable rate of 2%.

The main problem with anterior chamber phakic IOLs was that they seemed to cause pigment dispersion, which was mainly due to the forward motion of the crystalline

lens. Most of these lens styles have since been removed from the eyes of our patients, as pigment dispersion synechiae on the surface of the capsule can cause cataract.

Today, refractive results after phakic IOL implantation are stable, thanks to new posterior chamber lens designs, and there are fewer optical aberrations compared with LASIK.^{2,3} Phakic lenses surely have come a long way since the early 1980s, and thankfully we have a winning formula with the posterior chamber phakic IOL design.

CONCLUSION

To summarize, anterior chamber phakic IOLs cause various complications that likely warrant removal of the lens. For this reason, I believe it is important to mainly use a posterior chamber phakic IOL. ■

Georges Baikoff, MD, is Director and Professor of Eye Surgery at the Ophthalmology Centre of the Monticelli Clinic, Marseilles, France. Dr. Baikoff states that he has no financial interest in the products or companies mentioned. He may be reached at tel: +33 491 16 22 28; e-mail: g.baik.opht@wanadoo.fr.



1. Baikoff G, Lutun E, Ferraz C, et al. Analysis of the eye's anterior segment with an optical coherence tomography: static and dynamic study. *J Cataract Refract Surg.* 2004;30:1843-1850.
2. Baikoff G, Lutun E, Ferraz C, et al. Refractive Phakic IOLs: contact of three different models with the crystalline lens, an AC OCT study case reports. *J Cataract Refract Surg.* 2004;30:2007-2012.
3. Baikoff G, Bourgeon G, Jitsuo Jodai H, et al. Pigment dispersion and artisan implants. The crystalline lens rise as a safety criterion. *J Cataract Refract Surg.* 2005;31:674-680.

The Visian ICL: A Less-Invasive Refractive Surgery Procedure

Implantation of a phakic IOL does not require a flap cut.

BY JOSÉ F. ALFONSO, MD, PhD

Two of the largest drawbacks for a young ophthalmologist just beginning his or her career in refractive surgery are the surgical complications associated with conventional microkeratome cuts and the cost of owning a femtosecond laser to create a LASIK flap. Fortunately, microkeratome cuts and femtosecond-laser assisted flaps are no longer required to provide patients with the best refractive results, thanks to modern PRK techniques and new phakic IOLs. These two strategies adequately correct most ametropies and provide us with the fundamental criteria of efficacy, safety, and predictability that our patients need. In this article, I demonstrate these arguments.

I have more than 25 years of experience performing excimer laser ablations including PRK as well as LASIK (with

and without a femtosecond laser), phakic IOL implantation, and refractive lensectomy. Most of our complications after PRK have been eliminated by intraoperative use of mytomicin C and postoperative application of sodium hyaluronate and contact lenses for the first week after surgery. In less than 72 hours after PRK, the wound heals, and within the first week the patient can resume normal activities. The range of correction with PRK is between -5.00 and 2.50 D of sphere, with up to 5.00 D of astigmatism.

PREFERRED STRATEGY FOR REFRACTIVE CORRECTION

My preferred refractive strategy, however, is implantation of a posterior chamber phakic IOL, such as the

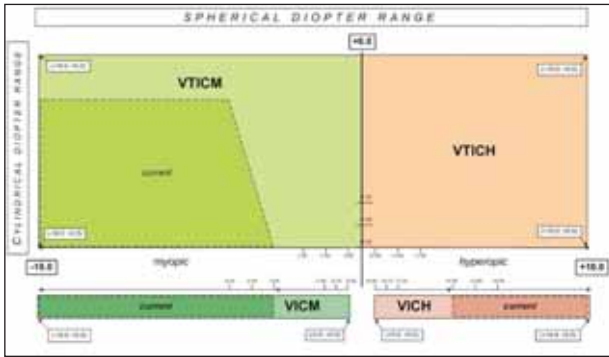


Figure 1. The spherical dioptric range of the Visian ICL spans from -18.00 D to 10.00 D.

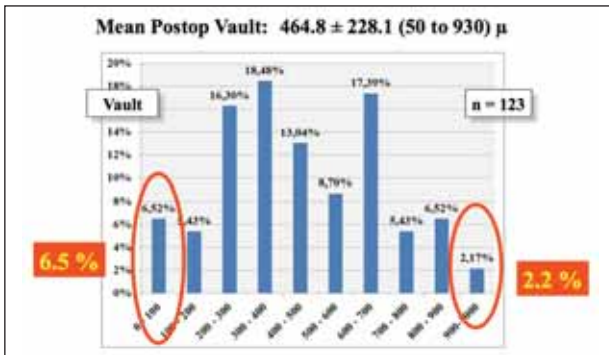


Figure 3. The mean postoperative vault in this population of eyes was $464.8 \pm 228.1 \mu\text{m}$.

Visian ICL (STAAR Surgical). Beyond the good optical quality, phakic IOLs have a large dioptric range (Figure 1), allowing us to correct practically any refractive error. Additionally, because this lens has a large dioptric range (-18.00 to 10.00 D), we can marry lens implantation with PRK to avoid the need for LASIK.

Numerous studies have demonstrated their good visual results.¹⁻⁵ In our last study of 123 eyes (71 patients), we implanted the V4b ICL. The mean preoperative sphere was -8.20 ± 3.34 D, which improved to -0.09 ± 0.28 D after surgery. Mean cylinder improved from -0.90 ± 0.68 D before surgery to -0.26 ± 0.39 after surgery. Distance BCVA improved as well, from 0.90 ± 0.10 before surgery to 1.0 ± 0.1 after surgery.

We also showed the safety of the technique, as all eyes had the same or better vision after lens implantation (Figure 2). The predictability is excellent, with more than 93% of eyes reaching the target refraction and, because of modern sizing nomograms based on optical coherence tomography and ultrasound biomicroscopy, we achieved a safe vault in more than 90% of eyes (Figure 3). Cataract formation was also easily avoided by optimizing the calculation for selecting ICL size as well as exchanging the ICL if contact with the crystalline lens occurred. However, several studies have confirmed that the incidence of cataract after ICL implantation is approximately 1.3%.^{2,6-8}

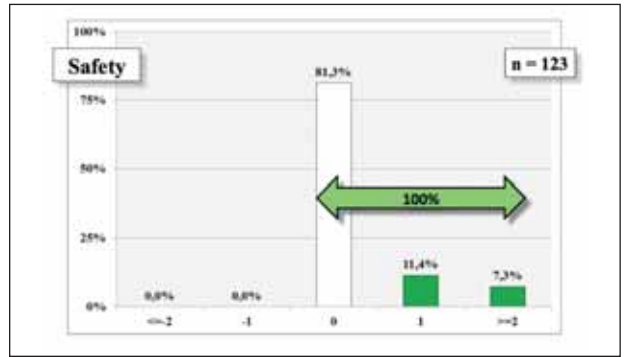


Figure 2. Safety profile of 123 eyes implanted with the Visian V4b.



Figure 4. The new Visian V4c has a hole in the center of the optic.

A NEW DESIGN, A NEW STRATEGY

In addition to cataract formation, some surgeons are worried about inducing a pupillary block after phakic IOL implantation. Previously, surgeons had to perform an iridectomy before surgery; however, the newest Visian ICL, the V4c, has a perforating central hole that allows aqueous humor flow without the need of an iridectomy. We recently started implanting this lens (Visian V4c; Figure 4) and are impressed with the normal values of intraocular pressure measured immediately after surgery. The surgery is easier and faster than with previous models. Going back to those young ophthalmologists just starting their refractive surgery careers, even the novel surgeon can perfect this procedure, as there is only a short learning curve.

In addition to using the new V4c in my patients, I have also started to combine ICL implantation with the use of intrastromal corneal ring segments (ICRSs). This is an effective technique for patients with keratoconus who also desire a large refractive correction. With this strategy, the main objective is to correct the corneal astigmatism with the ICRSs and the sphere with the ICL. Any residual astigmatism can then be treated with limbal relaxing incisions performed during the ICL surgery.

CONCLUSION

Phakic IOLs are an excellent choice to correct refractive errors for various reasons. In addition to the benefits of eliminating the need for flap creation, whether that is with a conventional microkeratome or femtosecond laser, phakic IOLs also provide patients with good optical quality. Specifically, the large dioptric range of the Visian ICL allows me to correct practically any refractive error, leaving my

patients satisfied. I prefer ICL implantation over all other strategies and have started combining it with procedures such as PRK and ICRS implantation for even better results. ■

José F. Alfonso, MD, PhD, practices at the Fernández-Vega Ophthalmological Institute, Surgery Department, School of Medicine, University of Oviedo, Spain. Dr. Alfonso states that he has no financial interest in the products or companies mentioned. He may be reached at tel: +34 985245533; fax: +34 985233288; e-mail: j.alfonso@fernandez-vega.com.



1. Alfonso JF, Fernández-Vega L, Lisa C, Fernandes P, Jorge J, Montés Micó R. Central vault after phakic intraocular lens implantation: Correlation with anterior chamber depth, white-to-

white distance, spherical equivalent, and patient age. *J Cataract Refract Surg.* 2012;38:46-53.
 2. Alfonso JF, Baamonde B, Fernández-Vega L, Fernandes P, González-Méijome JM, Montés-Micó R. Posterior chamber collagen copolymer phakic intraocular lenses to correct myopia: five-year follow-up. *J Cataract Refract Surg.* 2011;37:873-880.
 3. Alfonso JF, Baamonde B, Madrid-Costa D, Fernandes P, Jorge J, Montés-Micó R. Collagen copolymer toric posterior chamber phakic intraocular lenses to correct high myopic astigmatism. *J Cataract Refract Surg.* 2010;36:1349-1357.
 4. Alfonso JF, Fernández-Vega L, Fernandes P, González-Méijome JM, Montés-Micó R. Collagen copolymer toric posterior chamber phakic intraocular lens for myopic astigmatism: one-year follow-up. *J Cataract Refract Surg.* 2010;36:568-576.
 5. Alfonso JF, Lisa C, Abdelhamid A, Fernandes P, Jorge J, Montés-Micó R. Three-year follow-up of subjective vault following myopic implantable collamer lens implantation. *Graefes Arch Clin Exp Ophthalmol.* 2010;248:1827-1835.
 6. Sanders DR. Anterior subcapsular opacities and cataracts 5 years after surgery in the visian implantable collamer lens FDA trial. *J Refract Surg.* 2008;24:566-570.
 7. Alfonso JF, Lisa C, Palacios A, Fernandes P, González-Méijome JM, Montés-Micó R. Objective vs subjective vault measurement after myopic implantable collamer lens implantation. *Am J Ophthalmol.* 2009;147:978-983.
 8. Fernandes P, González-Méijome JM, Madrid-Costa D, Ferrer-Blasco T, Jorge J, Montés-Micó R. Implantable collamer posterior chamber intraocular lenses: a review of potential complications. *J Refract Surg.* 2011;27:765-776.

Toric ICL Implantation After CXL to Correct Ametropia in Keratoconic Eyes

Comparison of visual outcomes.

BY MOHAMED SHAFIK, MD, PhD

In the early stages of keratoconus, corneal integrity can be restored using several different approaches, including corneal collagen crosslinking (CXL) to increase corneal rigidity, intrastromal corneal ring segments (ICRS) to flatten the cornea and change its refraction, and various forms of keratoplasty to replace the damaged cornea with a healthy donor. Regardless of the strategy, the goal of keratoconus treatments is to correct the patient's distorted vision and, if caught early enough, spare the cornea from the need for transplantation.

The newest of these keratoconus treatments is CXL. This minimally invasive procedure uses riboflavin and ultraviolet light to increase the crosslinks in corneal collagen, thus flattening the keratometric values, improving UCVA and BCVA, arresting the progression of keratoconus, and possibly preventing further deterioration of vision. The results after CXL are typically significant in the first 6 months following the procedure and then stabilize thereafter.

The ultimate goal of CXL is to produce a central shift of the cone, leading to a stable refraction; however, CXL does not treat the previous refractive error, and therefore the patient must continue relying on glasses or contact lenses for correction of sphere and cylinder. In our high-demand society, patients expect refractive procedures to offer a

solution for all refractive errors. Therefore, I now offer patients a combination procedure: toric phakic IOL implantation after CXL. This strategy provides patients with a practical solution to correct ametropia in a stable, crosslinked keratoconus eye. I started using this combined procedure in July 2008, implanting the Visian Toric ICL (STAAR Surgical) approximately 9 months after CXL to correct the residual spherical and cylindrical refractive errors.

STUDY

My results with this combination strategy are promising. I now have 18-month follow-up for 16 eyes, all of which were keratoconic and had no history or physical signs of ocular disease (other than myopia); UCVA was 20/40 or worse, and intraocular pressure was below 20 mm Hg. All eyes had a normal anterior segment (anterior chamber depth of 3 mm or greater), a clear cornea 9 months after CXL, and a stable subjective refraction for at least 3 months before Toric ICL implantation. For each case, the lens power was determined based on the patient's subjective refraction of sphere, cylinder, and axis. The preoperative mean BCVA was 0.63 ± 0.14 . After surgery, the mean UCVA was 0.88 ± 0.18 , with all eyes gaining 1 or more lines (Figure 1). I believe these outcomes were the result of combining

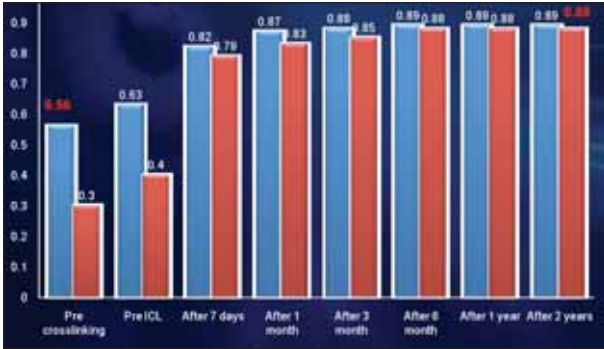


Figure 1. BCVA (blue) and UCVA (red) before CXL; before ICL implantation; 7 days and 1, 3, and 6 months after ICL implantation; and 1 and 2 years after ICL implantation.

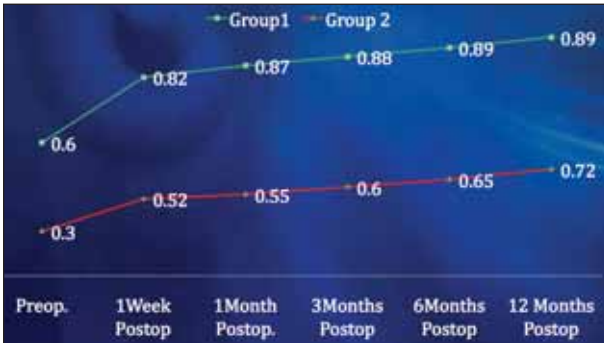


Figure 3. BCVA in the ICL (group 1) and ICRS (group 2) groups before and at 1 week and 1, 3, 6, and 12 months after surgery.

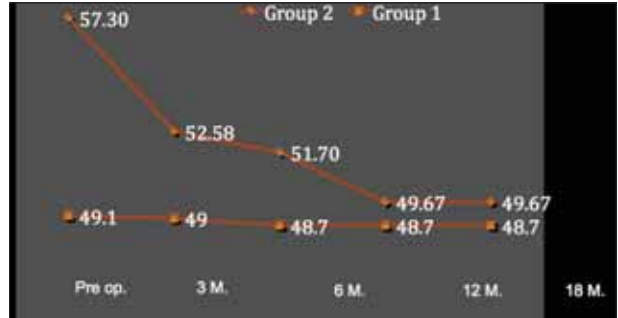


Figure 2. Mean keratometry in the ICL (group 1) and ICRS (group 2) groups before and at 3, 6, and 12 months after surgery.

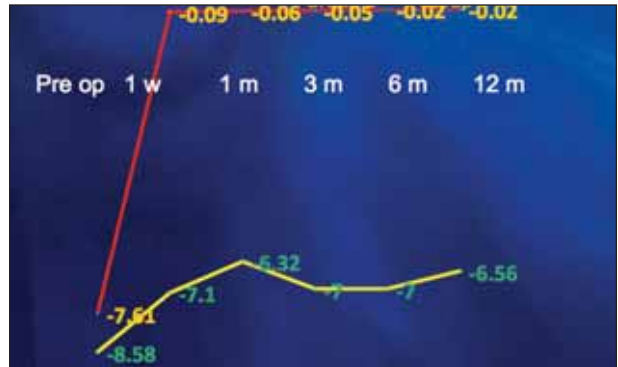


Figure 4. Spherical equivalent in the ICL (group 1; red) and ICRS (group 2; yellow) groups at 1 week and 1, 3, 6, and 12 months after surgery.

CXL with Toric ICL implantation, as the CXL flattened the cornea and improved corneal symmetry, and the Toric ICL corrected residual sphere and cylinder to overcome the aberrations induced by the previous corneal irregularity.

Results in these eyes were compared with the results of 20 keratoconic eyes that underwent ICRS implantation followed by CXL on the next day. The mean age in both groups was similar (25.6 ± 4.1 years in the ICL group vs 29.7 ± 2.6 years in the ICRS group), and there were no intra- or postoperative complications in either group. At 12 months, the mean keratometry reading was 48.7 in the ICL group and 49.67 in the ICRS group (Figure 2). At 1 week postoperative, the mean improvement in BCVA was 0.22 in both groups. By 12 months postoperative, BCVA gradually increased a total of 0.29 in the ICL group and 0.42 in the ICRS group (Figure 3). Additionally, the spherical equivalent in the ICL group was -0.09, -0.06, -0.05, -0.02, and -0.02 at 1 week and 1, 3, 6, and 12 months, respectively in the ICL group compared with -7.10, -6.32, -7.00, -7.00, and -6.56 in the ICRS group (Figure 4).

Analyzing these results revealed that ICRS implantation is a valuable solution for stabilizing keratoconus, especially in combination with CXL. However, ICRS implantation with or without CXL fails to correct the ametropia associated with keratoconus. We consider Toric ICL implantation after

CXL to be a superior treatment, as it corrects refractive errors after CXL is used to stabilize keratoconus. Visual acuity after Toric ICL implantation and CXL is also better than the BCVA after ICRS implantation and CXL.

CONCLUSION

As we know, keratoconus negatively affects not only our patient's quality of vision, including myopia and astigmatism, but their quality of life as well. Among available treatment options, I believe that Toric ICL implantation after CXL is the most promising modality we have to stop the progression of keratoconus and correct refractive errors, including sphere and cylinder. CXL alone only has the power to stabilize the cornea and the refraction, but without a subjective refraction, it is almost impossible to produce perfect correction of refractive errors. That is why, together, CXL and Toric ICL implantation is my procedure of choice in patients with keratoconus. ■

Mohamed Shafik, MD, PhD, is a Professor of Ophthalmology, University of Alexandria, and Director of Horus Vision Correction Center, Egypt. Dr. Shafik states that he has no financial interest in the products or companies mentioned. He may be reached at e-mail: m.shafik@link.net.

