

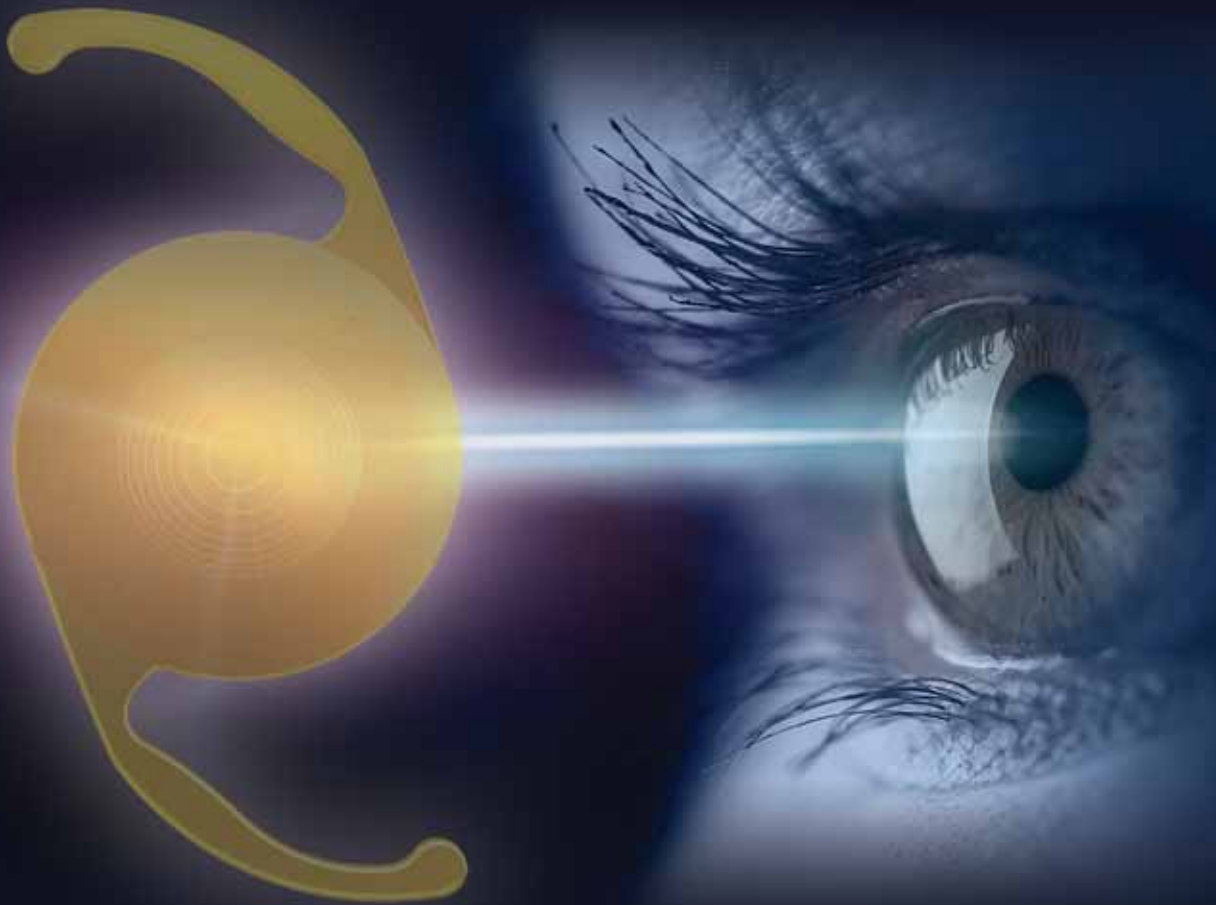
# Cataract & Refractive Surgery

**EUROPE**

Sponsored by Alcon Laboratories, Inc.

**TODAY**

## ADVANCED TECHNOLOGY IOLs AND LASERS



Data from the Alcon European user meeting in Prague, June, 2011.

# Merging Subspecialties Make for Exciting Times



It is exciting to be entering an era where it is appropriate to discuss cataract surgery and IOLs alongside excimer and femtosecond laser technologies. Ideally, all ophthalmic patients wish to rely on glasses as infrequently as possible.

Thanks to technological advances in lasers and IOLs in recent years, we now have the ability to meet this desire for both cataract and refractive patients. Cataract surgery has been adopting a more refractive focus for the past several years with IOLs that offer multifocality, asphericity, toricity, and other advantages (Figure 1). This trend gave birth to the term *refractive cataract surgery*. Also, a recent addition to phakic IOLs enables us to treat moderate-to-high myopes, thereby expanding our treatment range.

Refractive surgery continues to evolve as well. We are now able to perform customized Wavefront-Optimized, topography-guided, and asphericity-guided treatments, which we can combine with femtosecond-laser-created corneal flaps for a precise, bladeless surgery. In fact, the applications of the femtosecond laser have expanded greatly: the advanced software in the WaveLight FS200 Femtosecond Laser (Alcon Laboratories, Inc.; Figure 2) enables us to individually determine a flap's shape and diameter and the position and size of the hinge, as well as to adjust the angle for the sidecut. In addition to flap cutting, this new femtosecond laser integrates sub-Bowman's keratomileusis, intracorneal ring segment surgery, and lamellar and penetrating keratoplasties.

In this monograph, respected ophthalmologists describe these advanced technologies and their clinical experience with them. We hope that you will glean some pearls that will assist you in your own practice. ■

—Thomas Kohlen, MD, PhD, FEBO



Figure 1. The AcrySof IQ ReSTOR Toric IOL.




Figure 2. The WaveLight Refractive Suite.

## Contents

- |   |   |
|---|---|
| <p><b>3 Intraocular Stability of the AcrySof CACHET PHAKIC LENS</b><br/>By Thomas Kohlen, MD, PhD, FEBO</p> <p><b>5 Clinical Update on the AcrySof IQ ReSTOR Toric IOL</b><br/>By Patrick Desprez, MD</p> <p><b>8 Clinical Experience With the AcrySof Toric IOL</b><br/>By A. John Kanellopoulos, MD</p> | <p><b>10 IOL Calculations After Refractive Surgery</b><br/>By Warren E. Hill, MD</p> <p><b>13 Ensuring Patient Satisfaction With Multifocal Implants</b><br/>By Arthur B. Cummings, MB ChB, FCS(SA), MMed(Ophth), FRCS(Edin)</p> <p><b>15 Performance of New Femto and Excimer Laser Technologies</b><br/>By Prema Padmanabhan, MD, and Matthias Maus, MD</p> |
|---|---|

# Intraocular Stability of the AcrySof CACHET PHAKIC LENS

My clinical experience.

BY THOMAS KOHNEN, MD, PhD, FEBO

Phakic IOLs are well known for their efficacy in correcting moderate-to-high myopia. The AcrySof CACHET PHAKIC LENS (Alcon Laboratories, Inc.) is designed to be placed in the angle of the anterior chamber and to minimize the inflammatory response postoperatively. The lens has 7 years' experience in Europe,<sup>1,2</sup> and it is currently in clinical trials in the United States (per a submitted pre-market approval application to the U.S. Food and Drug Administration in September 2009). Here, I will share data from a recent clinical comparison of the AcrySof CACHET PHAKIC LENS and other phakic IOLs regarding the stability of their positioning in the anterior chamber.

## ACRYSOFT CACHET PHAKIC LENS DESIGN AND THE LENS POSITION

The AcrySof CACHET PHAKIC LENS is a single-piece, foldable IOL intended for placement in the anterior chamber in patients with moderate-to-high myopia. The lens is available in powers from -6.00 to -16.50 D and in four overall diameters: 12.5, 13.0, 13.5, and 14.0 mm, with a 6.00-mm meniscus optic. A "low-force" four-point bridged haptic design stabilizes the lens in the anterior chamber and maintains its vault (Figure 1; see the brief summary of the *Directions for Use for the AcrySof CACHET PHAKIC LENS* on the back page).

In a cohort that was part of the AcrySof CACHET IOL's FDA clinical trial, a colleague and I conducted a prospective, nonrandomized clinical trial in 2010 in which we examined this lens' postoperative positional stability.<sup>3</sup> We implanted 26 moderate-to-high myopes with the AcrySof CACHET IOL in diameters of 12.5, 13.0, and 13.5 mm. Then, we used Scheimpflug imaging preoperatively and at 1, 3, 6, 12, and 24 to 36 months postoperatively to measure the patients' corneal thickness, distance between the corneal endothelium and the anterior surface (EA) of the AcrySof CACHET IOL, the IOL's thickness, distance between the posterior surface of the PIOL and the anterior surface of the crystalline lens (PL), and the anterior chamber depth (cACD=CT+EA+LT+PL) (Figure 2).

Our evaluation of 22 eyes of 26 patients who completed all follow-up examinations showed no statistically significant difference in the AcrySof CACHET IOL's position during the 3-year study period. The overall change in clearance totaled 0.08 mm for the EA and 0.05 mm for the PL. The lens was well positioned and maintained adequate central clearance distances to the corneal endothelium and the natural crystalline lens during the 3 years (Figure 3).



Figure 1. The AcrySof CACHET PHAKIC LENS.

## POSITION OF OTHER PHAKIC IOLs

In 2004, my colleagues and I evaluated the positional stability of three phakic IOLs.<sup>4</sup> Of the 46 eyes in the




Figure 2. The intraocular spaces measured in the author's series with the AcrySof CACHET IOL.<sup>3</sup> (Reprinted with permission from Elsevier. Thomas Kohnen, Oliver K. Klapproth. Three-year stability of an angle-supported foldable hydrophobic acrylic phakic intraocular lens evaluated by Scheimpflug photography. *J Cataract Refract Surg*. 2010;36(7):1120-1126.)

study, 10 received an anterior chamber, angle-supported lens (the NuVita lens; Bausch + Lomb); 20 received an anterior chamber, iris-fixated implant (the Artisan IOL; Ophtec BV); and 16 eyes received a ciliary sulcus-implanted phakic IOL (the Visian ICL; STAAR Surgical Company). We evaluated the distance between the phakic IOL and the crystalline lens and the cornea as well as the rotation around the optical axis using Scheimpflug photography at 1, 3 to 6, and 12 months after surgery and generally found good IOL positioning with little movement over time. Four of the Nuvita lenses, however, rotated more than 10°. We must consider whether this so-called *propeller effect* occurs intraoperatively or long term, because long-term instability prevents astigmatic correction. The angle-supported anterior chamber phakic IOLs showed a generally stable position regarding distance to cornea and natural lens, aside from the four that rotated. However, the iris-fixated phakic IOL showed the highest overall stability. The posterior-chamber phakic IOL was stable in terms of rotation but had a tendency to decrease in distance toward the crystalline lens.

**LENS POSITION DURING ACCOMMODATION AND DEFOCUS CURVES**

In another study, my colleagues and I evaluated the positional stability of the AcrySof CACHET IOL during accommodation, and we also examined the preoperative and 1-month postoperative defocus curves of 50 eyes (25 patients) implanted with this lens using the Visante OCT. We captured defocus stimuli of -7.00 D to +1.00 D in 1.00 D steps, taking one horizontal scan per stimulus. We evaluated the pupil diameter, anterior chamber depth, the distance from the endothelium to the phakic IOL lens (M1), and the distance from the phakic IOL to the crystalline lens (M2). We also measured the subjects' visual acuity using ETDRS charts, both preoperatively and at 1 month postoperatively at 4 meters.

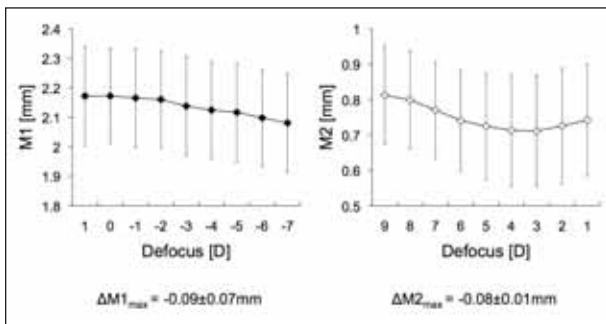


Figure 4. There was little change in the pupil diameter or the anterior chamber depth with accommodation (preliminary results).

$\Delta CT \pm SD$ [mm]	$\Delta EA \pm SD$ [mm]	$\Delta LT \pm SD$ [mm]	$\Delta PL \pm SD$ [mm]	$\Delta cACD \pm SD$ [mm]
-0.02 ± 0.08	0.08 ± 0.16†	0.00 ± 0.04	-0.05 ± 0.13	0.07 ± 0.08†

Figure 3. The AcrySof CACHET IOL maintained its position over 3 years (measured at 1-3 to 24-36 months postoperatively; n=22).<sup>3</sup>

Analysis showed little change in pupillary diameter and anterior chamber depth with accommodation (Figure 4). There was a slight forward movement of the IOL, although this occurred less in older patients. Looking at the movement of the AcrySof CACHET IOL over time, the distance from the endothelium to the phakic lens and the distance from the phakic IOL to the crystalline lens measurements showed less than 0.1 mm of change. There was some decrease in the defocus curve for the pupil's diameter, which typically changes during accommodation. We also found a slight change in the anterior chamber depths, but these numbers are quite small: 3.3 mm to start, and 3.2 mm with the defocus at -7.00 D. Again, we found a correlation between the change of these lenses in the eye according to the age and the distances for the two measurements.

An iris-fixated phakic IOL can move during accommodation. For example, Guell et al evaluated the relationship between the Verisyse (Abbot Medical Optics Inc.) and the Artiflex (Ophtec GmbH) phakic IOLs and the anterior chamber structures during accommodation.<sup>5</sup> The researchers used the Visante optical coherence tomographer (Carl Zeiss Meditec) to measure the relationship between the anterior surface of the IOL and the corneal endothelium, between the posterior surface of the phakic IOL and the anterior surface of the crystalline lens, and the pupil's diameter.

With accommodation, patients in both groups had a significant decrease in pupillary diameter and in the distance between the anterior surface of the lens and

(Continued on page 7)

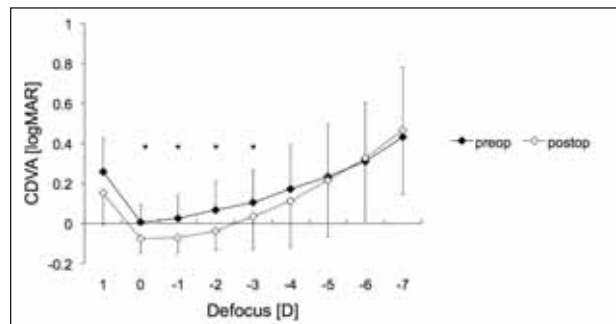


Figure 5. Even with 2.00 D of defocus, preliminary results with the AcrySof CACHET IOL showed high efficacy in corrected distance visual acuity.

# Clinical Update on the Acrysof IQ ReSTOR Toric IOL

Reducing astigmatism to improve outcomes.

BY PATRICK DESPREZ, MD

Attaining emmetropia requires spherical neutrality with the appropriate lens power and the correct biometry, cylindrical neutrality, and the centered and stable placement of the IOL within the capsular bag. Toric IOL technology has enabled surgeons to provide such visual accuracy to patients with significant amounts of corneal astigmatism who otherwise would suffer compromised acuity with standard implants. This article describes my latest clinical experience with the the AcrySof IQ ReSTOR Toric IOL (Alcon Laboratories, Inc.).

## THE IMPACT OF RESIDUAL ASTIGMATISM

Experience has taught us that to be successful with multifocal IOLs, the refractive outcome of the lens implantation should be as close as possible to emmetropia. Achieving this goal first requires precise biometry in order to calculate the correct spherical power of the IOL. To identify the eye's corneal astigmatism, surgeons must perform accurate keratometry combined with corneal topography. Then, the appropriately powered IOL must be implanted so that it is well centered and stable within the capsular bag.

Residual astigmatism of more than 0.50 D decreases visual acuity at all distances, reduces contrast sensitivity, and increases the incidence of halos and glare—all issues that compromise patients' postoperative vision and lessen their satisfaction, particularly with multifocal IOLs.<sup>1</sup> Current estimates propose that only 30% of cataract patients have less than -0.75 D of astigmatism preoperatively, which means that 70% may require additional correction for astigmatism.<sup>2</sup>

## EXPANDED TORIC IOL TREATMENT OPTIONS

Surgeons have used various methods to correct astigmatism either during or after cataract surgery. Limbal relaxing incisions (LRIs) can be useful for treating astigmatism of up to 1.50 D, although the technique can be challenging and the results inconsistent. The outcome of LRIs usually depends on several factors, including age, preoperative keratometry, peripheral pachymetry, the depth of the

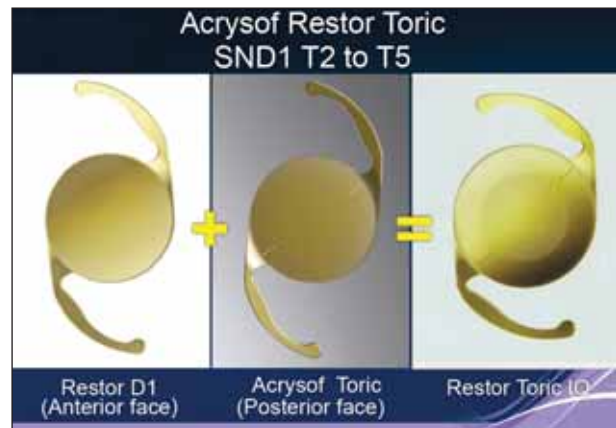


Figure 1. The AcrySof IQ ReSTOR Toric IOL contains the same aspheric, diffractive, multifocal optics as the AcrySof IQ ReSTOR IOL +3.0 D.

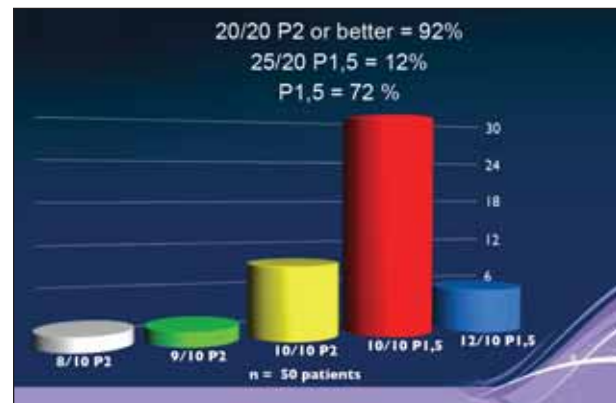


Figure 2. The majority of 50 patients implanted bilaterally with the AcrySof IQ ReSTOR Toric IOL achieved 20/20 UCVA.

incisions, and the healing response. Due to the imprecise nature of this option, many surgeons have adopted toric IOLs in recent years. Now, expanded treatment ranges and aspheric technology are making the toric option even more versatile. In Europe, for example, Advanced Technology (AT) IOLs compose just 7% of the market. It is estimated that the market for toric implants is expected to

ALCON® LENS MODELS		SN6AT3	SN6AT4	SN6AT5	SN6AT6	SN6AT7	SN6AT8	SN6AT9
Cylinder Power	IOL Plane	1.50 D	2.25 D	3.00 D	3.75 D	4.50 D	5.25 D	6.00 D
	Corneal Plane*	1.03 D	1.55 D	2.06 D	2.57 D	3.08 D	3.60 D	4.11 D
Recommended Corneal Astigmatism Correction Range		0.75 D to 1.54 D	1.55 D to 2.05 D	2.06 D to 2.56 D	2.57 D to 3.07 D	3.08 D to 3.59 D	3.60 D to 4.10 D	4.11 D and up

Figure 3. AcrySof IQ Toric IOL range of cylindrical powers (source: AcrySof IQ Toric IOL's Directions for Use).

grow 66% in 2011 vs. 2010, while the multifocal lens market is expected to grow just 25%.

**THE ACRYSOF IQ RESTOR TORIC IOL**

The AcrySof IQ ReSTOR Toric IOL (Alcon Laboratories, Inc.) is the latest innovation in the family of AcrySof ReSTOR lenses that was first introduced in 2004. This apodized, diffractive, multifocal, aspheric, toric model combines the anterior face of the multifocal AcrySof IQ ReSTOR IOL +3.0 D (model SN6AD1) and the posterior face of the well-known AcrySof Toric IOL (Figure 1; see the brief summary of the Directions for Use for the AcrySof Toric IOL on the back page). Thus, this lens is appropriate for use in astigmatic individuals who also require presbyopic correction. The aspheric optic contains 0.1 µm of negative asphericity that is designed to counteract the natural positive asphericity of the cornea, which increases with age.<sup>3</sup> The AcrySof IQ ReSTOR Toric IOL leaves the eye with approximately 0.2 µm of positive spherical aberration to improve contrast sensitivity and depth of focus.

The light energy distribution and defocus curve of the AcrySof IQ ReSTOR Toric IOL are the same as for the AcrySof IQ ReSTOR IOL +3.0 D. Patients implanted with the latter lens have reported that their most comfortable reading distance is at approximately 40 cm. In my practice, 92% of a cohort of 50 patients implanted bilaterally with

the AcrySof IQ ReSTOR Toric IOL demonstrated 20/20 or better (P2) UCVA (Figure 2).

Like the original AcrySof Toric IOL, the IQ ReSTOR Toric is made of a proprietary hydrophobic acrylic material, and I find it to be exceptionally stable inside the eye. In clinical trials, the lens demonstrated a mean rotation of less than 4° at 6 months

postoperatively. Thus, there is no risk of regression, as with LRLs. The lens is available in powers from +1.00 to +3.00 D at the IOL plane to correct from 0.50 to 2.00 D of astigmatism (Figure 3). This range of power enables surgeons to correct up to 90% of the preoperative astigmatism seen clinically. For assistance with IOL calculations, surgeons may access the easy-to-use AcrySof IQ ReSTOR Toric IOL Calculator (<http://www.acrysoftoriccalculator.com/>).

**IMPLANTATION**

When implanting the AcrySof IQ ReSTOR Toric IOL, accurate biometry and keratometry are critical. My staff and I cross-check the axis of astigmatism using both manual and automated keratometry as well as corneal topography. Toric misalignment of only 10° will leave the astigmatism undercorrected by 34%.<sup>4,5</sup> Prior to surgery, while the patient is sitting upright, I mark the horizontal axis using a Nuijts-Lane Pre-op Toric Reference Marker With Bubble (ASICO). Then, I make a 2.2-mm square incision according to the preoperative protocol. I feel that one of the most important steps is to make a 5.5-mm capsulorhexis that will overlap the optic and help stabilize it in the capsular bag. After implanting the AcrySof IQ ReSTOR Toric IOL, I make sure to remove the viscoelastic from behind the optic before I rotate the lens to its final position.

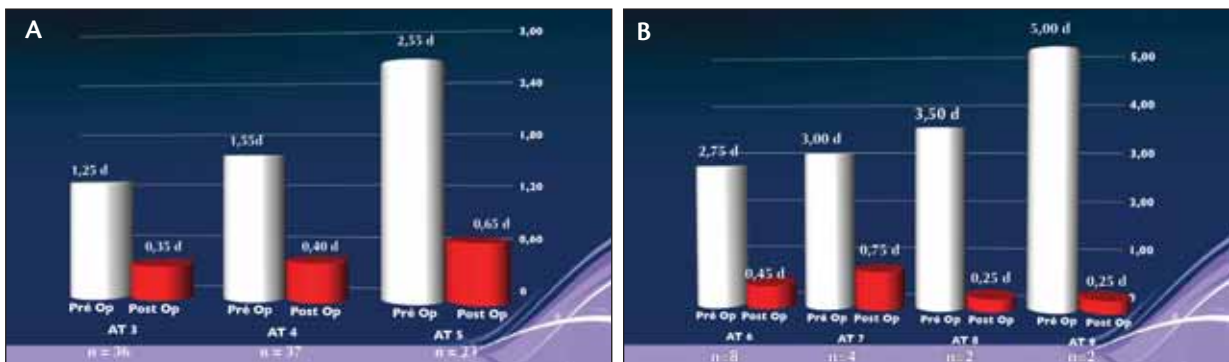


Figure 4. The percent by which the AcrySof IQ Toric lens reduced astigmatism ranged from 72% for the T3 model (A) to 95% for the T9 model (B).

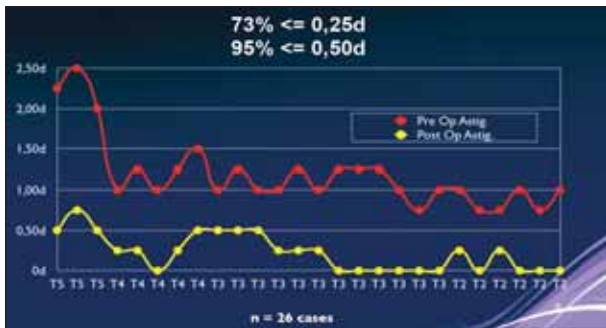

Figure 5. Early results of patients implanted with the AcrySof IQ ReSTOR Toric lens showed little residual astigmatism.

**CLINICAL EXPERIENCE**

As part of the lens' ongoing clinical trial, my staff and I tracked 112 eyes that we implanted with the AcrySof Toric IOL (models T3 to T9) to evaluate the amount of astigmatic correction they received from the lens (Figure 4A and B). The percent by which the lenses reduced astigmatism ranged from 72% for the T3 model to 95% for the T9 model, which suggests that a greater amount of correction produced a better result. Likewise, initial outcomes of 26 eyes we implanted with the AcrySof IQ ReSTOR Toric IOL (10 bilateral, 16 monocular) showed that 95% of patients had less than -0.50 D of residual astigmatism, and 73% of patients had less than -0.25 D (Figure 5).

Finally, there is evidence that the hydrophobic acrylic material of the AcrySof ReSTOR IOLs may provide some protection against posterior capsular opacification. In 2010, Gauthier et al compared the 2-year rate of Nd:YAG capsulotomies between the AcrySof ReSTOR IOLs and the AcriLISA IOLs (Acritec GmbH). At 24 months, the rate of Nd:YAG capsulotomies was 8.8% in the AcrySof ReSTOR group (n=80) and 37.2% in the AcriLISA group (n=76).<sup>6</sup>

Patrick Desprez, MD, practices at the Clinique Saint George in Nice, France. He is a consultant to Alcon Laboratories, Inc. Dr. Desprez may be reached at tel: +33 4 93 44 84 29; e-mail: patrickdesprez@me.com.



All trademarks are the properties of their respective owners.

1. Hayashi K, Manabe S, Yoshida M, Hayashi H. Effect of astigmatism on visual acuity in eyes with a diffractive multifocal intraocular lens. *J Cataract Refract Surg*. 2010;36(8):1323-1329.
2. Ferrer-Blasco T, Montés-Micó R, Peixoto-de-Matos SC, et al. Prevalence of corneal astigmatism before cataract surgery. *J Cataract Refract Surg*. 2009;Jan;35(1):70-5.
3. Wang L, Dai E, Koch DD, Nathoo A. Optical aberrations of the human anterior cornea. *J Cataract Refract Surg*. 2003;29(8):1514-1521.
4. Shimizu K, Misawa A, Suzuki Y. Toric intraocular lenses: correcting astigmatism while controlling axis shift. *J Cataract Refract Surg*. 1994;20(5):523-525.
5. Ma JJ, Tseng SS. Simple method for accurate alignment in toric phakic and aphakic intraocular lens implantation. *J Cataract Refract Surg*. 2008;34:1631-1636.
6. Gauthier L, Lafuma A, Laurendeau C, Berdeaux G, Neodymium:YAG laser rates after bilateral implantation of hydrophobic and hydrophilic multifocal intraocular lenses: twenty-four month retrospective comparative study. *J Cataract Refract Surg*. 2010;36(7):1195-1200.

(Continued from page 4)

the corneal endothelium. There were no statistically significant changes in the distance between the posterior surface of either IOL and the anterior surface of the crystalline lens. Also, there were no statistically significant differences between the two phakic IOLs in any measurement.

**CONCLUSIONS**

The AcrySof CACHET IOL showed high efficacy in corrected distance visual acuity, even with the 2.00 D defocus (Figure 5). With no negative impact on visual acuity, this lens remains a good option for older patients. Defocus curves were very similar pre- versus postoperatively, demonstrating that the lens does not interfere with accommodation. It is worth noting that the patients in these studies showed a better UCVA postoperatively with the AcrySof CACHET IOL than their preoperative BCVA with glasses, although this effect is common in myopic patients. The AcrySof CACHET IOL provides stable lens position in the anterior chamber. My colleagues and I believe this is true during accommodation as well, and the lens' movement during accommodation decreases with age. For overall stability of the AcrySof CACHET IOL, I use a two-thirds rule: that the distance of the lens to the endothelium is two-thirds of the depth of the anterior chamber. In other words, the distance from the lens to the cornea is twice the distance from the implant to the crystalline lens. ■

Thomas Kohnen, MD, PhD, FEBO, is a Professor of Ophthalmology and the Deputy Chairman at the Department of Ophthalmology, Goethe-University Clinic, Frankfurt, Germany, and Visiting Professor at the Baylor College of Medicine, Houston, Texas.



Professor Kohnen is a member of the CRST Europe Editorial Board. He is a consultant for and has received grant support from Alcon Laboratories, Inc. Prof. Kohnen may be reached at tel: +49 69 6301 3945; e-mail: kohnen@em.uni-frankfurt.de. All trademarks are the properties of their respective owners.

1. Güell JL, Morral M, Kook D, Kohnen T. Phakic intraocular lenses part 1: historical overview, current models, selection criteria, and surgical techniques. *J Cataract Refract Surg*. 2010;36(11):1976-1993.
2. Kohnen T, Kook D, Morral M, Güell JL. Phakic intraocular lenses: part 2: results and complications. *J Cataract Refract Surg*. 2010;36(12):2168-2194.
3. Kohnen T, Klapproth OK. Three-year stability of an angle-supported foldable hydrophobic acrylic phakic intraocular lens evaluated by Scheimpflug photography. *J Cataract Refract Surg*. 2010;36(7):1120-1126.
4. Baumeister M, Bühren J, Kohnen T. Position of angle-supported, iris-fixed, and ciliary sulcus-implanted myopic phakic intraocular lenses evaluated by Scheimpflug photography. *Am J Ophthalmol*. 2004;138(5):723-731.
5. Güell JL, Morral M, Gris O, et al. Evaluation of Verisyse and Artiflex phakic intraocular lenses during accommodation using Visante optical coherence tomography. *J Cataract Refract Surg*. 2007;33(8):1398-1404.

# Clinical Experience With the AcrySof Toric IOL

A 2-year review shows improved UCVA after implantation.

BY A. JOHN KANELLOPOULOS, MD

I have years of experience implanting toric IOLs, and to date, these lenses represent approximately 30% of my routine cataract practice. Toric IOLs have time-tested nomograms, and they have the potential to make astigmatic patients very happy. Recently, my staff and I attempted to evaluate the safety, efficacy, and clinical parameters of our use of the AcrySof Toric IOL (Alcon Laboratories, Inc.) in our routine cataract surgery protocol.

## TREATMENT OPTIONS

We surgeons have several ways to treat astigmatism after cataract surgery: corneal incisions, limbal relaxing incisions (LRIs), astigmatic keratotomy, postoperative bioptics with excimer treatments (PRK and LASIK), and toric IOLs. I prefer not to treat surgically induced astigmatism with corneal incisions; I feel there are much more elegant and stable methods available, such as toric IOLs. The astigmatic outcome with these lenses is quite predictable when we carefully evaluate the cornea preoperatively (via keratometry, topography, and tomographic imaging), and especially when we can confidently predict our amount of induced astigmatism from the cataract procedure. Therefore, including the calculated residual cylinder within the IOL to be implanted becomes a very attractive alternative.

I have had great success with implanting the AcrySof Toric IOL in recent years, which I believe is due to the lens' strong, time-tested nomogram compared with other brands, in my clinical experience. Moreover, the AcrySof Toric IOL's online calculator ([www.acrysoftoriccalculator.com](http://www.acrysoftoriccalculator.com)) makes it very easy to choose the appropriate lens for the patient I am treating. (See the brief summary of the Directions for Use for the AcrySof Toric IOL on the back page.)

## CLINICAL REVIEW

My staff and I reviewed the outcomes of 115 eyes of 78 consecutive patients implanted with the AcrySof Toric IOL over 2 years.<sup>1</sup> We prospectively evaluated the eyes' preoperative and 6-month postoperative data for age, UCVA, BSCVA, refraction, cylinder, change in topographic cylinder, endothelial cell count, degrees of planned-to-

**TABLE 1. MEAN RESULTS OF 115 EYES IMPLANTED WITH THE ACRYSOFTORIC IOL**

Mean age:	67 years
Mean UCVA (pre- to postoperatively):	20/100 to 20/25
Mean BSCVA (pre- to postoperatively):	20/40 to 20/22
Mean reduction in spherical equivalent:	from 4.20 to 0.50 D
Mean postoperative cylinder:	-2.75D to -0.55 D
Mean topographic cylinder change:	-0.45 D
Mean endothelium cell count (pre- to postoperatively):	1,850 to 1,650
Mean degrees of planned-to-achieved axis deviation:	5°

achieved IOL axis deviation, and possible complications. In this case series, we saw a significant improvement in patients' postoperative BCVA and UCVA. Table 1 shows the results of the series.

We encountered no serious complications in this small group. Two eyes required repositioning of the IOL due to an axis deviation of more than 30°. I recognize that correcting corneal astigmatism at the lenticular level may be counterintuitive, but in cataract patients, it works. Because cataract surgical patients tend to have small pupils, a small effective optical zone on the IOL's optic is sufficient. We concluded that the AcrySof Toric IOL appears to be safe and effective in achieving emmetropia in routine cataract surgery (see the list of conditions contraindicated for a toric IOL in the AcrySof Toric IOL's DFU [<http://www.alconsurgical.com/pdfs/TOR240.pdf>]). Furthermore, the lens is simple in design, and I feel it is minimally invasive compared to other alternatives mentioned previously.

Again, my staff and I have found the AcrySof Toric IOL to be a tremendous tool for happy patients. This positive experience has led us to also work with the AcrySof ReSTOR IQ Toric IOL, with which we have achieved similar success in managing preoperative astigmatism.



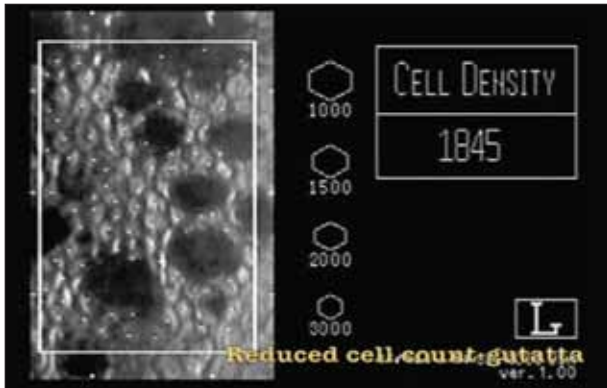


Figure 1. Reduced endothelial cell count caused by the corneal guttata.

**CASE STUDY**

The following case illustrates how the AcrySof Toric IOL can benefit patients with challenging presentations. A 67-year-old white female presented to my office with corneal guttata, pseudoexfoliation, and Fuch's endothelial dystrophy in the left eye (Figure 1). She also had bilateral cataracts. I requested that she return the next morning, and her cornea was 50 µm thicker. I planned to perform a corneal graft after cataract surgery with implantation of an AcrySof Toric IOL.

Needless to say, calculating the toric IOL's axis alignment was more challenging in this eye than in most. I used a technique that involves taking a picture of the eye at the slit lamp and bringing the picture into the OR. The slit lamp's light represents the eye's steep axis (Figure 2). During surgery, I oriented the steep axis marker on the cornea with the limbal anatomy and scleral vessels on the photo and in vivo.

I proceeded cautiously with the cataract surgery using the Constellation Vision System (Alcon Laboratories, Inc.) (a video of the surgery is available at <http://www.youtube.com/watch?v=D5nvCmBW9B8>). The surgery was greatly assisted by the ophthalmic viscosurgical device VISCOAT (Alcon Laboratories, Inc.). I discovered VISCOAT OVD later in my career, but I like this viscoelastic. It may take a little longer to remove from the eye at the end of a case, but it readily adheres to the intraocular structures and allows the surgeon to perform surgical maneuvers as necessary. I used four tubes of VISCOAT OVD to make sure I protected the corneal endothelium while I removed the cataract from this eye (see the brief summary of the Directions for Use for VISCOAT OVD on the back page). The surgery was a little challenging, but it proceeded without complication, thanks to this OVD.

When it was time to remove the cortex, the eye's pseudoexfoliation had exposed some of the posterior capsule, so I

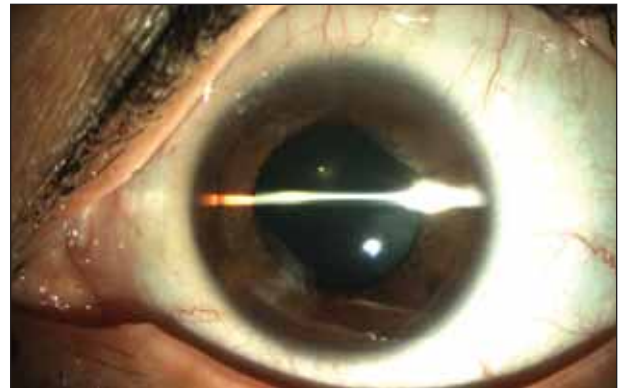


Figure 2. A slit-lamp image of an eye with the light indicating the axis between 3- and 9-o'clock.

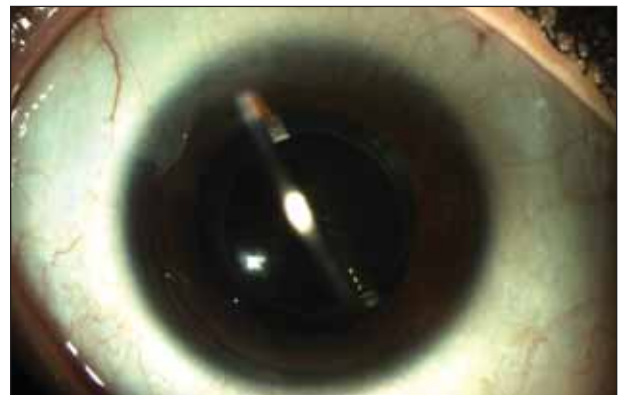

Figure 3. The eye on the first postoperative day with the AcrySof Toric IOL implanted.

inserted a 13-mm capsular tension ring (Ophtec BV) for additional support. Because the pupil was small, I took extra time when implanting the AcrySof Toric IOL to locate the alignment marks on the lens using the Intra-Op axis marker by ASICO LLC (AE-2792). This patient had a very good postoperative result of 20/25 UCVA (Figure 3). ■

*A. John Kanellopoulos, MD, is the Medical Director of Laservision Eye Institute, Athens, Greece, and a Clinical Professor of Ophthalmology at New York University Medical School. He states that he is a WaveLight Ambassador and a consultant to Alcon Laboratories, Inc. In 2011, he received the Lans Distinguished Award from the ISRS/AAO, and he is a member of the CRST Europe Editorial Board. Dr. Kanellopoulos may be reached at tel: +30 210 747 2777; e-mail: [ajk@brilliantvision.com](mailto:ajk@brilliantvision.com).*



*All trademarks are the properties of their respective owners.*

1. Kanellopoulos AJ. Evaluation of toric IOL implantation (AcrySof Toric) in cataract surgery. Poster presented at: The XXVIII Congress of the ESCRS, September 4-8 2010; Paris, France.

# IOL Calculations After Refractive Surgery

Methodologies and considerations.

BY WARREN E. HILL, MD

Since the introduction of radial keratotomy more than 30 years ago, we can conservatively estimate that more than 40 million people worldwide have undergone some form of keratorefractive surgery. According to Market Scope LLC (St. Louis, MO), more than 8.5 million people (15 million eyes) in the United States alone have undergone laser-based refractive surgery.<sup>1</sup> As these patients age and develop cataracts, they will seek a similar patient-centric surgical experience for cataract surgery.

Anyone who routinely performs IOL-based surgery after refractive surgery is well aware that these individuals are highly invested in a specific refractive outcome. However, the same procedure that allowed for a decrease in spectacle dependence leads to certain technological limitations. All forms of refractive surgery complicate surgeons' ability to accurately measure the central corneal power using standard techniques. Add to this challenge the possibility of increased higher-order aberrations for eyes that have undergone laser refractive surgery, which may limit available IOL options, along with the fact that unmodified theoretical formulas are ill suited to the correct estimation of the effective lens position for this patient population, and there is the potential for this patient population to turn into something of a refractive tsunami that will soon wash over ophthalmology.

## RADIAL KERATOTOMY

To estimate the central corneal power following radial keratotomy (RK), years of experience have shown that the average of the 1-mm through 4-mm annular power values from the Numerical View of models 995, 994, and 993 of the Atlas topographer (Carl Zeiss Meditec), or the average of the 1-mm through 4-mm ring values of the model 9000 Atlas topographer generally gives good results (Figure 1).<sup>2</sup> This is also the methodology employed by the ASCRS online postkeratorefractive surgery IOL power calculator (<http://iol.ascrs.org/>), which I highly recommend. Unpublished data suggest that the Power Distribution feature of the Pentacam

“There is the potential for [the postrefractive surgery] patient population to turn into something of a refractive tsunami that will soon wash over ophthalmology.”

Comprehensive Eye Scanner (Oculus Optikgeräte GmbH) at a 5.0-mm zone centered on the pupil may also work well for eyes that have undergone prior RK (Figure 2). However, all estimation techniques are generally less accurate when a post-RK cornea is significantly multifocal, or when there is a strong demarcation between the steep and flat areas near the pupillary center.

The combination of progressive corneal flattening (hyperopic drift) combined with small or large amounts of lenticular myopia may mask an eye's true refractive corneal power when we attempt to estimate this by historical methods. For this reason, methods based on clinical history may not be useful following RK. Accumulated experience has shown that the contact lens method lacks consistent accuracy, even with a reverse-geometry rigid gas permeable lens.

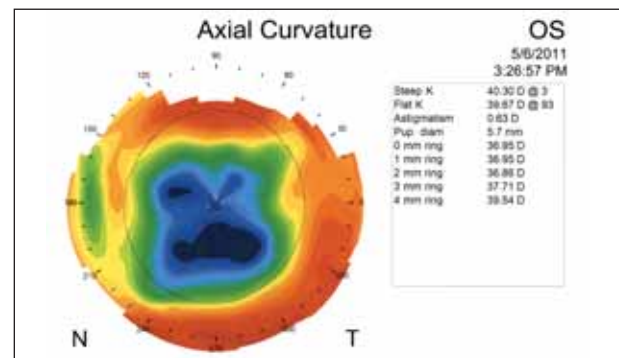


Figure 1. Prior RK with the Atlas 9000 topographer's ring values used to estimate the central corneal power.

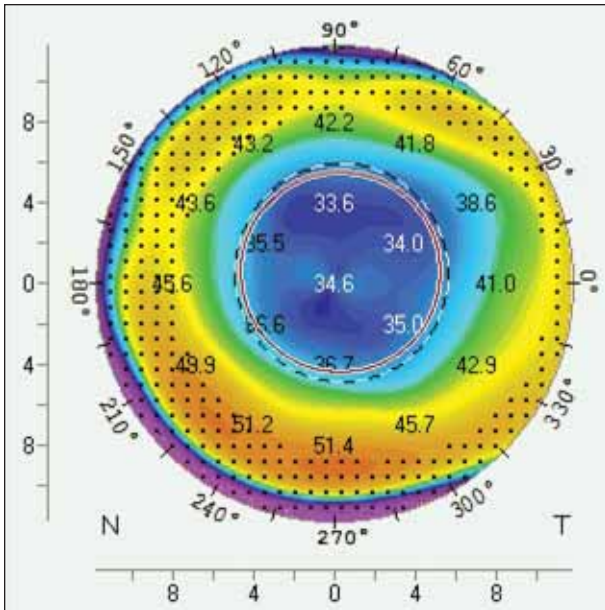


Figure 2. A 5-mm corneal Power Distribution zone taken with the Oculus Pentacam after an RK procedure that was centered on the pupil.

We cannot successfully carry out IOL power calculations following RK using routine corneal power measurement methods and an uncorrected or unmodified third-generation, theoretic two-variable formula. Instead, it is necessary to combine the correctly estimated corneal power with either a formula that is not impacted by the artifact of flat central Ks, such as Haigis, or a corrected version of one of the other formulas (the Aramberri double-K method corrects the Hoffer Q, Holladay 1, and SRK/T formulas; the internal double K method corrects the Holladay 2 formula<sup>3</sup>). The ASCRS online postkeratorefractive surgery IOL power calculator uses an Aramberri double-K specially modified version of the Holladay 1 formula.

Because hyperopic drift following RK may persist for decades, surgeons generally target refractive outcomes for somewhere between -0.50 and -0.75 D. There are two reasons for this: (1) unanticipated hyperopic errors are common, and (2) it is more desirable to have the patient shifting, over time, toward better vision (plano) than away from their visual goals. Hard plano should never be the refractive target after RK.

If the final refractive objective remains elusive following cataract surgery with

OD (right)		
K1: 46.42 D @ 57°		7.27 mm
K2: 47.14 D @ 147°		7.16 mm
ΔD: +0.72 D @ 147°		
K1: 46.42 D @ 53°		7.27 mm
K2: 47.14 D @ 143°		7.16 mm
ΔD: +0.72 D @ 143°		
K1: 46.42 D @ 42°		7.27 mm
K2: 47.14 D @ 132°		7.16 mm
ΔD: +0.72 D @ 132°		
n: 1.3375		

Figure 3. The IOLMaster's 2.5-mm small-zone autokeratometry is one of several options for the ASCRS online postkeratorefractive surgery calculator.

prior RK in spite of our best efforts, we should not make plans to perform an IOL exchange or implant a secondary piggyback IOL until the postoperative refractive outcome is stable. It is generally required that at least 2 months have passed and two refractions are stable at two consecutive visits at approximately the same time of the day (sometimes referred to as the *post-RK rule of 2s*).

### MYOPIC LASIK

Estimating an eye's central corneal power after myopic LASIK is less straightforward. There are a wide variety of methods that involve historical changes, autokeratometry correction algorithms, and the adjustment of topographic data (Figure 4). The Masket<sup>4</sup> and modified Masket<sup>5</sup> methods use small-zone autokeratometry and a linear correction algorithm that adjusts the measured central corneal power based on the amount of prior refractive surgery. These are some of the more accurate

IOL Powers Calculated Using Double-K Holladay 1 Formula Except Haigis-L		
Using Pre-LASIK/PRK Ks + ΔMR	Using ΔMR	Using no prior data
Clinical History 19.34	Adjusted EFRP 18.68	Wino-Koch-Maloney 18.77
Feiz-Macnis 19.66	Adjusted Atlas D-3 19.12	Sharmas Method 18.65
Corneal Bypass 19.51	Masket Formula 18.42	Haigis-L 18.90
	Modified-Masket 19.14	Gallie 18.77
	Adjusted ACCP 18.49	
	Average IOL Power: 18.95	
	Min: 18.42	
	Max: 19.66	

Figure 4. Example of a post-myopic LASIK IOL power calculation using the ASCRS online postkeratorefractive surgery calculator.

methods. Once considered the gold standard, purely historical methods of corneal power calculations following myopic LASIK appear to have the lowest overall accuracy.

Unfortunately, it is an increasingly common occurrence for patients to no longer have access to their refractive surgery records. When this is the case, the Shammass<sup>6</sup> and Haigis-L<sup>7</sup> methods can be very useful. Both make adjustments to the measured central corneal power, and both formulas are free of the calculation artifact that typically occurs with theoretical formulas in the setting of very flat or very steep corneal power values.

### HYPEROPIC LASIK

The estimation of central corneal power following hyperopic LASIK may also involve historical changes, autokeratometry correction algorithms, and the adjustment of topographic data. In general, the calculation accuracy following hyperopic LASIK is somewhat better than myopic LASIK. These patients typically undergo smaller amounts of refractive correction, and the measurement error by small-zone autokeratometry is relatively small when compared to myopic LASIK. However, treatment regression combined with lens-induced myopia may render historical methods inaccurate.<sup>8</sup> As with myopic LASIK, the Masket, modified Masket, and Haigis-L formulas give good overall results. The Haigis-L formula is very useful when there are no prior refractive surgery data for review.

### IOLs

Because the primary feature of refractive surgery is to change the central corneal power, the naturally occurring positive spherical aberration of the cornea may increase (as with RK and myopic LASIK), decrease, or shift negatively (as with hyperopic LASIK).<sup>9</sup> We must keep this effect in mind when selecting an IOL, so that the IOL does not accentuate the change in spherical aberration produced by refractive surgery and further reduce the patient's contrast sensitivity.

Eyes that have undergone prior RK or myopic LASIK generally see better with an aspheric IOL that adds negative spherical aberration (eg, the AcrySof IQ ReSTOR IOL [Alcon Laboratories Inc.] or the Tecnis aspheric IOLs [Abbott Medical Optics Inc.]). Eyes that have had prior hyperopic LASIK see well with spherical-aberration-neutral IOLs (such as the SofPort Advanced Optics Aspheric Lens System [LI61AO; Bausch + Lomb]), or spherical IOLs in the presence of large amounts of hyperopic correction. Ideally, the anterior corneal spherical aberration should be measured as part of this decision-making process.

In eyes that have had refractive surgery, we should only cautiously consider implanting toric IOLs when an anterior corneal topographic power map demonstrates regular astigmatism. In the same manner, we should not place multifocal IOLs in eyes with irregular astigmatism, or in the setting of obviously multifocal corneas with elevated higher-order aberrations, especially spherical aberration and coma. Doing so is likely to degrade visual function due to a loss of contrast sensitivity.

### THE ASCRS CALCULATOR

In 2007, the American Society of Cataract and Refractive Surgery made available a free online calculator for the postkeratorefractive eye (available at [www.ascrs.org](http://www.ascrs.org)). This calculator will perform IOL power calculations for eyes that have undergone previous myopic LASIK, hyperopic LASIK, and RK, provided it is given the correct information. Most of the methods listed above can be carried out using the ASCRS calculator.<sup>10</sup>

The calculation methodologies employed by the ASCRS online calculator have been gathered together from the literature and are updated on a regular basis as new, more accurate approaches to this problem appear. This calculator has also been added to the Web site of the American Academy of Ophthalmology and may be accessed at [www.aaopt.org/ce/iol.html](http://www.aaopt.org/ce/iol.html).

I highly recommend the ASCRS online calculator for any surgeon working with these challenging cases. ■

Warren E. Hill, MD, is in private practice at East Valley Ophthalmology in Mesa, Arizona. He is a consultant for Alcon Laboratories, Inc. Dr. Hill may be reached at (480) 981-6130; [hill@doctor-hill.com](mailto:hill@doctor-hill.com).



All trademarks are the properties of their respective owners.

1. MarketScope. The 2003 comprehensive report on the single use cataract device market. St. Louis, MO: MarketScope, LLC; 2003:14.
2. Eyes with prior radial keratotomy. [www.doctor-hill.com/iol-main/postRK.htm](http://www.doctor-hill.com/iol-main/postRK.htm). Accessed on July 31, 2011.
3. Fang JP, Hill WE, Wang L, et al. Advanced Intraocular Lens Power Calculations. Kohnen and Koch (ed), In: *Essentials in Ophthalmology - Cataract and Refractive Surgery*. Springer-Verlag, Berlin, 2007.
4. Masket S, Masket SE. Simple regression formula for intraocular lens power adjustment in eyes requiring cataract surgery after excimer laser photoablation. *J Cataract Refract Surg*. 2006;32(3):430-434.
5. Hill WE. IOL power calculations following keratorefractive surgery: a modification of the Masket regression formula. Paper presented at the ASCRS Annual Symposium; San Francisco, CA; March 17, 2006.
6. Shammass HJ, Shammass MC. No-history method of intraocular lens power calculation for cataract surgery after myopic laser in situ keratomileusis. *J Cataract Refract Surg*. 2007;33:31-36.
7. Haigis W. Intraocular lens calculation after refractive surgery for myopia: Haigis-L formula. *J Cataract Refract Surg*. 2008;34(10):1658-1663.
8. Wang L, Jackson W, Koch DD. Methods of estimating corneal refractive power after hyperopic laser in situ keratomileusis. *J Cataract Refract Surg*. 2002;28:954-996.
9. Hamza I, Aly MG, Hashem KA. Multifocal IOL dissatisfaction in patients with high coma aberrations. Presented at: The ASCRS Annual Symposium; March 27, 2011; San Diego, CA.
10. Wang L, Hill WE, Koch DD. Evaluation of IOL power prediction methods using the ASCRS post-keratorefractive IOL power calculator. *J Cataract Refract Surg*. 2010;36:1466-1473.

# Ensuring Patient Satisfaction With Multifocal Implants

Strategies to optimize clinical outcomes for multifocal IOL recipients.

BY ARTHUR B. CUMMINGS, MB CHB, FCS(SA), MMed(OPHTH), FRCS(Edin)

**T**he clinical outcomes of multifocal IOLs vary from patient to patient. In my experience, dissatisfaction with these implants most often is the result of ocular surface issues and the disparity in vision after having only one eye implanted. In this article, I will share a case study and then discuss some recent literature about implanting multifocal IOLs.

## CASE STUDY

A 54-year-old female presented to my office with fairly poor uncorrected vision. Her refraction was +2.00 D in each eye with a little bit of astigmatism. Her BCVA was 20/20, but she wanted to be free of spectacles. I always give my patients a monovision trial first, but this patient did not like monovision. Next, as I routinely do for multifocal IOL candidates, I asked her to trial a multifocal contact lens in each eye. To simulate what the AcrySof IQ ReSTOR IOL +3.0 D lens (Alcon Laboratories, Inc.) would do for the patient, I would put a high-add contact lens in both eyes. This patient preferred the trial with the multifocal contact lens to monovision. Her eyes were a little dry despite preoperative tear management, which is common among the presbyopic age group.

After the contact lens trial was concluded satisfactorily (the patient liked the outcome), I implanted the AcrySof IQ ReSTOR IOL +3.0 D bilaterally in this patient (a week apart) in March of 2010. Her postoperative result was satisfactory to both of us: she was 6/6 unaided binocularly, and her acuity was even better with a simple refractive correction.

Approximately 12 months postoperatively, the patient complained that her vision had worsened at both distance and near. Her unaided visual acuity had dropped to 6/12 and 6/10 respectively, and her reading vision was N8. Upon slit-lamp examination, I found that she had posterior capsular opacification (PCO) bilaterally. As we know, the smallest amount of PCO can impact the quality of vision in multifocal IOL patients. I decided to use an Nd:YAG laser on both eyes, and her vision returned to 6/6 in the left eye and 6/7.5 in the right eye. Her reading vision was 6/6+. Her post-YAG laser examination at the slit lamp looked good, but she complained that the vision in her right eye was not as

strong as in the left, and she is right-eye dominant. I asked the patient to undergo another trial with a +0.75 contact lens, which greatly improved her vision (she reported that her vision improved all around). Three months later, I performed PRK on the right eye to correct the residual +0.75 D of sphere. The patient is now 6 months out and is quite pleased with her result.

## LITERATURE AND DISCUSSION

I believe that the performance of multifocal lenses suffers from even slight imperfections in the optical system. In a study that analyzed the reasons for patient dissatisfaction after multifocal IOL implantation (n = 43 eyes of 32 patients), Woodward et al reported that 54% of eyes with blurred vision and 66% of eyes with photic phenomena had significant PCO and underwent an Nd:YAG laser capsulotomy.<sup>1</sup> This contradicts what Shimizu and Ito discussed in their article, which argued that an Nd:YAG laser capsulotomy must be delayed for as long as possible and should be a last resort, because it can make an IOL exchange more difficult.<sup>2</sup>

At the 2011 Hawaiian Eye meeting, David Chang, MD, of the University of California, San Francisco, showed that exchanging multifocal IOLs with monofocal implants resulted in better outcomes and resolved patients' subjective complaints due to decentration or tilt.<sup>3</sup> He made these clinical decisions using the iTrace (Tracey Technologies). In addition to stating that multifocal IOLs are contraindicated in eyes prone to decentration or tilt, such as those with a torn capsulorhexis or weak zonules, Dr. Chang warned against implanting these lenses in eyes with irregular corneas, such as those that have undergone previous LASIK or RK.

Jessica Chow, MD, from Duke University, believes that the most common cause for dissatisfaction after multifocal IOL implantation is residual spherical and astigmatic refractive error.<sup>4</sup> She treated 75% of IOL recipients with PRK enhancements 5 to 7 months after surgery. She applied the refractive enhancements to all eyes in which the residual sphere and cylinder were greater than 0.50 D. Thus, we must get these patients as close as possible to emmetropia.

Eric Donnenfeld, MD, has described the seven situations

**DR. DONNENFELD'S SEVEN Cs OF PATIENT DISSATISFACTION WITH MULTIFOCAL IOLs<sup>5</sup>**

1. Consecutive treatment
2. Cylinder and residual refractive error
3. Capsular opacification
4. Cystoid macular edema
5. Corneal and ocular surface disease
6. Centration of the IOL relative to the pupil
7. Circumference of the pupil relative to the IOL

(what he calls the *seven Cs*) that are typical causes of patients' dissatisfaction with their vision after multifocal IOL implantation.<sup>5</sup> It is important to look at the seven Cs before considering explantation.

My own experience largely mirrors Dr. Donnensfeld's recommendations. I certainly agree that a consecutive treatment is very important; I warn my multifocal patients that they will only be happy with their outcome once the second eye is implanted. Second, we must keep cylinder and residual refractive error under 0.50 D to make these patients happy. Capsular opacification and of course retinal conditions, especially cystoid macular edema, significantly affect patients' visual function. Also, we know that we must ensure a healthy ocular surface, because a poor-quality tear film can scatter light and interfere with the multifocal optics of these lenses. Centration of the IOL relative to the pupil is very important with multifocal implants, as is the circumference of the pupil relative to the IOL. Therefore, patients who have small or particularly immobile pupils will not experience sufficient pseudoaccommodation of the IOL.

**CONCLUSIONS**

If we adhere to meticulous surgery and appropriate patient selection, multifocal IOLs can provide patients excellent vision at the full range of viewing distances. ■

*Arthur B. Cummings, MB ChB, FCS(SA), Mmed(OPHTH), FRCS(Edin), is a consultant ophthalmologist at Wellington Eye Clinic in Dublin, Ireland. He is a consultant to Alcon Laboratories, Inc., and WaveLight GmbH. Mr. Cummings may be reached at +353 1 2930470; abc@wellingtoneyeclinic.com.*




*All trademarks are the properties of their respective owners.*

1. Woodward MA, Randleman JB, Stulting RD. Dissatisfaction after multifocal intraocular lens implantation. *J Cataract Refract Surg* 2009;35(6):992-997  
 2. Shimizu K, Ito M. Dissatisfaction after bilateral multifocal intraocular lens implantation: an electrophysiology study. *J Refract Surg* 2001;27(4):309-312.  
 3. Chang DF. Evaluating unhappy multifocal IOL patients with wavefront aberrometry. Paper presented at: The Hawaiian Eye Meeting, January 17, 2011; Maui, HI.  
 4. Krader CG. Optimizing outcomes. *Eur J Ophthalmol*. 2011;16(6):13.  
 5. Barsom A, Donnensfeld E. Bonus feature: IOL explantation: Indications and strategies for multifocal IOL explantation. *Cataract & Refractive Surgery Today Europe*. 2011;6(4):18-20.

**CLINICAL ADVANTAGES OF THE LENsX LASER**

*By Stephen G. Slade, MD*

The LenSx laser (Alcon Laboratories, Inc.) can help improve the quality of cataract surgery two ways. First, the laser lets the surgeon precisely control the capsulotomy. The human hand cannot make capsulotomies as perfectly shaped or reproducibly as a femtosecond laser. The laser also provides amazing control over the capsulotomy's centration, shape, and diameter, and it achieves the exact same configuration every time.



**Figure 1.** The surgeon can watch the LenSx laser crack the nucleus (also known as *phacofragmentation*) in real time.

The capsule's opening is very important in determining the effective lens position. For example, too small an opening will induce posterior vaulting. With the LenSx laser providing a consistent capsulorhexis, we can predict the effective lens position much more accurately. Just by switching to this device, I have reduced my standard deviation of spherical component considerably. Simply put, this laser makes lens implantation more predictable.

Second, the LenSx laser creates precise and reproducible corneal incisions, including arcuate incisions. Predictable, customizable incision construction may impact the success and safety of the cataract procedure. Furthermore, I think femtosecond laser technology is the perfect partner for phacoemulsification, because phacoemulsification will allow us to optimize our phaco machines and techniques and use less phaco power to remove the fragmented nucleus (Figure 1). ■

*Stephen G. Slade, MD, is a surgeon at Slade and Baker Vision in Houston. He is the medical director for the LenSx Laser, and he is a consultant for Alcon Laboratories, Inc. Dr. Slade may be reached at (713) 626-5544; sgs@visiontexas.com.*



# Performance of New Femto and Excimer Laser Technologies

Outcomes with the WaveLight FS200 femtosecond and WaveLight EX500 excimer lasers.

BY PREMA PADMANABHAN, MD, AND MATTHIAS MAUS, MD

The WaveLight Refractive Suite (Alcon Laboratories, Inc.) is a group of fully integrated refractive equipment—the 500-Hz WaveLight EX500 excimer laser, the WaveLight FS200 femtosecond laser, and the WaveLight diagnostic devices—that are able to communicate with one another to provide patients with what may be an unprecedented level of surgical customization. For example, the integration allows the WaveLight FS200 femtosecond laser to superimpose the design of the flap over the ablation profile the surgeon has selected on the WaveLight EX500 excimer laser. This allows the surgeon to digitally position the corneal flap while customizing the hinge position and flap shape over the area to be ablated.

This article describes recent clinical experience with the WaveLight EX500 excimer and the WaveLight FS200 femtosecond lasers.

## My First 100 Eyes With the WaveLight EX500 Excimer Laser

By Prema Padmanabhan, MD

### THE WAVELIGHT EX500 EXCIMER LASER

The WaveLight EX500—the redesigned model of the WaveLight excimer lasers (Figure 1)—is currently the fastest excimer laser available, with a 500-Hz repetition rate that translates to only 1.4 seconds per diopter of ablation. This level of speed delivers extremely consistent outcomes and reduces the potential for corneal dehydration and patients' loss of fixation.<sup>1</sup> Longer treatment times may increase the incidence of these involuntary movements and also amplify stromal dehydration, which may impact the laser's interaction with the corneal tissue. A study conducted by Mrochen et al<sup>2</sup> showed that even subclinical decentration induces higher-order aberrations, which may negatively impact patients' quality of vision.

The WaveLight EX500 laser's Gaussian beam delivers pulses at a high frequency with a low thermal output, and the ablation depth is controlled in order to preserve tissue.

The laser offers the patented Wavefront Optimized ablation profile that minimizes induced spherical aberration, as well as Wavefront-Guided, Custom-Q, Topography-Guided, and PTK treatments. The WaveLight EX500 laser has a 0.68-mm (FWHM) flying-spot beam that delivers a prolate treatment profile in a range from -14.00 to +6.00 D and up to +6.00 D




Figure 1. The WaveLight EX500 excimer and WaveLight FS200 lasers.

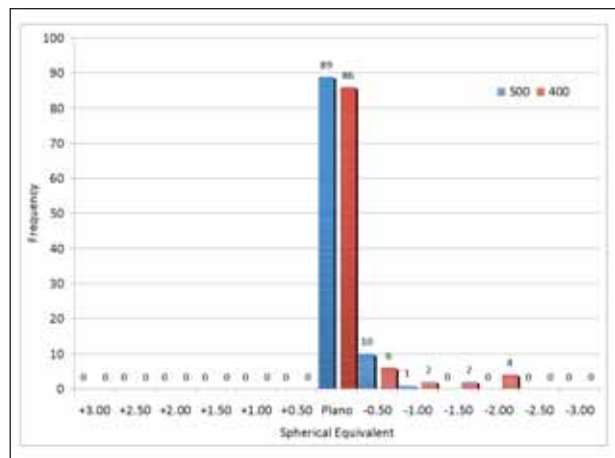


Figure 2. This graph shows the 1-day postoperative spherical equivalent of 100 eyes treated with the 500-Hz WaveLight EX500 excimer laser and 100 eyes treated with the 400-Hz ALLEGRETTO WAVE Eye-Q excimer laser.

of mixed astigmatism. The laser's PerfectPulse Technology controls the delivery of the beam and overlaps every fifth pulse to minimize the thermal effect on the cornea.

A 1,050-Hz multidimensional eye tracker (which is synchronized to the laser's 500-Hz speed) dynamically tracks pupils from 1.5 to 8.0 mm. The eye tracker is able to recognize even subtle saccadic movements of the eye and has a very short latency time of only 2 milliseconds. In addition to the eye tracker, NeuroTrack fixation lights also help prevent cyclotorsion. The WaveLight EX500 excimer laser features an active, noncontact, dynamic, optical pachymeter that monitors the stromal bed thickness before, during, and after the procedure. Before each procedure, the WaveLight EX500 performs a calibration protocol that further ensures the accuracy of the surgery.

**OUTCOMES OF FIRST 100 EYES**

My staff and I compiled the preliminary results of our first 100 Wavefront Optimized surgeries performed with the WaveLight FS200 and the WaveLight EX500 excimer laser. The refractive results were excellent. On the first postoperative day, eight of the 100 eyes had gained one line of vision, and 99% had less than 0.50 D of defocus (Figure 2). The refractions remained stable between 1 day (-0.03 D) and 1 month (-0.09 D). The attempted versus achieved corrections were very tight, with 99% falling within ±0.50 D. Furthermore, 89% of the eyes had a plano refraction, and 99% had a postoperative spherical equivalent of +0.50 D (compared with 92% treated with the 400-Hz ALLEGRETTO WAVE Eye-Q laser). The mean decentration from the ablation's center to the pupillary center was 0.26 ±0.56 mm. Also, our rate of induced corneal aberrations was comparable with our use of the 400-Hz ALLEGRETTO WAVE Eye-Q excimer laser (Alcon Laboratories, Inc.).

Similarly, Arthur Cummings, MB ChB, MMed(Ophth), FRSC(Edin), recently reported his clinic's outcomes of a large series of eyes that underwent LASIK with the 200-Hz ALLEGRETTO WAVE laser, the 400-Hz ALLEGRETTO WAVE Eye-Q laser, and the WaveLight EX500 excimer laser.<sup>3</sup> With each faster laser, fewer patients lost lines and more patients gained lines of vision (Figure 3). Without adjusting their nomogram, Dr. Cummings and his team saw a greater percentage of patients achieve within 0.50 D of their intended correction, and more patients achieved better uncorrected and best-corrected acuities compared to those rates with the slower lasers (Figure 4).

**STUDY OF ABLATION PROFILES**

In 2004, Canals et al<sup>4</sup> compared the ablation profiles of six different excimer lasers by ablating a 6-mm optical zone in a PMMA fluence plate. They observed a wide variation not only in the total ablation diameters between the different lasers (Figure 5), but also between the horizontal and vertical diameters of each laser as well as between the optical zone programmed and what was actually achieved. In contrast, each time we used the WaveLight EX500 excimer laser, the optical zone was exactly where we wanted it to be (Figure 6). Whether we performed a myopic, hyperopic, spherocylindrical, or a purely spherical correction, and no matter the diameter of the planned ablation, our achieved optical zone was always the same as what we intended, and almost perfectly circular. My team and I were also impressed with the EX500 laser's Custom Q profile in eyes with large scotopic pupils. This procedure, which allows surgeons to give the cornea an aspheric, hyperprolate shape, enabled us to create the optical zone in 0.1-mm increments. Like with the Wavefront Optimized ablations, the Custom Q ablations produced the exact size of optical zone that we programmed into the system.

(Courtesy of Arthur B. Cummings, MB, ChB)

Safety	>-2	-2	-1	0	+1	+2	>+2
<b>LASIK</b>							
200	0.3	1.3	10.1	65.8	17.8	4.4	0.3
400	0.4	1.2	8.6	70.8	15.5	2.8	0.7
500	0	1	4	65	24	5	1
<b>LASEK / ASA</b>							
200	0	0	8.6	52.7	29	9.7	0
400	0.2	2	10.3	65.6	17.8	3.4	0.8
500	0	0	5	60	35	8	2
<b>ENHANCEMENTS</b>							
200	0.4	1.7	15.1	57.6	22.3	2.5	0.4
400	0.8	2.2	18.3	61.3	15.9	2.8	0.8
500	0	0	13.3	60	20	6.7	0

Figure 3. Dr. Cummings compared LASIK outcomes between three speeds of the WaveLight excimer laser to identify lines of vision gained and lost.

(Courtesy of Arthur B. Cummings, MB, ChB)

PARAMETER	LASER	6/4	6/5	6/6	6/7.5	6/12
UCVA	200	1.3	43	63.5	77.5	87.5
	400	3.3	49.2	68.2	78.8	87.9
	500	6	50	72	88	93
BCVA	200	2.2	70	89.6	97.1	99.5
	400	3.8	75.1	91	97.1	99.3
	500	15	87	92	94	97
PREDICTABILITY ± 0.50	200 Hz	85%		83%		88%
	400 Hz	85%		83%		88%
	500 Hz	85%		83%		88%

Figure 4. Without adjusting their nomogram, Dr. Cummings and his team found better UCVA, BCVA, and predictability using the faster lasers.



**6 mm OZ ablation**  
-2.00 DS / -2.00D cyl x 90°

**Measurements of Ablated Areas in Six Excimer Lasers**

Laser	Horizontal Total Diameter (mm)	Vertical Total Diameter (mm)	Horizontal Central Diameter (mm)	Vertical Central Diameter (mm)	Central Horizontal to Vertical Diameter Ratio (%)
Bausch & Lomb	6.69	12.25	5.96	6.73	0.68
Schwind	6.96	7.25	5.14	6.18	0.83
NovaTech	8.20	8.93	5.49	7.03	0.78
LectraVision	6.60	8.98	4.38	6.12	0.72
Zenar Medtec	8.81	10.91	5.92	8.05	0.74
Vaa	7.67	8.06	5.52	5.94	0.95

Figure 5. This chart shows the measurements of ablated areas using six different excimer lasers. Each eye received a 6-mm optical zone.

My staff and I have also found the WaveLight EX500 laser's topography-guided ablations to be very useful. We frequently use this profile for our keratoconic patients in conjunction with corneal cross-linking. Figure 7 shows a keratoconic patient who underwent a topography-guided procedure before corneal cross-linking. The laser appropriately steepened the flat areas and flattened the steep areas of the cornea.

## Clinical Experience With the FS200 Femtosecond Laser

By Matthias Maus, MD

Beyond its ability to communicate with the WaveLight EX500 laser in the WaveLight Refractive Suite, the primary advantage of the WaveLight FS200 femtosecond laser is the wide range of customization it offers surgeons

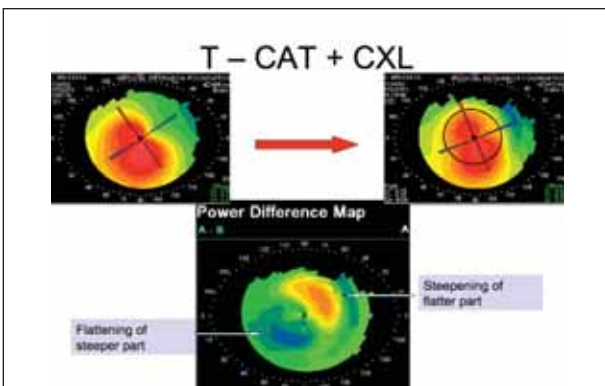


Figure 7. A keratoconic eye was treated with the WaveLight topography-guided procedure and then corneal crosslinking. The laser steepened and flattened the tissue in the appropriate places.

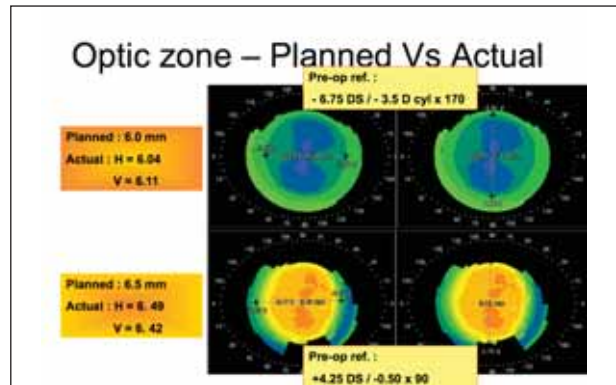


Figure 6. Planned versus achieved optical zones with the WaveLight EX500 laser.

in making corneal cuts (Figure 8). The surgeon can pre-program the shape, location, diameter, thickness, depth, and angle of corneal flaps and their hinges to accommodate the ablation profile, corneal thickness, or other considerations. Additionally, the WaveLight FS200 can make round or elliptical cuts for corneal flaps as well as side and reverse cuts for corneal segments and keratoplasties. It allows the surgeon to customize the hinge of the flap superiorly, nasally, or temporally, and he or she may angle the hinge at any position to protect corneal nerves.

The surgeon may also adjust the energy delivery, spot and line separation parameters, and depth of the WaveLight FS200 laser's beam. The laser is able to make stromal cuts as shallow as 30 µm away from Descemet's membrane or as deep as 1,000 µm, and it creates flaps with a maximum diameter of 10 mm, adjustable in 0.1-mm steps. In contrast, published data have confirmed that

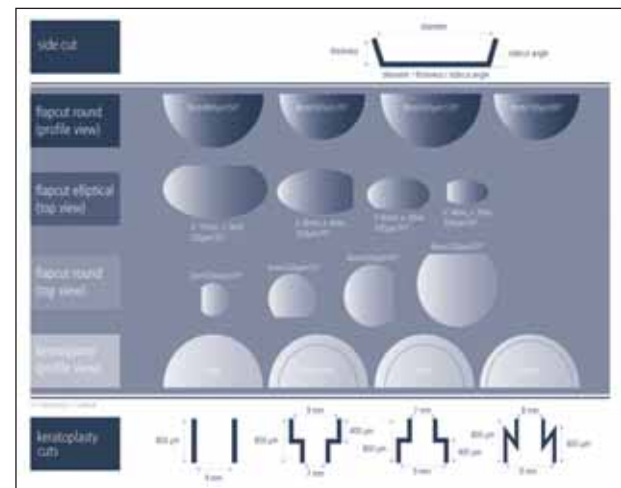


Figure 8. Possible flap and hinge cuts with the WaveLight FS200 femtosecond laser.




Figure 9. The WaveLight FS200 laser creates a tunnel that allows gas to escape.

	pre-op flat K [D]	pre-op steep K [D]	Pre-op Pachymetry [μm]	Flap-thickness [μm]
Mean	42,5	43,8	557,5	122,4
Median	42,4	43,9	557,8	121,5
Min	38,6	41,2	518,5	115,2
Max	45,4	46,7	623,5	129,5
Sd	1,6	1,6	22,8	3,8

Figure 10. The reproducible flap thickness Dr. Maus achieved in a series of 2,163 eyes.

	210 eyes	42 eyes	64 eyes	23 eyes
Intended	8,5	9,0	9,5	10
Measured	8,5	9,0	9,5	10
Min	8,5	9,0	9,5	10
Max	8,5	9,0	9,5	10
SD	0	0	0	0

Figure 11. In another series of 339 eyes treated with the FS200 laser, Dr. Maus' standard deviation in flap size was 0.

manual microkeratomes have a wide standard of deviation in flap thickness,<sup>5</sup> and an inadequate residual stromal bed diameter has been incriminated as one of the leading risk factors in iatrogenic keratoectasia.<sup>6</sup>

**SAFETY**

The WaveLight FS200 laser's beam offers two important safety features. First, it runs a calibration procedure with each ablation cone called a Beam Control Check (BCC) just before treatments to ensure precise flap thickness within a standard deviation of ±5 μm.

Second, the laser automatically cuts a tunnel through the hinge of the flap (Figure 9) in order to evacuate the gas created in the flap formation process to the corneal surface, thereby preventing opaque bubble layers (OBLs) from forming.

**APPLANATION CONE**

The WaveLight FS200 laser features a two-piece Advanced Suction Technology, which consists of a disposable suction ring and an ablation cone. The suction ring has peripheral spacers that maintains the eye's natural shape and mitigates unwanted spikes in IOP. I have not found the rise in IOP to be much of an issue, as the ring stays on the eye for less than 30 seconds while the flap is cut.

One unique feature of the WaveLight FS200 that I particularly like is the ability to change the centration of the flap within the ablation area of 12 mm, even after suction has been applied, without changing the diameter of the flap.

**PERSONAL PARAMETERS**

Prior to receiving the WaveLight Refractive Suite, the proper positioning of LASIK flaps has always been a challenge. With the WaveLight FS200, it has become quick and easy. For example, when cutting flaps to treat hyperopia, we would create 9.5-mm flaps. For simple myopia with a little astigmatism, we use an 8.5-mm flap (or 8.8 mm, if the astigmatism is greater than 2.00 D). With this machine, we are able to get the precise size and location of the flap we need and even orient the hinge to our preferences. Figures 10 and 11 show the consistency in flap thickness and size (respectively) we have achieved with the laser.

When using the WaveLight FS200 laser, my staff and I work with a relatively low energy setting of 0.65 μJ for both the bed and side cut. Our spot separation is 8 μm for each, and our line separation is 8 μm for the bed and 7 μm for the side cut.

When I first obtained this laser, I worried that it would slow down the flap-creation procedure versus using a mechanical microkeratome. Bilateral treatments with a microkeratome used to take me approximately 10 minutes; bilateral treatments with the WaveLight FS200 laser take me less than 9 minutes.

My staff and I have found the WaveLight FS200 laser to be easy to use and very reliable—we have never had to switch to using a mechanical microkeratome in any patient. At the time of this writing, we have used this workhorse laser in 2,737 eyes, and we have not encountered an eye in which it would not work. I consider it a great

tool not only for LASIK flaps, but for making intracorneal cuts and lamellar and penetrating keratoplasties as well. I feel the WaveLight FS200 has increased the precision and safety of corneal procedures. ■

**Prema Padmanabhan, MD,** is the medical director of the Medical Research



Foundation in Tamil Nadu, India. She acknowledged no financial interest in any product or company mentioned herein. Dr. Padmanabhan may be reached at phone: 00-91-44-28271616; email: drpp@snmail.org.

**Matthias J. Maus, MD,** is medical director of refractive surgery at Sehkraft in Cologne, Germany. He is a clinical consultant to Wavelight GmbH. Dr. Maus is a member of the CRSToday Europe Editorial Board. He may be reached at phone: +49 221 8601613; e-mail: maus@sehkraft.de.



All trademarks are the properties of their respective owners.

1. Drifes, microsaccades and tremors occur during fixation (Bueeler M, Mrochen M. Limitations of pupil tracking in Refractive Surgery: Systematic error in determination of corneal locations. *J Refract Surg.* 2004;20:371-378.
2. Mrochen M, Kaemmerer M, Mierdel P, Seiler T. Increased higher order optical aberrations after laser refractive surgery; a problem of subclinical decentration. *J Cataract Refract Surg.* 2001;27:362-369.
3. Cummings A. How to maximize the options of new excimer technology. Paper presented at: The Alcon User Meeting; June 18, 2011; Prague, Czech Republic.
4. Canals M, Elies D, Costa-Vila J, Coret A. Comparative study of ablation profiles of six different excimer lasers. *J Refract Surg.* 2004;20(2):106-109.
5. Zhou Y, Tian L, Wang N, Dougherty PJ. Anterior segment optical coherence tomography measurement of LASIK flaps: femtosecond laser vs microkeratome. *J Refract Surg.* 2011;27(6):408-416.
6. Randleman JB, Russell B, Ward MA, et al. Risk factors and prognosis for corneal ectasia after LASIK. *Ophthalmology.* 2003;110(2):267-275.



Putting the Future in Motion

**Indication:**

The LenSx® Laser is indicated for use in patients undergoing cataract surgery for removal of the crystalline lens. Intended uses in cataract surgery include anterior capsulotomy, phacofragmentation, and the creation of single plane and multi-plane arc cuts/incisions in the cornea, each of which may be performed either individually or consecutively during the same procedure.

**Caution:**

United States Federal Law restricts this device to sale and use by or on the order of a physician or licensed eye care practitioner. United States Federal Law restricts the use of this device to practitioners who have been trained in the operation of this device.

**Restrictions:**

- This device is not intended for use in pediatric surgery.
- Patients must be able to lie flat and motionless in a supine position.
- Patient must be able to understand and give an informed consent.
- Patients must be able to tolerate local or topical anesthesia.
- Patients with elevated IOP should use topical steroids only under close medical supervision.

**Contraindications:**

- Corneal disease that precludes applanation of the cornea or transmission of laser light at 1030 nm wavelength
- Descemetocoele with impending corneal rupture
- Presence of blood or other material in the anterior chamber
- Poorly dilating pupil, such that the iris is not peripheral to the intended diameter for the capsulotomy
- Conditions which would cause inadequate clearance between the intended capsulotomy depth and the endothelium (applicable to capsulotomy only)
- Previous corneal incisions that might provide a potential space into which the gas produced by the procedure can escape

- Corneal thickness requirements that are beyond the range of the system
- Corneal opacity that would interfere with the laser beam
- Hypotony, glaucoma, or the presence of a corneal implant
- Residual, recurrent, active ocular or eyelid disease, including any corneal abnormality (for example, recurrent corneal erosion, severe basement membrane disease)
- This device is not intended for use in pediatric surgery.

**Attention:**

Reference the Directions for Use labeling for a complete listing of indications, warnings and precautions.

**Warnings:**

The LenSx® Laser System should only be operated by a physician trained in its use.

The LenSx® Laser delivery system employs one sterile disposable LenSx® Laser Patient Interface consisting of an applanation lens and suction ring. The Patient Interface is intended for single use only. The disposables used in conjunction with ALCON® instrument products constitute a complete surgical system. Use of disposables other than those manufactured by Alcon may affect system performance and create potential hazards.

The physician should base patient selection criteria on professional experience, published literature, and educational courses. Adult patients should be scheduled to undergo cataract extraction.

**Precautions:**

- Do not use cell phones or pagers of any kind in the same room as the LenSx® Laser.
- Discard used Patient Interfaces as medical waste.

**AEs/Complications:**

- Capsulotomy, phacofragmentation, or cut or incision decentration
- Incomplete or interrupted capsulotomy, fragmentation, or corneal incision procedure
- Capsular tear
- Corneal abrasion or defect
- Pain
- Infection
- Bleeding
- Damage to intraocular structures
- Anterior chamber fluid leakage, anterior chamber collapse
- Elevated pressure to the eye



© 2011 Novartis 9/11 LSX11500PI

## Wavelight® EX500 Excimer Laser

Not available in the United States. International Only.

The information and materials within these sections do not pertain to the US market. Not all products are approved in every market, and approved labeling and instructions may vary by local country.

## AcrySof® Cachet™ Phakic Angle Supported IOL

Not available in the United States. International Only.

The information and materials within these sections do not pertain to the US market. Not all products are approved in every market, and approved labeling and instructions may vary by local country.

**CAUTION:** Federal law restricts this device to sale by or on the order of a physician.

**DESCRIPTION:** The AcrySof® Phakic Angle Supported Anterior Chamber Intraocular Lens (IOL) is intended for the reduction or elimination of moderate to high myopia in adult patients 21 years of age or older having an anterior chamber depth > 3.2 mm (measured including corneal thickness). The IOL is surgically positioned in the angle (iris/cornea junction) of the anterior chamber of the phakic eye in order to provide refractive correction. No supplemental fixation or enclavation is required.

**WARNINGS:** Patients with significant preoperative astigmatism (determined by keratometry) or expected postoperative astigmatism > 2.0 D may not achieve optimal visual outcomes. The patient's central and peripheral endothelial cell density (ECD) should be monitored periodically (at least annually) since the long term effects of this lens on the corneal endothelium have not been established. If elevated rates of loss in ECD are observed, the patient should be informed and more frequent monitoring is recommended. Elevated rates of cell loss over time or sudden, dramatic increases in cell loss may require the IOL to be explanted.

**PRECAUTIONS:** Careful and detailed preoperative evaluation and sound clinical judgment should be used by the surgeon to decide the risk/benefit ratio before implanting a lens in a patient with any of the conditions described in the Directions for Use labeling. The patient must be informed of these risks and benefits as well as precautionary measures to be taken to ensure optimal outcomes (e.g., importance of having exams at least annually, avoidance of eye rubbing, etc.). The safety and effectiveness of this lens have not been substantiated in patients with pre-existing ocular conditions and/or intraoperative complications which may include, but are not limited to, those having: stable manifest refractions of less than 1 year, cataract formation, significant irregular corneal aberration, retinal conditions, Amblyopia, clinically severe corneal dystrophy, irregular anterior chamber anatomy, anterior or posterior segment inflammation, Aniridia, iris neovascularization, glaucoma or uncontrollable pressure, micro-/macrophthalmos, optic nerve atrophy, corneal transplant, ocular condition(s) which may impact stability of the IOL, pregnancy, vitreous loss. Clinical complications which have been encountered with this IOL include raised IOP requiring treatment, cataract formation, surgical reintervention, synechia, raised IOP requiring hospitalization, BSCVA loss > 0.2 logMAR and corneal haze. A high level of surgical skill is required for implantation and as such the surgeon should have successfully completed an Alcon approved training program for the AcrySof® Phakic Angle Supported IOL prior to beginning implantations with this IOL. ProVisc® Ophthalmic Viscosurgical Device is the recommended cohesive viscoelastic for use with this IOL. Improper delivery and/or orientation of the IOL during surgery may increase the risk of surgical reintervention, including explantation. Do not resterilize; do not store over 45° C; use only sterile irrigating solutions such as BSS® or BSS PLUS® Sterile Intraocular Irrigating Solution.

**ATTENTION:** Reference the Physician Labeling/Directions for Use for a complete listing of indications, warnings, and precautions.

## AcrySof® IQ ReSTOR® IOL

**CAUTION:** Federal (USA) law restricts this device to the sale by or on the order of a physician.

**INDICATIONS:** The AcrySof® IQ ReSTOR® Posterior Chamber Intraocular Lens (IOL) is intended for primary implantation for the visual correction of aphakia secondary to removal of a cataractous lens in adult patients with and without presbyopia, who desire near, intermediate and distance vision with increased spectacle independence. The lens is intended to be placed in the capsular bag.

**WARNING/PRECAUTION:** Careful preoperative evaluation and sound clinical judgment should be used by the surgeon to decide the risk/benefit ratio before implanting a lens in a patient with any of the conditions described in the Directions for Use labeling. Physicians should target emmetropia, and ensure that IOL centration is achieved. Care should be taken to remove viscoelastic from the eye at the close of surgery.

Some patients may experience visual disturbances and/or discomfort due to multifocality, especially under dim light conditions. Clinical studies with the AcrySof® ReSTOR® lens indicated that posterior capsule opacification (PCO), when present, developed earlier into clinically significant PCO. Prior to surgery, physicians should provide prospective patients with a copy of the Patient Information Brochure available from Alcon for this product informing them of possible risks and benefits associated with the AcrySof® IQ ReSTOR® IOLs.

Studies have shown that color vision discrimination is not adversely affected in individuals with the AcrySof® Natural IOL and normal color vision. The effect on vision of the AcrySof® Natural IOL in subjects with hereditary color vision defects and acquired color vision defects secondary to ocular disease (e.g., glaucoma, diabetic retinopathy, chronic uveitis, and other retinal or optic nerve diseases) has not been studied. Do not resterilize; do not store over 45° C; use only sterile irrigating solutions such as BSS® or BSS PLUS® Sterile Intraocular Irrigating Solutions.

**ATTENTION:** Reference the Directions for Use labeling for a complete listing of indications, warnings and precautions.

## AcrySof® IQ Toric IOL

Currently AcrySof® IQ Toric IOL is only available in the United States.

**CAUTION:** Federal (USA) law restricts this device to the sale by or on the order of a physician.

**INDICATIONS:** AcrySof® IQ Toric posterior chamber intraocular lenses are intended for primary implantation in the capsular bag of the eye for visual correction of aphakia and pre-existing corneal astigmatism secondary to removal of a cataractous lens in adult patients with or without presbyopia, who desire improved uncorrected distance vision, reduction of residual refractive cylinder and increased spectacle independence for distance vision.

**WARNING/PRECAUTION:** Careful preoperative evaluation and sound clinical judgment should be used by the surgeon to decide the risk/benefit ratio before implanting a lens in a patient with any of the conditions described in the Directions for Use labeling. Toric IOLs should not be implanted if the posterior capsule is ruptured, if the zonules are damaged, or if a primary posterior capsulotomy is planned. Rotation can reduce astigmatic correction; if necessary lens repositioning should occur as early as possible prior to lens encapsulation. All viscoelastics should be removed from both the anterior and posterior sides of the lens; residual viscoelastics may allow the lens to rotate.

Optical theory suggest, that, high astigmatic patients (i.e. > 2.5 D) may experience spatial distortions. Possible toric IOL related factors may include residual cylindrical error or axis misalignments. Prior to surgery, physicians should provide prospective patients with a copy of the Patient Information Brochure available from Alcon for this product informing

them of possible risks and benefits associated with the AcrySof® IQ Toric Cylinder Power IOLs.

Studies have shown that color vision discrimination is not adversely affected in individuals with the AcrySof® Natural IOL and normal color vision. The effect on vision of the AcrySof® Natural IOL in subjects with hereditary color vision defects and acquired color vision defects secondary to ocular disease (e.g., glaucoma, diabetic retinopathy, chronic uveitis, and other retinal or optic nerve diseases) has not been studied. Do not resterilize; do not store over 45° C; use only sterile irrigating solutions such as BSS® or BSS PLUS® Sterile Intraocular Irrigating Solutions.

**ATTENTION:** Reference the Directions for Use labeling for a complete listing of indications, warnings and precautions.

## AcrySof® IQ ReSTOR® Multifocal Toric IOL

Not available in the United States. International Only.

The information and materials within these sections do not pertain to the US market. Not all products are approved in every market, and approved labeling and instructions may vary by local country.

**CAUTION:** Federal law restricts this device to the sale by or on the order of a physician.

**INDICATIONS:** The AcrySof® IQ ReSTOR® Multifocal Toric IOL is intended for primary implantation for the visual correction of aphakia and pre-existing corneal astigmatism secondary to removal of a cataractous lens in adult patients with and without presbyopia, who desire near, intermediate, and distance vision, reduction of residual refractive cylinder, and increased spectacle independence. The AcrySof® IQ ReSTOR® Multifocal Toric IOL is indicated for the replacement of the human lens in refractive lens exchange (RLE) in adult patients who may benefit from near vision without a reading aid, and from increased spectacle independence. The lens is intended to be placed in the capsular bag.

**WARNINGS:** The safety and effectiveness of the AcrySof® IQ ReSTOR® Multifocal Toric IOL have not been clinically studied. Careful preoperative evaluation and sound clinical judgment should be used by the surgeon to decide the benefit/risk ratio before implanting a lens in a patient with any of the conditions described in the Directions for Use labeling. Some visual effects may be expected due to the superposition of focused and unfocused multiple images. These may include some perceptions of halos or radial lines around point sources of light under nighttime conditions. A reduction in contrast sensitivity as compared to a monofocal IOL may be experienced by some patients and may be more prevalent in low lighting conditions. Therefore, multifocal patients should exercise caution when driving at night or in poor visibility conditions. Toric IOLs should not be implanted if the posterior capsule is ruptured, if the zonules are damaged, or if a primary posterior capsulotomy is planned. Rotation can reduce astigmatic correction; if necessary lens repositioning should occur as early as possible prior to lens encapsulation. All viscoelastics should be removed from both the anterior and posterior sides of the lens; residual viscoelastics may allow the lens to rotate.

**PRECAUTIONS:** Studies have shown that color vision discrimination is not adversely affected in individuals with the AcrySof® Natural IOL and normal color vision. The effect on vision of the AcrySof® Natural IOL in subjects with hereditary color vision defects and acquired color vision defects secondary to ocular disease (e.g., glaucoma, diabetic retinopathy, chronic uveitis, and other retinal or optic nerve diseases) has not been studied. Do not resterilize; do not store over 45° C; use only sterile irrigating solutions such as BSS® or BSS PLUS® Sterile Intraocular Irrigating Solutions.

**ATTENTION:** Reference the Directions for Use labeling for a complete listing of indications, warnings, and precautions.

**Cataract & Refractive Surgery**  
EUROPE TODAY