Insert to

CRST EUROPE

Cataract & Refractive Surgery Today

April 2016
Sponsored by STAAR Surgical

Preserving the Cornea and the Lens for the Future

HIGHLIGHTS FROM THE ESCRS LUNCH SYMPOSIUM 2015

Seven Pearls for Successful ICL Implantation

A few key surgical principles will help improve the chances for successful implantation.

BY JAIME ARAMBERRI, MD

The Visian implantable collamer lenses (ICL) from STAAR Surgical are capable of delivering high-quality postsurgical vision. These seven pearls may improve surgical outcomes.

1. INTRAOPERATIVE AXIS ALIGNMENT

The incisions must be placed and the ICL positioned in the correct meridian to guarantee success, especially if a toric implant is used. Identifying the correct placement starts with the patient in the upright position so the surgeon can properly identify the exact 180° meridian; use of topography may assist in this step. The meridian should be marked for reference, with manual ink marks representing the most common approach to this step. Manual marks, however, are prone to error and the lines may bleed or disappear.

Then, when the patient is lying down, the target meridian for the ICL is identified. Although the manual reference marks may be helpful for this step, use of intraoperative aberrometry (such as the ORA from WaveTec Vision) or computer-assisted alignment (the Verion from Alcon or the Callisto from Carl Zeiss Meditec) may improve accuracy.

2. USE A GOOD QUALITY OPHTHALMIC VISCOSURGICAL DEVICE

Use of an improper ophthalmic viscosurgical device (OVD) during the surgery may cause postsurgical anterior capsule opacities (Figure). STAAR Surgical recommends the OVD used during an ICL surgery be composed of hydroxypropyl methycellulose (HPMC). I have also used sodium hyaluronate (NaHA) with good results, although this is not recommended by STAAR. Just as important as using the correct OVD is its removal: Complete aspiration at the end of surgery is mandatory for success.

3. FOLLOW PROPER SULCUS IMPLANTATION TECHNIQUE

The footplates of the Visian ICL are soft with low centrifugal pressure and, therefore, may in some cases be implanted asymmetrically, leading to asymmetric high vault. This error may not always be readily apparent to the surgeon. Therefore, it is important to nestle the ICL in a very gentle back-and-forth and right-to-left movement to ensure that the footplates rest in the posterior sulcus plane.

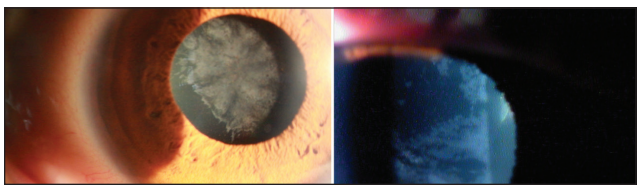

Figure. Cases of anterior capsule opacities have been reported with poor quality OVDs.

4. PERFORM I/A THROUGH THE CENTRAL PORT

Remnant OVD or other surgical debris left between the ICL and the crystalline lens is a risk factor for postoperative IOP elevation and inflammation. Thus, it is crucial to perform meticulous irrigation and aspiration during the surgery. The latest ICL model, the V4c Centraflow with the KS-AquaPORT*, which includes a central hole opening, has made it easier to aspirate the OVD at the end of the surgery and check the flow using acetylcholine.

5. PROPERLY UNFOLD THE IMPLANT

Most anterior segment surgeons are familiar with techniques for unfolding a lens in the eye. It is a routine step performed during lens-based procedures. But that does not mean the step always goes as planned. A very simple, but all too common mistake is that the ICL is loaded into the cartridge facing the wrong direction, and so when it is unfolded, it is positioned in an inverse position. If upside-down positioning occurs, it is not advisable to flip the lens, as this may cause endothelial damage; it is better to carefully explant the lens, reload, and implant again.

6. IRIS MANAGEMENT

The iris is a delicate structure that must be avoided during intraoperative maneuvers. Patient risk factors may elevate the risk of a complication. In particular, iris herniation is more likely in young patients, especially those with a shallow anterior chamber depth—especially hyperopes.

7. SURGICAL IRIDECTOMY VERSUS YAG

When using the earlier generations of ICLs, it was necessary to perform a peripheral iridectomy. The Visian ICL with Centraflow (model V4c) eliminates the need for this step,

because the central hole is intended to help maintain aqueous flow, and thus, regulates IOP. However the hyperopic ICL model (VICH) does not have a hole as its central thickness is larger. Therefore, iridectomy is still necessary in these cases, and proper patency may be best achieved with surgical iridectomy, either with an anterior chamber vitrector or with microscissors, rather than Nd:YAG laser. ■

*The KS-AquaPORT was named after and developed in cooperation with Kimiya Shimizu, MD, of Japan.

Jaime Aramberri, MD
- practices at the Begitek Ophthalmology Clinic, San Sebastian, Spain, and the Okular Ophthalmology Clinic, Vitoria, Spain
- jaimearamberri@telefonica.net
- financial disclosure: consultant to STAAR Surgical

Toric ICL Provides Predictable and Stable Correction of Astigmatism

A large series of patients demonstrates the viability of the lens.

BY ERIK L. MERTENS, MD, FEBOPHTH

The Visian implantable collamer lens (ICL) model with Centraflow (STAAR Surgical) is a welcome addition to the armamentarium of surgeons interested in helping patients achieve improved refractive status with a lens-based procedure. However, use of a phakic IOL need not be confined to correcting hyperopia and myopia. A large case series of patients from our institution demonstrates the viability of the toric ICL with Centraflow for the correction of astigmatism, and the results demonstrated the predictability and stability of the refractive correction.

EFFICACY

The accuracy of alignment of a toric implant is the single most important factor in the ability to correct the astigmatism without inducing any aberrations or optical deficiencies. The toric ICL with Centraflow features extended toric alignment markings on the horizontal axis to allow accurate rotation and alignment. I believe this accuracy was a key feature in the success of the patients in our case series.

We reviewed the records of 143 eyes of 88 patients implanted with the toric ICL who were a mean 39.98 ± 8.95 years (range, 18 to 52). At baseline, mean sphere was -5.60 ± 3.85 D (-17.75 D to + 2.50 D) and mean cylinder was -2.11 ± 1.22 D (-6.00 D to -1.00 D). We followed 124 eyes (87.32%) for at least 3 months, 90 (63.38%) for at least 6 months, and 69 eyes (48.59%) eyes for 1 year.

There was a significant improvement in UCVA compared with baseline at all follow-up visits, as well as demonstrated improvements in BCVA (Figure 1). Among eyes followed for 1 year, 100% and 99% achieved 20/25 and 20/20 vision, respectively, compared to 93% and 73% at baseline.

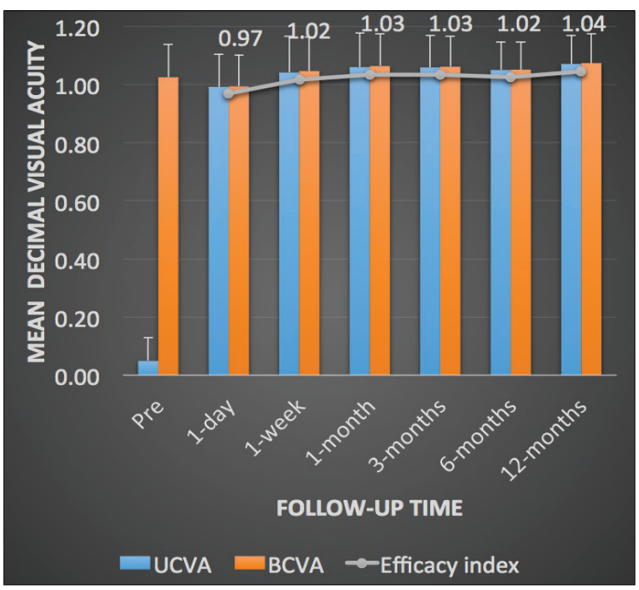

Figure 1. There was a significant improvement in UCVA compared with baseline at all follow-up visits, as well as demonstrated improvements in BCVA.

Importantly, I was consistently able to achieve a correction that was very close to the refractive target, indicating a highly predictable result with use of the Visian toric ICL (Figure 2). Correction of cylinder was also highly predictable among eyes followed for 1 year (Figure 3).

Through 1 year of follow-up, the results were remarkably stable. At baseline, the mean spherical equivalent was -6.65 D. This improved at day 1 to -0.16 D, and it was -0.16 D, 0.70 D, -0.09 D, and -0.16 D at 1, 3, 6, and 12 months, respectively.

SAFETY

In our series, only one patient required a lens exchange for a different power ICL, and one patient required repositioning. Almost all patients gained vision, and only one patient lost vision (2 lines) at 1 year. Mean IOP was 13.8 mm Hg at baseline and 13 mm Hg at 1 year with no apparent pressure spikes noted at any time point. Lens vault decreased over time, from 696.1 µm at day 1, to 664.3 µm at 1 week, to 633.8 µm at 1 month, to 595.3 µm at 3 months, to 578.7 µm at 6 months, and to 570.1 µm at 1 year. Of note, there were no cases of cataract due to contact of the ICL with the crystalline lens or due to any other reason.

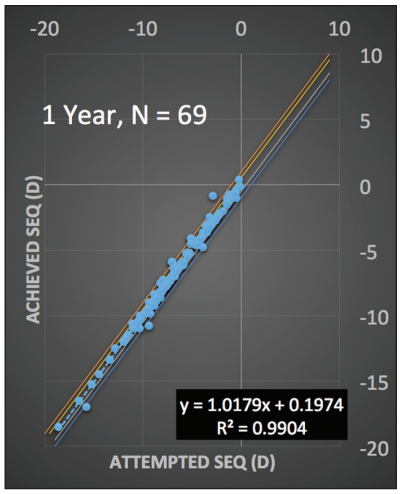

Figure 2. The Visian toric ICL consistently achieved a correction that was very close to the refractive target, indicating a highly predictable result.

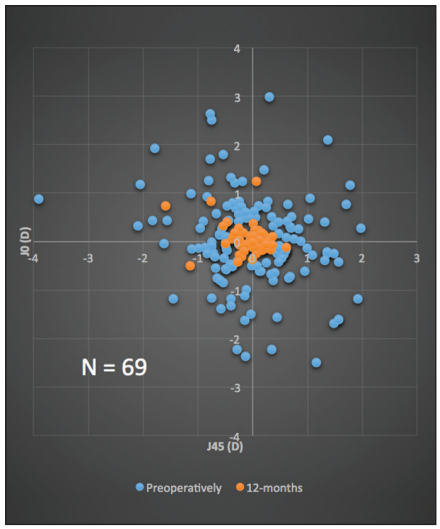

Figure 3. Correction of cylinder was also highly predictable among eyes followed for 1 year.

CONCLUSION

The results of our study demonstrate that the toric ICL provided predictable and stable resolution of astigmatism while providing improved refractive status. The safety of the implant was excellent. Our case series was retrospective in nature and is not intended to be a head-to-head comparison with other methods for correcting astigmatism. Nevertheless, the results provide a strong rationale for use of toric ICL implants for patients with low to moderate degrees of astigmatism. ■

Erik L. Mertens, MD, FEBOphth
- medical director, Medipolis, Antwerp, Belgium
- chief medical editor, *CRST Europe*
- e.mertens@medipolis.be
- financial disclosure: consultant to STAAR Surgical

Does ICL Implantation Offer Advantages Over LASIK?

ICL implantation offers a stable and predictable refractive correction with significant advantages over laser-based correction.

BY KIMIYA SHIMIZU, MD, PHD

The relative success of LASIK surgery as a refractive procedure has led many to believe it is the only viable option for correcting vision. However, phakic IOL implantation may offer distinct advantages over laser refractive surgery. For instance, the reversibility of phakic IOL implantation provides a more flexible option that accounts for age-related changes that may affect patients' refractive statuses.

With advances in lens technology and because of refinements in the surgery, there are now a plethora of options to match a phakic IOL to a patient's individual needs. The family of implantable collamer lenses (ICL) from Visian (STAAR

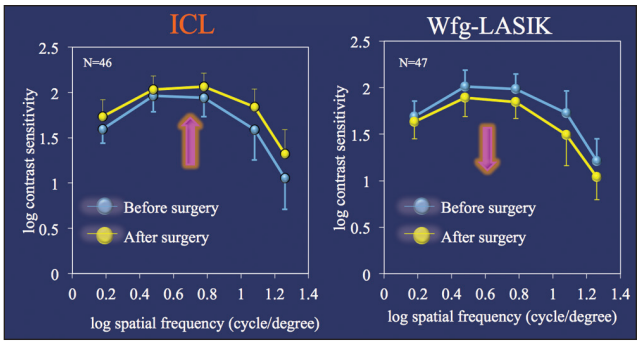

Figure 1. Postoperative contrast sensitivity improves in ICL but declines in LASIK.

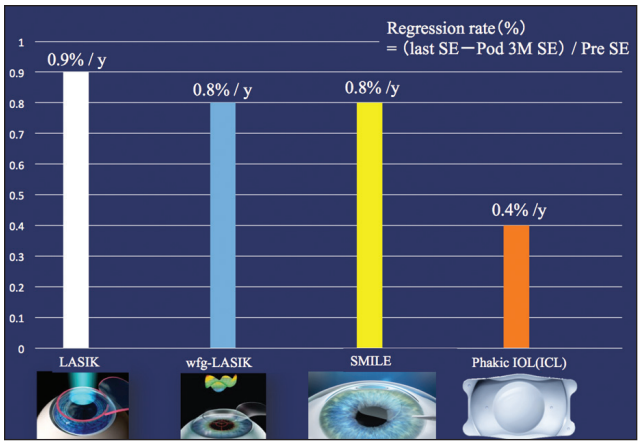

Figure 2. In spite of their high myopia, patients in the phakic IOL group experienced the lowest regression rate.

Surgical), in particular, may offer some distinct advantages over LASIK in terms of predictability and stability, while offering comparable quality of vision with the same level of or fewer complications.

In my view, refractive surgery should meet five important criteria: (1) it should improve visual acuity while providing patients with good visual quality, (2) it should be both predictable and stable, (3) it should be associated with few complications, and (4) there should be an ability for the surgeon to reverse course if anything untoward occurs. To a lesser extent, (5) the refractive surgery should not interfere with the ability to select an IOL in the future should cataract surgery be necessary.

It is for these reasons that I believe implanting phakic IOLs using the Visian ICL offers a superior option for most patients compared with even the most sophisticated laser refractive surgery procedure.

THE FIVE CRITERIA

Quality Vision

In published studies, ICL use has demonstrated a superior ability to provide improved visual acuity and quality of vision compared with conventional and wavefront-guided LASIK.

In a comparison of eyes that underwent conventional or wavefront-guided LASIK compared with eyes that were implanted with an ICL, the phakic IOL provided 100% of patients better than 20/30 UCVA at 1 and 4 years, and 95.5% of patients maintained this vision at 8 years.[1,2] Comparatively, the rates for 20/30 or better visual acuity at 1, 4, and 8 years for patients who received wavefront-guided LASIK (95.5%, 95.5%, and 86.4%, respectively) or conventional LASIK (93.8%, 81.3%, and 81.3%, respectively) were much lower.

ICL also provides better post-correction quality of vision. In 2009, my study group published a retrospective, observational case study comparing 46 eyes of 33 patients who underwent implantation with a Visian ICL and 47 eyes of 29 patients who received wavefront-guided LASIK (Technolas 217z excimer laser (Bausch + Lomb) to correct high myopia.[1] In our study, ICL use induced significantly fewer higher-order aberrations, including ocular coma-like and spherical-like aberrations. Interestingly, we noted that whereas contrast sensitivity decreased after LASIK, it increased after implantation with an ICL (Figure 1). Based on our results, we concluded that ICL implantation provided a superior option to wavefront-guided LASIK for the correction of high myopia. We have observed similar trends among eyes corrected for low to moderate myopia, with lower rates of induced third-order, fourth-order, and total aberration after ICL implantation compared with wavefront-guided LASIK.[2]

More recently, we published the results of a prospective analysis of 30 eyes after wavefront-guided LASIK and 30 eyes after ICL implantation.[3] Visual acuity was superior in the phakic IOL group compared with the wavefront-guided LASIK group at myopic defocus levels of 0.00, -1.00, and -2.00 D ($P < .001$, $P < .001$, and $P = .02$, respectively), and similar results were observed using cycloplegic refraction: Decimal visual acuity values at a myopic defocus of 0.00, -1.00, -2.00, and -3.00 D by optical simulation were estimated to be 1.95, 1.21, 0.97, and 0.75, respectively, in the phakic IOL group, and 1.39, 1.11, 0.94, and 0.71, respectively, in the wavefront-guided LASIK group. We concluded that on both clinical and optical measurements, the ICL provided better visual performance.

On a more subjective level, there is evidence that patients' satisfaction is higher after receiving an ICL implant compared with wavefront-guided LASIK, including scores for activity limitations, symptoms, appearance, and satisfaction with correction.[4]

Predictability and Stability

I was involved in a separate study to investigate the

long-term clinical outcomes of ICL implantation compared with wavefront-guided LASIK[5] (data on file with STAAR Surgical). For the study, we evaluated eyes of patients who underwent ICL implantation and compared with eyes of who underwent wavefront-guided LASIK for a minimum of 8 years. At the end of our study, 86% of patients implanted with an ICL were within 0.50 D of the refractive target and 100% were within 1.00 D. The predictability of the refractive correction after long-term follow-up was superior to that of eyes that underwent either wavefront-guided LASIK (59.1% within 0.50 D and 86.4% within 1.00 D of refractive target) or conventional LASIK (70.8% within 0.50 D and 81.6% within 1.00 D of the refractive target).

We have also observed the ICL to deliver stable refractive correction over time. Compared with wavefront-guided or conventional LASIK and the SMILE procedure, eyes implanted with an ICL IOL experience less loss of spherical equivalent over long-term follow-up (data on file with STAAR Surgical). Interestingly, in this study, patients in the phakic IOL group had the highest degree of myopia at baseline, which confers the greatest risk for loss of acuity over time.[5] In fact, despite the high myopia corrected in the phakic IOL group, this group experienced the lowest regression rate over time (Figure 2).

Safety and Complications

Post-LASIK ectasia is a well-known complication associated with laser vision correction, occurring in between 0.04% to 0.6% of cases.[6-8] Exact rates are unknown, however, and are believed to be lower after wavefront-guided LASIK compared with conventional LASIK. Nevertheless, in 2009, we noted that LASIK led to a significant reduction in corneal hysteresis and corneal resistance factor 3 months after surgery.[9] Both measures of corneal biomechanics portend a risk for development of corneal changes following surgery.

In evaluations in our research center, we have observed much less propensity for ICL implants to yield such effects on cornea biomechanics. In a retrospective review of 29 eyes of 16 consecutive patients (mean age ± SD, 32.4 ± 7.3 years) undergoing ICL implantation through a 3.0-mm temporal corneal incision, corneal hysteresis was 9.2 ± 1.4 mm Hg preoperatively, and 9.2 ± 1.4 mm Hg, 9.3 ± 1.7 mm Hg, and 8.8 ± 1.3 mm Hg at 1 week, 1 month, and 3 months postoperatively, respectively; the corneal resistance factor was 8.4 ± 1.6 mm Hg preoperatively, and 9.0 ± 1.5 mm Hg, 8.8 ± 1.7 mm Hg, and 8.8 ± 1.6 mm Hg, at 1 week, 1 month, and 3 months postoperatively, respectively.[10] These results, it should be noted, were similar in both normal and keratoconic eyes.

One noted complication of ICL surgery is inflammation. However, the effect of inflammation on pupil diameter appears transient, and it is likely that appropriate ICL sizing and careful surgery avoids any risk to the pupil.[11]

Lens vault has been described as an important factor in the risk for secondary cataract development after ICL implantation—ie, low lens vault may cause the lens to come in contact with the crystalline lens and cause posterior capsule opacification. Achieving appropriate lens vault is a matter of appropriate ICL sizing, as well as performing competent surgery. Additionally, younger age and greater white-to-white distance appear to predispose patients to achieving higher ICL vaulting over the crystalline lens.[12]

Reversibility

ICL has distinct advantages over LASIK and SMILE in terms of the reversibility of the procedure. An implanted lens can be routinely removed, and the surgery is not difficult or foreign to surgeons who perform lens implantation procedures.[13] LASIK is intended to reshape the cornea, thus increasing the chance for postoperative higher-order aberrations and a decrease in contrast sensitivity.[1] The step of creating the flap for LASIK may be associated with complications, including decreased visual function and patient discomfort. In addition, higher-order aberrations following LASIK surgery compounded by naturally occurring age-related lenticular changes may lead such patients to desire cataract surgery at a younger age.[14] However, cataract surgery on an eye that previously underwent LASIK is notoriously difficult and can be associated with refractive surprise (ie, unexpected hyperopic manifest refraction after surgery). On the other hand, cataract surgery following a previous ICL implantation avoids these complications and enables more accurate biometry and predictable IOL power calculation.[15]

CONCLUSION

It is my opinion that ICL implantation offers distinct advantages over LASIK surgery. Data from a number of studies support this impression. With advances in ICL technology, such as the release of the Visian ICL with a central hole, the separation between these two refractive modalities appears to be widening. ■

1. Igarashi A, Kamiya K, Shimizu K, Komatsu M. Visual performance after implantable collamer lens implantation and wavefront-guided laser in situ keratomileusis for high myopia. *Am J Ophthalmol*. 2009;148(1):164–170.e1.
2. Kamiya K, Igarashi A, Shimizu K, et al. Visual performance after posterior chamber phakic intraocular lens implantation and wavefront-guided laser in situ keratomileusis for low to moderate myopia. *Am J Ophthalmol*. 2012;153(6):1178–1186.e1
3. Kamiya K, Shimizu K, Igarashi A, Kawamorita T. Effect of myopic defocus on visual acuity after phakic intraocular lens implantation and wavefront-guided laser in situ keratomileusis. *Sci Rep*. 2015;5:10456.
4. Kobashi H, Kamiya K, Igarashi A, et al. Long-term quality of life after posterior chamber phakic intraocular lens implantation and after wavefront-guided laser in situ keratomileusis for myopia. *J Cataract Refract Surg*. 2014;40(12):2019–2024.
5. Kamiya K, Shimizu K, Igarashi A, Kobashi H. Factors influencing long-term regression after posterior chamber phakic intraocular lens implantation for moderate to high myopia. *Am J Ophthalmol*. 2014;158(1):179–184.e1.
6. Randleman JB, Russell B, Ward MA, et al. Risk factors and prognosis for corneal ectasia after LASIK. *Ophthalmology*. 2003;110:267–275.
7. Rad AS, Jabbarvand M, Saifi N. Progressive keratectasia after laser in situ keratomileusis. *J Refract Surg*. 2004; 20:S718–S722.
8. Pallikaris IG, Kymionis GD, Astyrakakis NI. Corneal ectasia induced by laser in situ keratomileusis. *J Cataract Refract Surg*. 2001;27:1796–1802.
9. Kamiya K, Shimizu K, Ohmoto F. Comparison of the changes in corneal biomechanical properties after photorefractive keratectomy and laser in situ keratomileusis. *Cornea*. 2009;28(7):765–769.
10. Ali M, Kamiya K, Shimizu K, et al. Clinical evaluation of corneal biomechanical parameters after posterior chamber phakic intraocular lens implantation. *Cornea*. 2014;33(5):470–474.

11. Kamiya K, Shimizu K, Igarashi A, Ishikawa H. Evaluation of pupil diameter after posterior chamber phakic intraocular lens implantation. *Eye* (Lond). 2010;24(4):588-594.
12. Kamiya K, Shimizu K, Komatsu M. Factors affecting vaulting after implantable collamer lens implantation. *J Refract Surg*. 2009;25(3):259-264.
13. Igarashi A, Shimizu K, Kamiya K. Eight-year follow-up of posterior chamber phakic intraocular lens implantation for moderate to high myopia. *Am J Ophthalmol*. 2014;157(3):532-539.e1.
14. Iijima K, Kamiya K, Shimizu K, et al. Demographics of patients having cataract surgery after laser in situ keratomileusis. *J Cataract Refract Surg*. 2015;41(2):334-338.
15. Kamiya K, Shimizu K, Igarashi A, et al. Clinical outcomes and patient satisfaction after Visian implantable collamer lens removal and phacoemulsification with intraocular lens implantation in eyes with induced cataract. *Eye*. 2010;24:304-309.

Kimiya Shimizu, MD, PhD
- professor of ophthalmology and chair of the department of ophthalmology, Kitasato University, Japan
- kimiyas@med.kitasato-u.ac.jp
- financial disclosure: consultant to STAAR Surgical

The Influence of Lens Design on Optical Performance

Collagen-based collamer lenses provide the optimal conditions for patients to recover vision and experience improvements in quality of vision.

BY ROBERTO ZALDIVAR, MD

I have been implanting STAAR Surgical's Visian implantable collamer lenses (ICL) as a refractive procedure for a long time in my clinical practice. I truly believe the ICL delivers superior performance in terms of optical quality and visual performance that is durable and long lasting. In fact, I have a lot of patients in my practice in whom I now have over 20 years of follow-up with a collamer lens.

The first posterior chamber phakic IOL, the IC 2020, was implanted on September 22, 1993. Over two decades later, this implant, the forbearer of the Visian ICL (STAAR Surgical), in my opinion, has been through more evolution and has demonstrated more success than any other lens in the field of refractive surgery.

The original model IC 2020, which had a concave profile with a radius of curvature back 11.37 mm and a length of 11.5 mm, was introduced in 1993 and followed by a series of modifications designed to improve performance. In 1994, another generation was released with changes in the periphery of the optical area, while conserving the same radius of back curvature; this was also the first model to feature haptics. A later model added the central hole. In 2011, the Visian ICL with Centraflow was launched featuring the KS-AquaPORT, aligning all of these innovative technological concepts.

Despite the generational changes in the design, patients continue to experience long-term success with the earlier models. In a case series of patients implanted between 1993 and 1994 who have 10 years or more of follow-up, uncorrected distance visual acuity improved from 2.66 logMAR at baseline to 0.46 logMAR, while best distance visual acuity improved from 0.26 logMAR to 0.36 logMAR (Table). Mean spherical equivalent improved from -11.20 D to -0.50 D.

TABLE. LONG-TERM SUCCESS OF PATIENTS WITH EARLY MODEL COLLAMER LENSES

	DATE	Preoperative					DATE	Postoperative						
EYE	SURGERY	UDVAlog	BDVA log	Sph	Cyl	Axis	CONTROL	UDVAlog	BDVA log	Sph	Cyl	Axis	IOL power	Size
OD	3/8/94	2	0.2	-8.5	-1.25	65	10/5/09	0.4	0.1	-0.75	-0.75	85	-11	11.5
OD	4/4/94	3	0.2	-11	-1	95	9/14/06	0.3	0.2	-1	0	0	-12.5	11.5
OS	2/17/94	3	0.3	-14	-2.5	0	11/13/13	0.7	0.7	0.25	-1.5	85	-13	11.5
OS	3/10/94	3	0.3	-12	-0.75	75	4/20/94	0.3	0.2	-0.75	-1	95	-13.5	11.5
OS	3/8/94	2	0.3	-9.5	-5.5	175	4/4/08	0.4	0.3	-0.75	-0.5	5	-12.5	11.5
OS	12/11/93	3	0.3	-12	-6	170	8/15/08	0.7	0.7	0	-0.75	170	-14.5	11.5

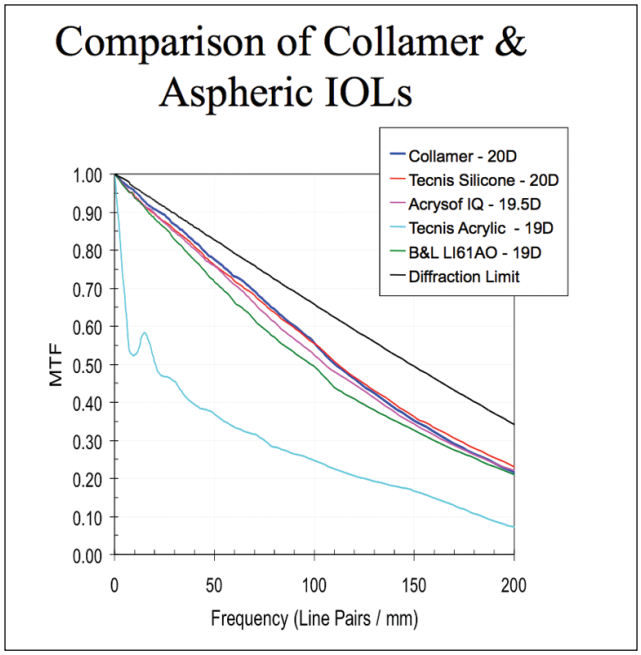

Figure. A modulation transfer function analysis showed that the ICL delivered nearly optimal light transference.

One of the main reasons for the long-term success in these patients is because of the materials used in their lens implants. Collamer lenses are constructed by bonding collagen and ultraviolet-absorbing chromophores into a poly-HEMA–based copolymer. To date, over 550,000 (data on file with STAAR Surgical) such lenses have been implanted worldwide. This material is available only from STAAR Surgical.

THE SCIENCE BEHIND THE LENS

In any visual system, dysphotopsias occur when light passes through materials with different refractive indexes. The refractive index is most critical at the interface of or transition between materials. However, the hydrophilic collamer technology (over 40% of the lens is composed of water) minimizes the difference in refractive index between the ICL and aqueous of the eye. In other words, light passes through the collamer lens in nearly an identical fashion as through a natural crystalline lens.[1] By mimicking the properties of the natural lens, glare, halo, and other optical aberrations are minimized.[1]

Many of my patients in whom I implant an ICL experience not only gains in visual acuity, but also report improvements in terms of optical quality. Although visual quality is somewhat subjective, there may be a basis for believing that the collamer lens delivers improved visual performance compared to other IOLs on the market.[2]

Martin and Sanders studied four different lens designs (Collamer, AA4204VF, Sensar [Abbott Medical Optics], and SA60 [Alcon]) to determine corresponding higher-order aberrations (HOAs) after implantation.[2] Their analysis revealed that all of lenses tested induced significantly more HOAs than the collamer lens; there were significantly less third- and fourth-order aberrations, coma, trefoil, spherical aberration, and tetrafoil observed postoperatively among patients implanted with the collamer lens.

This phenomenon of lower rates of HOAs is due to the collamer being less prone to diffraction. In an independent analysis of modulation transfer function, researchers showed that the collamer lens displayed nearly optimal diffraction-free performance (Figure). Combined, these studies reinforce the impressions my patients convey, that the ICL helps restore visual acuity as well as quality vision. Quite simply, the collamer lens supplies the optimal conditions for patients to recover nearly diffraction-free vision.

CONCLUSION

The use of collagen in the construction of the ICL may explain why inflammation, flare, and cellular reaction are reduced compared with other IOL options.[3,4] One study showed that clinical flare and cellular reaction after ICL implantation was absent in 99.6% to 100% of cases and there was no long-term inflammatory response over the course of 3 years of follow-up.[5] The use of a biocompatible substance means less potential for inducing an inflammatory or cellular response.

In my practice, I can attest to the fact that patients implanted with an ICL report vast improvements in quality of vision, which I believe is directly attributable to the use of collagen in the composition of the lens. Collamer mimics the characteristics of the natural human crystalline lens and transmits light in a nearly identical fashion. This hydrophilic lens with an integrated anti-reflective interface minimizes optical aberrations, giving patients the optimal conditions to have durable and meaningful improvements in visual acuity and visual quality. ■

1. Gontijo I. *The Collamer Story*. 2006. Data on file. STAAR Surgical, Monrovia, California.
2. Martin RG, Sanders DR. A comparison of higher order aberrations following implantation of four foldable intraocular lens designs. *J Refract Surg*. 2005;21(6):716–721
3. Till JS. Collamer intraocular lens implantation with active uveitis. *J Cataract Refract Surg*. 2003;2439–2443.
4. Fine IH. Aiming for a new level of biocompatibility. *Ophthalmology Management Supplement*. May 2000;6S–7S.
5. Sanders DR. Postoperative inflammation after implantation of the implantable contact lens. *Ophthalmology*. 2003;110:2335–2341

Roberto Zaldivar, MD
- scientific director of the Instituto Zaldivar, Mendoza, Argentina
- +54 261 441 9999; zaldivar@zaldivar.com
- financial disclosure: consultant to STAAR Surgical