

Cataract & Refractive Surgery TODAY

EUROPE

New Advances in Glaucoma Surgery: Alternatives to Standard Trabeculectomy

Material from the 2010 ICGS Symposium
in New Delhi, India.

A New Filtration Device



The EX-PRESS Glaucoma Filtration Device (Alcon Laboratories, Inc., Fort Worth, Texas; Figure 1) represents an alternative approach to trabeculectomy that may provide glaucoma patients fewer post-operative complications and a quicker visual recovery. Although clinical experience with the EX-PRESS device is still accumulating, it is showing promising results in several recently published studies, as described herein.

At the International Congress on Glaucoma Surgery symposium held in New Delhi in late 2010, noted clinicians described their use of the EX-PRESS device as well as additional strategies to enhance outcomes in some patients undergoing filtration surgery after failed medical procedures. We hope you find this monograph informative and relevant to your daily practice.

—Malik Y. Kahook, MD

*Associate Professor & Director of Research
University of Colorado Hospital Eye Center*

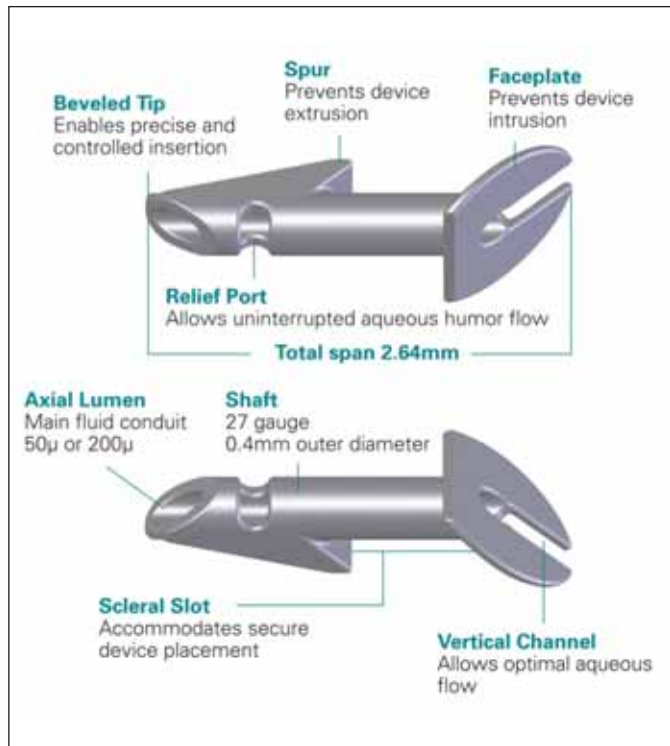


Figure 1. The EX-PRESS Glaucoma Filtration Device.

CONTENTS

- 3** THE “HOW” AND THE “WHOM” OF THE EX-PRESS DEVICE
By Robert D. Fechtner, MD
- 6** FASTER VISUAL RECOVERY WITH THE EX-PRESS DEVICE
Reported By Jennifer Byrne
- 8** CONJUNCTIVA-INDEPENDENT GLAUCOMA SURGERY
By Tarek Shaarawy, MD
- 10** CATARACT WITH GLAUCOMA: SURGICAL OPTIONS
By Tanuj Dada, MD
- 13** SURGICAL MANAGEMENT OF ANGLE-CLOSURE GLAUCOMA
By Prin Rojanapongpun, MD

The “How” and the “Whom” of the EX-PRESS Device

Pearls for choosing the best candidates and surgical techniques for the EX-PRESS device.

BY ROBERT D. FECHTNER, MD



When we evaluate glaucoma patients' candidacy for surgery, it is useful to classify them according to their disease, underlying medical conditions, and their estimated life expectancy.

This information helps us decide whether to perform surgery, what type of surgery to perform, and when.

Trabeculectomy has traditionally been glaucoma surgeons' surgical standard; it is a continuously evolving procedure that we each execute slightly differently. During my career, I have seen several important advancements in trabeculectomy surgery, including fornix-based limbal conjunctiva incisions, standard wound-management techniques, and releasable or laserable flap-suture techniques. These innovations have helped me immeasurably to improve outcomes and avoid complications.

When considering using the EX-PRESS Glaucoma Filtration Device (Alcon Laboratories, Inc., Fort Worth, Texas), I think it is essential that we understand both the “how” of the surgical technique and the “whom” of patient selection.

THE EX-PRESS DEVICE: WHAT IS IT?

The EX-PRESS Glaucoma Filtration Device is a small, stainless steel implant less than 3 mm in size (Figure 1). It has a channel that diverts aqueous from the anterior chamber under a scleral flap. The version of the EX-PRESS device I currently use (the P-50 model) has one port at the tip that faces into the eye, and another port that faces anteriorly toward the cornea. The anterior port helps avoid occlusion of the tip; even if some of the iris should touch the tip, there is a slot in the footplate that directs aqueous posteriorly and helps the surgeon correctly orient the device.

ADVANTAGES AND DISADVANTAGES

Why not just continue performing trabeculectomy in every glaucomatous patient? Many glaucoma surgeons have found several aspects of trabeculectomy surgery to be problematic. The EX-PRESS Glaucoma Filtration Device is useful in making a portion of the surgery more predictable and avoiding certain complications. The

device provides an opening of approximately 50 μm to somewhat regulate outflow. Additionally, the EX-PRESS device has demonstrated IOP-lowering efficiency similar to trabeculectomy, and it can reduce certain intraoperative complications and offer alternatives for postoperative care.

No single type of glaucoma surgery is right for all patients, and the EX-PRESS device may not be suitable for all eyes that need surgical reduction of IOP. The cost associated with this procedure has also been cited as a drawback compared with trabeculectomy.

IOP CONTROL: A RETROSPECTIVE STUDY

An early indicator of the usefulness of the EX-PRESS Glaucoma Filtration Device was a retrospective study of IOP control that compared the device with trabeculectomy. This report by Maris et al¹ showed that by 6 months, the pressure control was identical between trabeculectomy patients and EX-PRESS device patients. There was a higher mean IOP in the EX-PRESS device group in the early postoperative period. The success rate between the two groups was virtually identical, however.

PROSPECTIVE FINDINGS

Although there is not yet a multicenter, prospective, randomized, masked-observer comparison between the EX-PRESS procedure and trabeculectomy, several surgeons

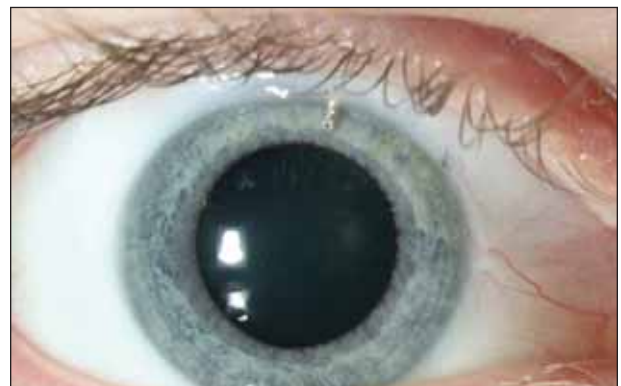

Figure 1. The EX-PRESS Glaucoma Filtration Device as seen at the slit lamp after implantation.

Courtesy of Ton J. Rouwen, MD, PhD, Utrecht, The Netherlands.

are now reporting their individual clinical results. One such study conducted by de Jongl² was a prospective, single-surgeon series in which 80 glaucomatous eyes were randomized to receive either the EX-PRESS device or trabeculectomy. Once again, the mean IOP was statistically the same between the two groups. Yet, the success rate, which was defined as IOP of less than or equal to 18 mm Hg, was lower in the trabeculectomy group. Only when medications were allowed did the trabeculectomy group's proportion of success equal that of the EX-PRESS device group.

PREOPERATIVE CONSIDERATIONS

How can we successfully use the EX-PRESS Glaucoma Filtration Device? My first guideline for implanting this device is to choose the right patients. My rule of thumb is that individuals who are poor candidates for trabeculectomy should not be considered for implantation with the EX-PRESS device. For me, these include patients with uveitis, neovascular glaucoma, or severe dry eye.

Preoperative gonioscopy is essential to effectively using the EX-PRESS device; you must know what is going on in the superior angle before you attempt an implantation. Narrow angles can make placement of the EX-PRESS device difficult.

CONJUNCTIVAL INCISION, ANTIFIBROSIS AGENTS

When making the conjunctival incision, I use the same approach as for trabeculectomy, provided that the incision is large enough to accommodate the delivery of standard wound management techniques and suturing of the flap. A fornix-based limbal incision maximizes exposure. I use my same wound-management techniques as with trabeculectomy.

THE SCLERAL FLAP

It is very important to create a properly sized scleral flap for the EX-PRESS device procedure. One common technical error is to make the flap too small and leave part of the implant exposed. A depth of 3 x 3 mm is sufficient to provide good coverage. Leave the sclera thick enough to cover the device on top and to support it from underneath; I consider 300- to 400- μ m flap thickness to be a good starting point in a normal eye. I encourage my colleagues to be cautious implanting the EX-PRESS device in eyes with thin sclera, such as high myopes, because they may not have enough scleral thickness to adequately support and cover the device.

ROLE OF THE PARACENTESIS

The paracentesis plays an important role in terms of deepening the chamber prior to inserting the EX-PRESS device. Making the paracentesis can cause some aqueous to escape and induce the iris to move forward. Our goal

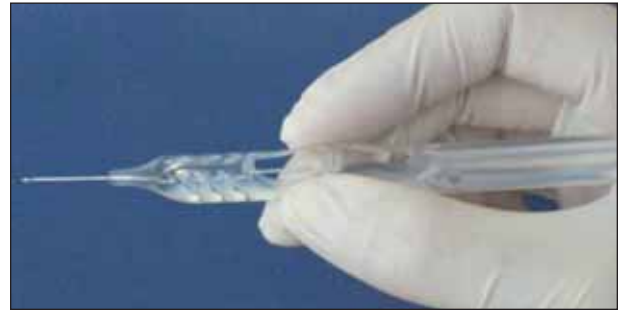

Figure 2. The EX-PRESS Glaucoma Filtration Device comes with its own inserter. The author positions his finger over the injector's trigger button and then applies downward pressure for a soft release.

is to recreate that space to allow for easy insertion of the device. I suggest creating a paracentesis similar to that used in trabeculectomy; it may be helpful to use an ophthalmic viscoelastic device for the first several cases.

ENTRY UNDER THE SCLERAL FLAP

Inserting the EX-PRESS Glaucoma Filtration Device under the scleral flap is an important aspect of performing the EX-PRESS device procedure. In my opinion, a 25-gauge needle is more than sufficiently large for this purpose. A 27-gauge needle is too small, unless you enlarge the opening. Some surgeons who desire a tighter fit may use a smaller needle, but for early cases, I think a 25-gauge needle is suitable. Because the plate has an anterior portion, it is important to leave space between the entry site and the anterior hinge of the flap—I prefer 1 mm from the hinge.

INSERTION AND FLAP CLOSURE

The EX-PRESS device inserter (Figure 2) is quite easy to use. It features a wire and an injector trigger button. Pressing on the release point causes the wire to withdraw, leaving the EX-PRESS device behind (Figures 3 and 4). Prior to entry, I keep the inserter in my hand, with my finger positioned over the injector trigger to allow for easy release.

Flap closure with the EX-PRESS device is slightly different than with trabeculectomy, because the former greatly slows the flow of fluid, and if the surgeon does not achieve a secure flap closure, he or she may see hypotony in the early postoperative period. When starting out with the EX-PRESS device, I suggest suturing the flap securely and then releasing sutures postoperatively.

CONJUNCTIVAL CLOSURE AND POSTOPERATIVE CARE

Conjunctival closure and postoperative care are largely the same with the EX-PRESS device as they are with trabeculectomy. I recommend using topical steroids and antibiotics and performing cycloplegia if necessary. I find

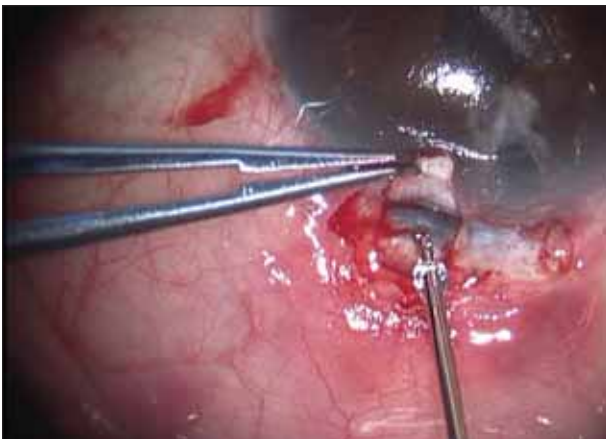


Figure 3. The author places the EX-PRESS device under the scleral flap via the inserter.

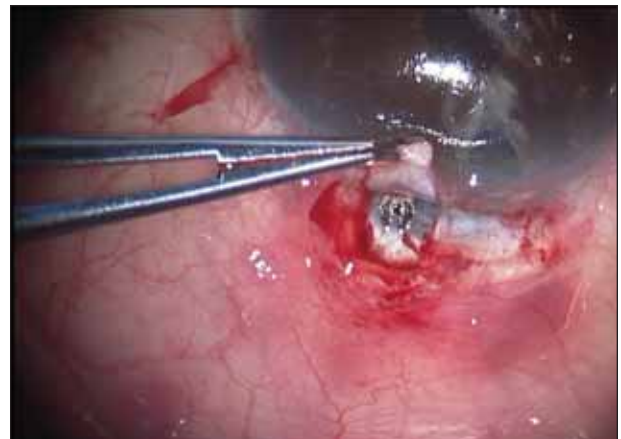

Figure 4. The EX-PRESS device in position before the author closes the scleral flap.

that many surgeons who implant the EX-PRESS device are comfortable releasing more sutures earlier, either with planned suture lysis or releasable sutures, starting at 4 to 7 days postoperatively. In general, these are quiet eyes that do not have the same spectrum of postoperative complications as their trabeculectomy counterparts (Figure 5).

EX-PRESS DEVICE PATIENT PROFILE

Once we understand the intricacies of the procedure, it is important to recognize the type of patient who is an appropriate candidate for the EX-PRESS device. Specifically, the device may be indicated for patients who are poor candidates for iridotomy due to risk of bleeding or inflammation. There is very little bleeding with the EX-PRESS device procedure. The EX-PRESS device may also be desirable when there is a need to avoid low intra- and postoperative IOP, such as in cases where there has been a suprachoroidal hemorrhage in the fellow eye. The EX-PRESS device does not need to cause the intraocular drop in IOP that trabeculectomy does, where the chamber shallows and the pressure goes to zero.

OTHER CONSIDERATIONS

Patients with anatomic considerations, such as eyes with a compromised angle, would not be suitable candidates for an EX-PRESS device. I also would not perform this surgery on patients with active uveitic glaucoma or those who are poor candidates for trabeculectomy due to conjunctival scarring or scleral problems.

SUMMARY

I would characterize the ideal first patient for implantation with the EX-PRESS device as someone who meets the surgeon's standards for trabeculectomy, is pseudophakic, has open-angle glaucoma with a wide open angle, and has had no previous conjunctival surgery. In my opinion, this is an excellent place to start in order to ensure the greatest chance for success with the EX-PRESS device. I find the EX-PRESS device procedure to be an




Figure 5. The EX-PRESS Glaucoma Filtration Device as seen at the slit lamp 2 months after implantation. Note the trabecular meshwork pigment band confirming the correct insertion site.

attractive alternative to trabeculectomy for appropriate patients, being that it is more controlled, requires less postoperative care, and produces results similar to trabeculectomy. I feel that the EX-PRESS device is a valuable tool in our battle against glaucoma. ■

Robert D. Fechtner, MD, is the director of the Glaucoma Division at the University of Medicine and Dentistry, New Jersey, and he is a professor of ophthalmology at the Institute of Ophthalmology, both at New Jersey Medical School in Newark. He is a consultant to and has received research support from Alcon Laboratories, Inc., and Allergan, Inc. Dr. Fechtner may be reached at phone: +1 973-972-2030; e-mail: fechtner@umdnj.edu.

1. Maris PJ Jr, Ishida K, Netland PA. Comparison of trabeculectomy with Ex-PRESS miniature glaucoma device implanted under scleral flap. *J Glaucoma*. 2007;16 (1):14-19.
2. de Jong LA. The Ex-PRESS glaucoma shunt versus trabeculectomy in open-angle glaucoma: a prospective randomized study. *Adv Ther*. 2009;26(3):336-345.

Faster Visual Recovery With the EX-PRESS Device

A review of one surgeon's early experience using this device.

REPORTED BY JENNIFER BYRNE

When adopting a new glaucoma surgery procedure, it is beneficial for clinicians to evaluate the technology against the existing surgical standards. To effectively assess the clinical value of a new device, practitioners must compare the surgical outcomes, rate and nature of complications, and patients' visual recovery against the current standard practice.

"After completing a few cases with a new technique or device, we must ask ourselves how much of a difference it makes in our care of patients," said Malik Y. Kahook, MD, associate professor of ophthalmology at the University of Colorado. "This was the question I asked myself when I began using the EX-PRESS device."

Dr. Kahook reported the results of a retrospective, consecutive, case-controlled series using the EX-PRESS Glaucoma Filtration Device (Alcon Laboratories, Inc., Fort Worth, Texas). The series consisted of 70 patients,¹ 35 of whom received the EX-PRESS device and 35 who underwent trabeculectomy. Both groups received standard wound-management techniques. The series included four parameters: Moorfields Bleb Grading System, IOP, number of complications, and postoperative visual results.

PATIENT DEMOGRAPHICS

Demographically, the patient groups in the study were similar in age, sex and diagnosis. The average age was 68.9 years in the EX-PRESS group and 69.3 years in the trabeculectomy group, and the ratio of male to female patients was 19/16 in the EX-PRESS group and 17/18 in the trabeculectomy group. "There were a few patients with angle-closure glaucoma, but these were patients who were already pseudophakic," Dr. Kahook said. "They'd had their cataract surgery, and had deep chambers." Preoperative medications and lens status were also similar between the two groups, he reported.

METHODS

Dr. Kahook and his staff performed all cases in this series using the P-50 model of the EX-PRESS device, which has a 50- μ m internal lumen. Dr. Kahook created a fornix-based incision for the conjunctiva, made a 3-mm trapezoidal scleral flap, and used an entry site within the sclera that was approximately 0.5 mm away from the blue line. "The goal was to have the device sitting within

the sclera to provide support, and to prevent the device from wiggling or moving," he stated. He used a 27-gauge needle for all the EX-PRESS device cases to achieve a snug fit around the device.

IOP RESULTS

Dr. Kahook defined "complete success" in this study as a postoperative IOP of between 5 and 18 mm Hg, with at least a 30% decrease in IOP without IOP-lowering medication. He considered "qualified success" to be the same IOP outcomes but with the use of IOP-lowering medications postoperatively. Postsurgical IOP was statistically similar in both groups at baseline and in the early postoperative period, except at the 1-week follow-up visit, when the EX-PRESS device group showed a somewhat higher IOL ($P=.019$). Furthermore, IOP was slightly higher in the EX-PRESS device group at 1 year and at the last follow-up visit ($P=.004$ versus $P=.008$ for the trabeculectomy group; Figure 1). "However, the percentage by which IOP lowered from baseline to the last follow-up visit in each group (45.15% in the EX-PRESS device group and 48.45% in the trabeculectomy group) was statistically similar," Dr. Kahook said. "In my hands, the two procedures are similar as far as IOP reduction."

The rate of complete success was 77% in the EX-PRESS device group and 74% for the trabeculectomy eyes. An additional 5% of EX-PRESS device patients and 8% of

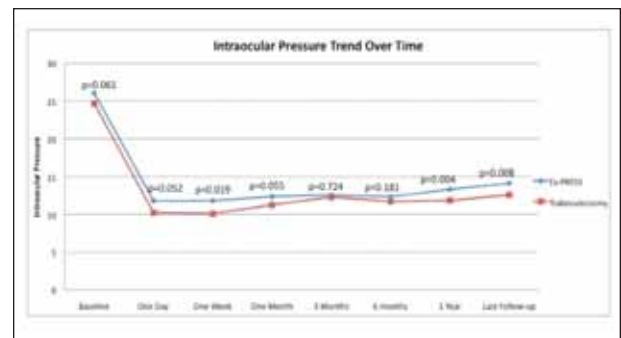


Figure 1. The rate of IOP up to 18 months between eyes that underwent trabeculectomy versus eyes that received the EX-PRESS device.

(Reprinted from Good TJ, Kahook MY. Assessment of bleb morphologic features and postoperative outcomes after EX-PRESS Drainage Device implantation versus trabeculectomy. *Am J Ophthalmol.* 2011;151(3):507-513, with permission from Elsevier.)

trabeculectomy patients achieved qualified success, according to Dr. Kahook.

MOORFIELDS BLEB GRADING SYSTEM

Dr. Kahook and his team evaluated both groups of eyes using the Moorfields Bleb Grading System, which involves measuring the central demarcated area and maximum area of the bleb, the bleb's highest point, and the vascularization of the central demarcated bleb, peripheral bleb, and peripheral nonbleb-related conjunctiva. They found that early differences in bleb vascularity between the two groups had decreased by the conclusion of the study. "The blebs in the EX-PRESS device group were less vascular than the blebs in the trabeculectomy group, up until 1 year to 18 months," Dr. Kahook said (Figure 2). "Toward the end of the study—between 18 and 28 months—the vascularization of the blebs was similar between the two groups." Dr. Kahook reported similar findings in terms of the height and area of location of the blebs, with statistically significant differences emerging early in the study. Within the first year, the height was lower and the blebs more diffuse in the EX-PRESS device group, but at the end of the follow-up period, these results were also similar between the two groups.

POSTOPERATIVE VISUAL RECOVERY AND VISITS

One finding that was markedly different between the eyes that underwent trabeculectomy and those that received the EX-PRESS device, according to Dr. Kahook, was that of postoperative visual recovery. "We found that the EX-PRESS device group returned to baseline visual acuity at 1 week, whereas it took 1 month for the trabeculectomy patients to return to baseline visual acuity," he said. "There was quicker visual recovery with the EX-PRESS device than after trabeculectomy." The EX-PRESS patients also required fewer postoperative visits (6.05, SD=0.54) than the trabeculectomy group (8.23, SD=0.92), he reported in the study. These findings were statistically significant.

MEDICATIONS AND COMPLICATIONS

The mean number of prescribed pre- and postoperative medications was similar between the two groups, Dr. Kahook noted. Although the findings also showed fewer complications in the EX-PRESS device group than in the trabeculectomy group, the patient population of the study was not large enough to demonstrate statistical significance. The EX-PRESS device group showed less hypotony and hyphema than the trabeculectomy group, Dr. Kahook said.

STUDY CONCLUSIONS

Overall, Dr. Kahook said the study results showed similar outcomes between the two surgeries. "We found that the two procedures yielded similar rates of complete and qualified success, and similar IOP-lowering capability," he said. He added that although the Moorfields Bleb Grading




Figure 2. Moorfields Bleb Grading System for vascularity.

(Reprinted from Good TJ, Kahook MY. Assessment of bleb morphologic features and postoperative outcomes after EX-PRESS Drainage Device implantation versus trabeculectomy. *Am J Ophthalmol.* 2011;151(3):507-513, with permission from Elsevier.)

System initially favored the EX-PRESS device, these results became equivalent between the two groups by the end of the study. However, the EX-PRESS device outperformed trabeculectomy in several other parameters. "The EX-PRESS device demonstrated faster postoperative visual recovery, fewer follow-up visits, and fewer complications than trabeculectomy," Dr. Kahook reported.

WHEN TO USE THE EX-PRESS DEVICE

These findings may serve as guidance in deciding when and for which patients the EX-PRESS device procedure is indicated. Dr. Kahook said he has found this procedure to be appropriate for the following patients:

- those who are at high risk for hypotony, such as high myopes, as well as for those requiring faster visual recovery, such as monocular patients;
- those with combined glaucoma/cataract extraction; and
- people at high risk for hyphema, such as anticoagulated patients or those with a history of uveitis.

For his own clinical experience with the EX-PRESS device, Dr. Kahook started with a pseudophakic patient who had primary open-angle glaucoma and an angle that could easily accommodate the device. "This is the type of patient I would first implant with the EX-PRESS device," Dr. Kahook said. "After gaining experience with the device, I suggest that surgeons adapt the procedure to their patient population, and I think they will achieve the same success in these patient categories that I have." ■

Malik Y. Kahook, MD, is an assistant professor of ophthalmology and the director of clinical research, Department of Ophthalmology, the University of Colorado at Denver & Health Sciences Center. He has received research support from and is on the speakers' bureau of Alcon Laboratories, Inc. Dr. Kahook may be reached at phone: +1 720-848-5029; e-mail: malik.kahook@uchsc.edu.



1. Good TJ, Kahook MY, et al. Assessment of bleb morphologic features and postoperative outcomes after EX-PRESS Drainage Device implantation versus trabeculectomy. *Am J Ophthalmol.* 2011;151(3):507-513.

Conjunctiva-Independent Glaucoma Surgery

An ab interno, minimally invasive surgical option.

BY TAREK SHAARAWY, MD



It is mandatory that we glaucoma surgeons evaluate the ocular surface and the health of the conjunctiva. A conjunctiva that is scarred from years of exposure to topical medications can make the surgical procedure long and difficult.

Because the tissue is more susceptible to postoperative scarring, it can compromise surgical outcomes. Since the adverse effects of antiglaucoma medications and benzalkonium chloride (the most commonly used preservative) is dose dependent, each additional eye drop decreases the chances of success with conventional glaucoma surgical procedures. Thus, we need to judiciously choose between the potentially deleterious effects of exposing the eye to multiple antiglaucoma medications versus the risks and benefits of surgery.

The current surgical options for glaucoma surgery include trabeculectomy (which is the gold standard), tube shunts, nonpenetrating glaucoma surgery, cyclophotocoagulation, and conjunctiva-independent surgery. Conjunctiva-independent surgery is considered the “new kid on the block” among the current surgical interventions for glaucoma. According to the available evidence based on limited experience, these ab interno approaches can be performed quickly, do not damage the conjunctiva, and appear to be safe. Their main advantage is that they do not rely on the conjunctiva for surgical success, leaving it unaffected and available for later use in case of surgical failure. Three established conjunctiva-independent approaches include conjunctiva-independent Trabectome surgery (NeoMedix, Inc., Tustin, CA), the trabecular microstent (the iStent; Glaukos Corp., Laguna Hills, CA; not available in the United States), and the CyPass implant (Transcend Medical, Inc., Menlo Park, CA; not available in the United States).

TRABECULECTOMY, TUBES

Nonpenetrating glaucoma surgery and trabeculectomy both essentially depend on the limbal conjunctiva for success and thus are contraindicated in a scarred limbal conjunctiva. A potential course of action in these eyes is a tube, which shunts the aqueous to an area posterior to the limbus and thus bypasses the limbal conjunctiva. This procedure is not without significant complications, however. Extrusions are particularly problematic, according to the Tube Versus Trabeculectomy (TVT) study, and they occur in

“Ab interno approaches can be performed quickly, do not damage the conjunctiva, and appear to be safe.”

up to 5% of cases.¹ Such a risk can be lessened by placing a tube in a tunnel to protect it, creating a deep trench in which to bury the tube, and using a large envelope flap (9 x 5 mm; Figure 1). Conjunctival scarring remains a determinant of surgical success, however.

Therefore, we must consider other options that circumvent the conjunctiva. Conjunctiva-independent surgery is essentially an ab interno approach, which has the potential to drastically influence the results of glaucoma surgery.

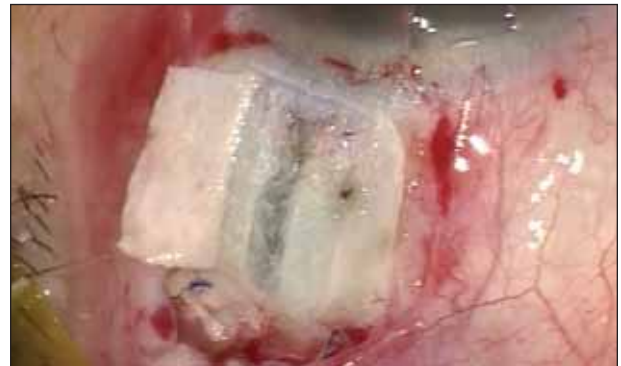

Figure 1. The author creates a scleral envelope and deep trench for implanting the Ahmed Glaucoma Valve (New World Medical, Inc., Rancho Cucamonga, CA).

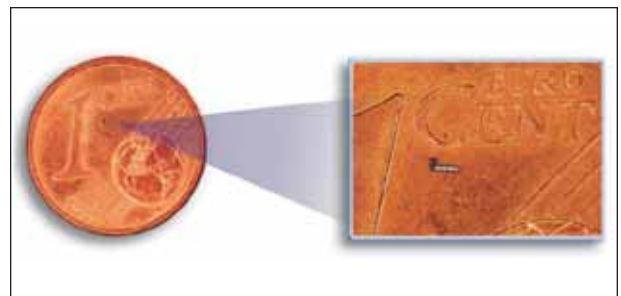


Figure 2. The iStent trabecular microstent is the fraction of the size of a 1-cent coin.

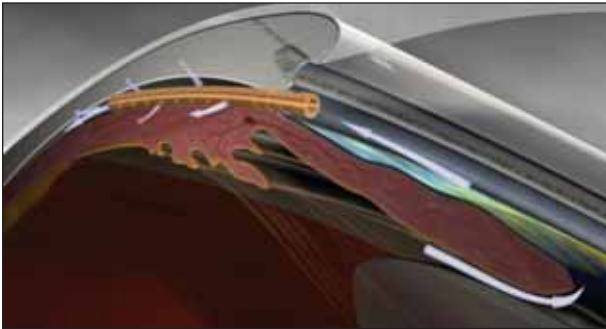


Figure 3. The CyPass supraciliary device targets aqueous outflow through the supraciliary space.

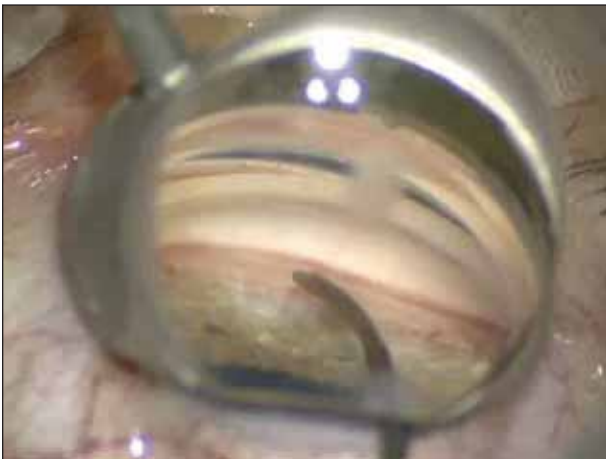

Figure 4. The author creates the anterior chamber paracentesis to implant the CyPass.

AB INTERNO TRABECULECTOMY

One of the more widely accepted conjunctiva-independent surgeries is ab interno trabeculectomy with the Trabectome. The procedure involves an electrocautery ablation of the trabecular meshwork and inner wall of Schlemm's canal through a paracentesis incision under gonioscopic guidance. I was privileged to participate in the early clinical trial of the first 101 cases of ab interno trabeculectomy with George Baerveldt, MD, and Donald S. Minckler, MD, both at the University of California, Irvine.² Our early results showed that the procedure spared the conjunctiva and was minimally invasive. IOP outcomes to date in our clinical case series have been in the mid-to-low teens, so the procedure may not be appropriate for eyes in which a very low IOP goal is deemed necessary. As with any new glaucoma surgery, patient selection should take into account the expected IOP outcome.

MICROSTENT SURGERY

The rationale for using a trabecular microstent (the iStent; Figure 2) is that it provides a channel for direct transtrabecular aqueous outflow from the anterior chamber to collector channels. The device is self-retaining, constructed of implant-grade titanium (6AL4V), and coated with heparin.

The microstent is implanted under gonioscopic guidance using an applicator introduced via an anterior chamber paracentesis.

Most clinical studies of the iStent have been encouraging, showing decreased medication requirements postoperatively and reduced IOP to an average of approximately 17 mm Hg after iStent instillation. Complications have been infrequent, with the most common being malpositioning of the iStent presumed to lead to clinical failure. Reflux bleeding from Schlemm's canal after viscoelastic removal intraoperatively has been common.

THE CyPASS MICROSTENT

The final ab interno approach is the CyPass supraciliary device (Figure 3). Unlike other tubes, it does not target the conventional pathways such as the trabecular meshwork and Schlemm's canal system. Again, the surgeon creates a paracentesis by injecting viscoelastic into the anterior chamber under the guidance of a gonioscopy lens (Figure 4). After inserting the CyPass, the goal is to target the aqueous outflow through the supraciliary space by positioning the outlet of the tube between the sclera and the ciliary body, almost like a surgical prostaglandin. This approach taps into the eye's strategic reserves of uveoscleral outflow. The first time I attempted this procedure, I was skeptical about how easy it would be to properly place the CyPass. I found that the sclera's rigidity guides the tube into the space between the ciliary body and the sclera. The procedure is quite straightforward and is not particularly challenging for the trained surgeon. Long-term follow-up results are necessary.

ADVANTAGES OF CONJUNCTIVA-SPARING PROCEDURES

I am interested in conjunctiva-sparing procedures for glaucoma therapy, because they are fast and relatively safe, based on the data thus far. However, these modalities need more long-term data on their safety and ability to lower IOP. Nevertheless, they appear to offer viable options for driving IOP below critical levels without damaging the conjunctiva, which leaves those tissues available for conventional filtration procedures if and when required. Controlled, randomized, head-to-head comparisons with trabeculectomy are essential before these devices can gain widespread use. ■

Tarek Shaarawy, MD, is head of glaucoma in the Ophthalmology Service, Department of Clinical Neurosciences, Geneva University Hospitals, Switzerland. He acknowledged no financial interest in the products or companies mentioned herein. Dr. Shaarawy may be reached at e-mail: tarek.shaarawy@hcuge.ch.

1. Gedde SJ, Schiffman JC, Feuer WJ, et al. Three-year follow-up of the tube versus trabeculectomy study. *Am J Ophthalmol.* 2009;148(5):670-684.

2. Minckler D, Baerveldt G, Remierez MA, et al. Clinical results with the trabectome, a novel surgical device for the treatment of open angle glaucoma. *Trans Am Ophthalmol Soc.* 2006;104:40-50.

Cataract With Glaucoma: Surgical Options

When is combined or sequential surgery indicated for these coexisting conditions?

BY TANUJ DADA, MD



The coexistence of glaucoma and cataract is a common occurrence that requires insight into the diagnosis and management of both conditions. The presence of a cataract can affect the ability to detect glaucoma, and cataract surgery can affect both IOP control and the effectiveness of previously performed glaucoma surgery.

The management of coexistent glaucoma and cataract is a complex issue with several therapeutic options, and there is currently a dearth of clear guidelines based on the evidence from the literature. When deciding how to manage patients with coexisting cataract and glaucoma, we must consider the impact of each condition on the diagnosis and treatment of the other as well as the indications for a combined surgery versus cataract or glaucoma surgery alone.

THE IMPACT OF CATARACT ON THE EVALUATION OF GLAUCOMA

First, we must consider the extent to which the presence of a cataract may compromise the evaluation of the glaucomatous eye. The development of a cataract worsens the mean deviation across all tests of the visual field, including standard automated perimetry, frequency doubling perimetry, and short-wavelength automated perimetry. For this reason, visual field analyses are not considered reliable in cases of coexisting glaucoma and cataract. Also, some studies have indicated that the presence of a cataract may affect the visual field index/glaucoma progression index as well as the characterization of scotomas.¹ Therefore, the presentation of a cataract may affect the decision to monitor versus operate on the glaucomatous eye.

The existence of a cataract may also obfuscate the evaluation of optic nerve structures and the retinal nerve fiber layer (RNFL). The use of optical coherence tomography (OCT) in assessing the RNFL of patients with cataracts can cause an underestimation of the thickness of the RNFL and may lead to a false detection of progression with OCT due to the cataract. According to a study conducted by Mwanza and colleagues at the Bascom Palmer Eye Institute,² thinning of the peripapillary RNFL that is typically characteristic of glaucomatous

RNFL Parameters	Pre operative	Post operative	P value
TSNIT average	49.2 ± 14.1	56.5 ± 7.6	0.001
Superior average	51.6 ± 12.2	59.8 ± 7.3	0.004
Inferior average	50.2 ± 13.7	61.5 ± 10.3	0.001
NI1	41.3 ± 15.3	21.6 ± 11.9	0.001

Figure 1. GDx VCC parameters pre- and postcataract surgery.³

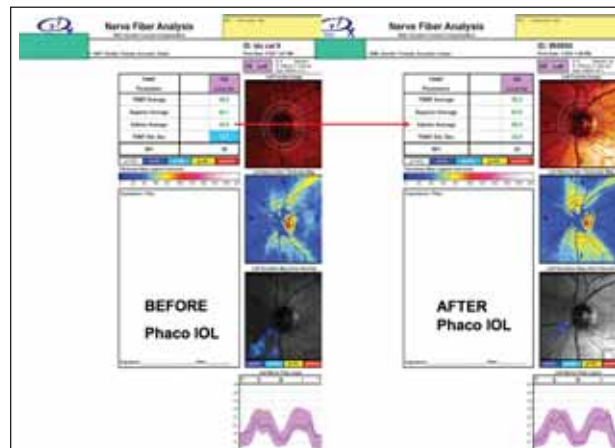


Figure 2. A GDx VCC printout shows increased thickness of the retinal nerve fiber layer after cataract surgery.

progression may, in cases of coexisting cataract, be due instead to artifact from advancing cataract.

In another study, colleagues and I assessed the measurement of the RNFL using the GDx scanning laser perimeter (Carl Zeiss Meditec, Inc., Dublin, CA) in patients before and after they underwent cataract surgery.³ We found a definite increase in the RNFL thickness after cataract surgery, and we concluded that the cataract was retarding the signal and leading to an underestimation of the parameters of the RNFL (Figures 1 and 2). Therefore, in the presence of a cataract, there may be a false underestimation of the thickness of the peripapillary RNFL, primarily due to a decrease in the signal-to-noise ratio.

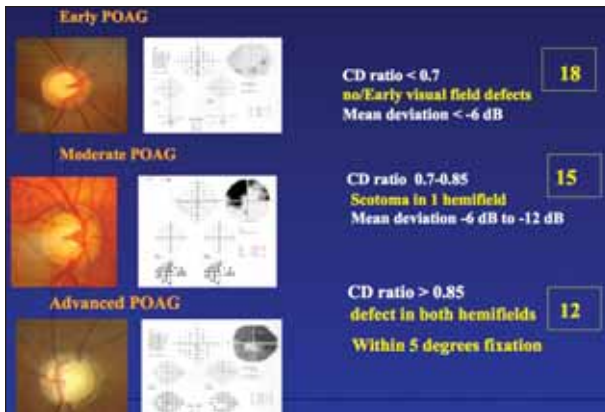


Figure 3. Setting the target IOP in glaucomatous eyes with a cataract.

EFFECT OF TRABECULECTOMY ON CATARACTOGENESIS

Another important consideration is the potential effect of trabeculectomy on accelerating cataract development in glaucomatous eyes. The Advanced Glaucoma Intervention Study (AGIS) clearly showed a 78% increased risk of cataract in patients who have undergone a first trabeculectomy.⁴ This heightened risk was determined in AGIS eyes after adjusting for age and diabetes, and it was especially pronounced in eyes with a shallow anterior chamber or a history of uveitis following cataract surgery.

EFFECT OF CATARACT SURGERY ON IOP

According to a review by Shrivastava and Singh published in *Current Opinion in Ophthalmology*,⁵ there may be a modest, long-lasting decrease in IOP following phacoemulsification in some eyes with open-angle glaucoma and ocular hypertension. We must also consider the impact of cataract surgery on eyes that already have a filtering bleb. The literature shows that phacoemulsification has an adverse effect on bleb function, even in surgeries that avoid the area of the bleb, such as temporal clear corneal phacoemulsification.

SURGICAL OPTIONS AND INDICATIONS

In deciding when to perform combined phacoemulsification and trabeculectomy surgery, I think it is wise to consider the extent of glaucomatous damage, the type of patient, the surgeon's individual expertise, and the number of topical medicines the patient is taking. When evaluating the severity of glaucoma, the surgeon must look at the target pressure that is required for the individual case (Figure 3). Most glaucoma patients I see present at a moderate-to-advanced stage and require an IOP below 15 mm Hg. After assessing an individual's IOP, I consider whether he or she is compliant with topical medications and whether his or her geographic location is conducive to a two-phased surgery. Once I decide to

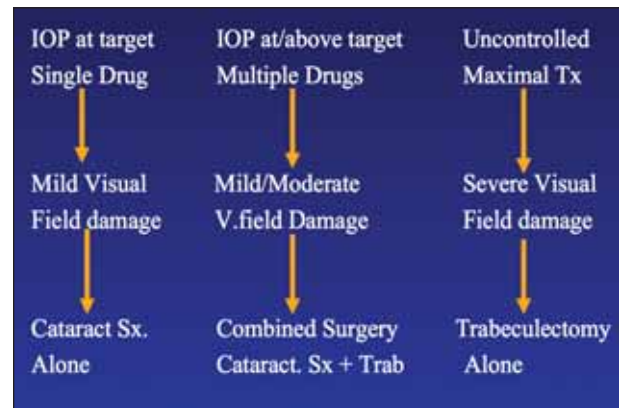

Figure 4. Decision tree for treating a glaucomatous eye with a cataract.

proceed with surgery, I have three options: cataract surgery alone, combined cataract and glaucoma surgery, or two-phased surgery (glaucoma surgery followed by cataract surgery, or vice versa) (Figure 4).

Cataract surgery alone may be sufficient in cases of elevated glaucoma or ocular hypertension or when the IOP is well controlled with a single drug. It is important to remember, however, that cataract surgery in such eyes requires pharmaceutical control of the IOP postoperatively. To control the IOP in these eyes as well as possible, I thoroughly remove all viscoelastic at the conclusion of cataract surgery, and I administer a drop of timolol immediately after surgery before patching the eye in the postoperative period.

Trabeculectomy surgery alone is indicated in eyes that need to achieve a very low target IOP. The procedure is also appropriate for patients who are poor candidates for combined surgery, including those with

- advanced glaucomatous optic neuropathy
- a very high IOP that is not controlled medically
- a poor prognosis for trabeculectomy, due either to excessive conjunctival scarring or secondary glaucoma such as uveitic or neovascular glaucoma
- pseudoexfoliation or a subluxated lens with anticipated vitreous loss

Combined surgery may be warranted for

- patients with early-to-moderate glaucoma
- patients with IOP above or at the required target on multiple medications
- noncompliant patients or those experiencing side effects of medications
- patients whose geographic locations preclude returning for a second surgery

One important factor to consider is the IOP-lowering potential of combined surgery versus trabeculectomy alone. This has been addressed in several studies, which have found that the IOP-lowering capability of trabeculectomy alone is far superior to that of combined

“There is an unmet need for developing a surgical technique for combined cataract and glaucoma surgery with IOP-lowering efficacy similar to trabeculectomy.”

phacoemulsification and trabeculectomy. There is an unmet need for developing a surgical technique for combined cataract and glaucoma surgery with IOP-lowering efficacy similar to trabeculectomy. New microsurgical shunts like the EX-PRESS Glaucoma Filtration Device (Alcon Laboratories, Inc., Fort Worth, Texas) may offer some advantages in terms of lowering complication rates as compared to standard trabeculectomy, but they need to be evaluated in terms of long-term IOP control when used in combination with phacoemulsification.⁶

TECHNIQUE RECOMMENDATIONS

According to an evidence-based review published in *Ophthalmology*,⁷ there are three important points to remember when considering the surgical technique for glaucomatous eyes:

- In all combined surgery, the use of standard wound-management techniques will provide a 2- to 4-mm Hg benefit
- Two-site surgery is superior to single-site surgery as far as IOP reduction is concerned
- Performing cataract surgery after trabeculectomy may compromise bleb function

My preferred approach for most glaucomatous eyes with cataract is first to perform temporal clear corneal phacoemulsification and strictly monitor the patient postoperatively to prevent and treat any spikes in IOP. After the cataract has been removed, I re-evaluate the eye's IOP and the structure and function of the optic nerve to set a new baseline and try to reach the desired target IOP with topical medical therapy. If the eye's IOP is not at the desired level despite medical therapy (a maximum of three medications as three eye drops in

24 hours), I plan a second-stage trabeculectomy with my standard wound-management technique. This way, both procedures are standard eye surgeries with predictable outcomes, and I do not need to change my surgical technique. Additionally, performing trabeculectomy is much easier in a pseudophakic eye with a deep anterior chamber.

CONCLUSION

We have learned that trabeculectomy leads to the progression of a cataract and a worsening of visual acuity (and therefore patients' quality of life), and that cataract surgery can complicate the control of IOP after trabeculectomy. Moreover, the IOP-lowering capability of combined surgery is inferior to that of trabeculectomy alone. In most cases, then, it is prudent to perform a staged procedure: cataract surgery alone (IOP control with topical ocular hypotensive therapy), establish a new baseline of IOP, verify the structure and function of the optic nerve, and then perform a second-stage trabeculectomy with standard wound-management techniques if required (if the target IOP was not reached with medical therapy or there is evidence of progression). ■

Tanuj Dada, MD, specializes in glaucoma and phacoemulsification at the RP Centre for Ophthalmic Sciences in the All India Institute of Medical Sciences in New Delhi, India. He acknowledged no financial interest in any product or company mentioned herein. Dr. Dada may be reached at phone: +91 98 733 36315; e-mail: tanujdada@gmail.com.

1. Ang GS, Shunmugam M, Azuara-Blanco A, et al. Effect of cataract extraction on the glaucoma progression index (GPI) in glaucoma patients. *J Glaucoma*. 2010;19(4):275-278.
2. Mwanza JC, Bhorade AM, Sekhon N, et al. Effect of cataract and its removal on signal strength and peripapillary retinal nerve fiber layer optical coherence tomography measurements. *J Glaucoma*. 2011;20(1):37-43.
3. Dada T, Behera G, Agarwal A, et al. Effect of cataract surgery on retinal nerve fiber layer thickness parameters using scanning laser polarimetry (GDxVCC). *Indian J Ophthalmol*. 2010;58(5):389-394.
4. Mitchell P, Smith W, Attebo K, Healey PR. Prevalence of open-angle glaucoma in Australia. The Blue Mountains Eye Study. *Ophthalmology*. 1999;106:2144-2153.
5. Shrivastava A, Singh K. The effect of cataract extraction on intraocular pressure. *Curr Opin Ophthalmol*. 2010;21(2):118-122.
6. Kanner EM, Netland PA, Sarkisian SR Jr, Du H. Ex-PRESS miniature glaucoma device implanted under a scleral flap alone or combined with phacoemulsification cataract surgery. *J Glaucoma*. 2009;18(6):488-491.
7. Jampel HD, Friedman DS, Lubomski LH, et al. Effect of technique on intraocular pressure after combined cataract and glaucoma surgery: an evidence-based review. *Ophthalmology*. 2002;109(12):2215-2224.

Surgical Management of Angle-Closure Glaucoma

Consider patient subgroups.

BY PRIN ROJANAPONGPUN, MD



For glaucoma specialists, the question of whether angle-closure glaucoma is a surgical disease is an important one, and in my opinion, the answer to this question is 'yes.'

Surgical options for angle-closure glaucoma are different than those for open-angle glaucoma and depend upon such factors as the extent of IOP control with medications and the presence of coexisting cataract. Our choice of surgical intervention needs to take these factors into account.

Eyes with angle-closure glaucoma progress from potential angle closure to angle closure with or without peripheral anterior synechiae (PAS), followed by an acute or chronic rise in IOP, and finally glaucomatous optic neuropathy (Figure 1). My colleagues and I are focused on this last stage of angle-closure glaucoma, which has already induced structural and functional changes of the optic disc.

CONSULTING THE GUIDELINES

The treatment guidelines for angle-closure glaucoma are derived through consensus by glaucoma experts based on the best available evidence. I helped to develop the Asia Pacific Glaucoma Guidelines.¹ When we released the second edition in 2008, the information on angle-closure glaucoma was incomplete, particularly regarding the surgical aspect of this disease. A more recent publication comes from the American Academy of Ophthalmology's *Preferred Practice Patterns*,² which was released in October 2010. These guidelines address the goals of managing a patient with primary angle-closure glaucoma:

- to reverse or prevent the angle-closure process
- to control IOP
- to prevent damage to the optic nerve

Iridotomy is indicated in all eyes with primary angle-closure glaucoma.

MANAGEMENT PRINCIPLES

The management of primary angle-closure glaucoma focuses on correcting the problem by modifying the angle-closure configurations, controlling IOP, and mini-

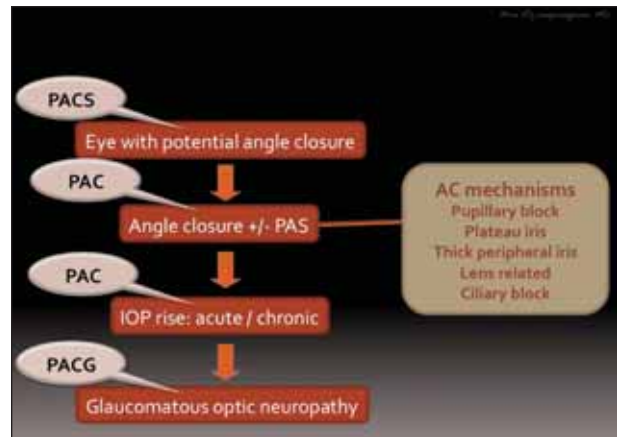


Figure 1. The angle-closure glaucoma cascade.

mizing changes in the optic disc and visual field (Figure 2). Options for correcting this condition generally include laser or surgical peripheral iridotomy, iridoplasty, topical pilocarpine, and removal of the crystalline lens. Unfortunately, according to a study published by Aung and colleagues,³ nearly 60% of primary angle-closure glaucoma patients demonstrate increased IOP and damage to the optic nerve head after successful laser peripheral iridotomy upon long-term follow-up. We may opt to use additional treatments such as laser iridoplasty or goniosynechialysis to reopen the angle after a peripheral iridotomy. Goniosynechialysis may improve aqueous outflow, particularly when it is performed within 6 months after an acute attack.

IS LENS REMOVAL NECESSARY?

We know that the crystalline lens contributes significantly to the mechanism of primary angle closure, particularly in the Asian population. Do we therefore need to remove the lens?

According to one series published by Sihota and colleagues,⁴ more than one-fourth (35%) of primary angle-closure glaucoma patients needed some kind of surgical intervention to control IOP at the 6-year follow-up. Although various surgical options are available, treatment for this condition is more complex than for open-angle

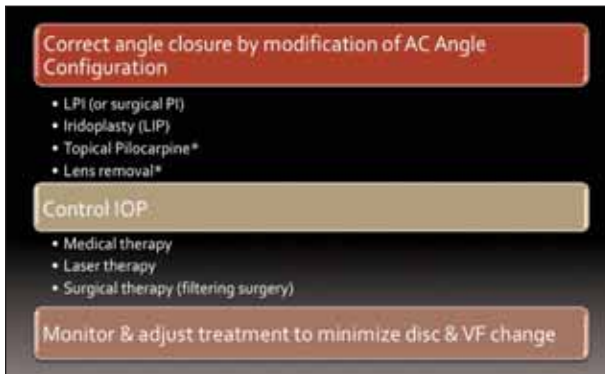


Figure 2. The author's basic principles for managing angle-closure glaucoma.

glaucoma, because the lens is involved. We must decide whether to remove the lens with or without performing goniosynechialysis or to do a combined surgery.

The outcomes of trabeculectomy to treat angle closure seem to be less favorable than for open-angle glaucoma, with a higher risk of filtration failure. Trabeculectomy also increases the chance of further shallowing of the anterior chamber, the risk of developing malignant glaucoma, and the risk of cataract formation. Although a study by Maris et al⁵ showed significantly lower complication rates with the EX-PRESS Glaucoma Filtration Device (Alcon Laboratories, Inc., Fort Worth, Texas) versus trabeculectomy in patients with primary open-angle glaucoma, and Kanner et al⁶ demonstrated similar complication rates between using the EX-PRESS device alone or in combination with phacoemulsification, experience with this approach in these patients is still limited and subject to potential future studies.

SUBCATEGORIZING PATIENT POPULATIONS

Deciding Between a Single or Combined Therapy

In terms of clinical approach, we can divide angle-closure glaucoma patients by those with coexisting cataract and those without. We can subcategorize these groups into individuals with medically controlled versus uncontrolled angle-closure glaucoma. Within these subcategories, we need to consider whether to simply perform phacoemulsification surgery or a combined phacoemulsification and trabeculectomy procedure.

Medically Controlled Angle-Closure Glaucoma With Cataract

A prospective, randomized trial conducted by Tham and colleagues in Hong Kong⁷ evaluated 35 eyes with medically controlled angle-closure glaucoma that underwent phacoemulsification alone and 37 eyes that had combined phacoemulsification and trabeculectomy surgery. The phacoemulsification-only group experienced a 9.82% reduction of IOP, and 59.2% decreased their use of medications.

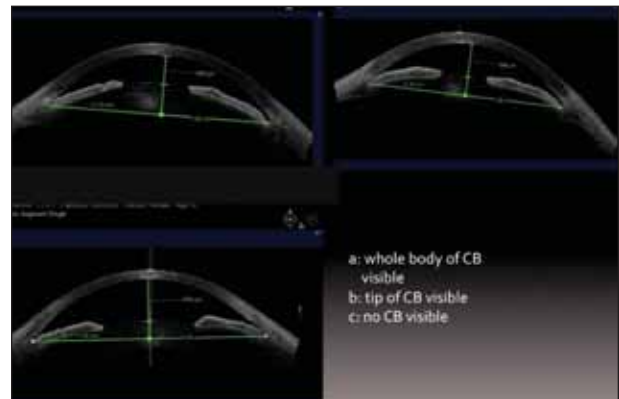


Figure 3. The lens mechanism in eyes with angle-closure glaucoma is difficult to assess.

Although the combined phacoemulsification and trabeculectomy procedure appeared to deliver slightly better results, this group also had significantly more complications. If we adjust for the seven reported cases of hypotony in the combined phacoemulsification and trabeculectomy group, the outcomes of the two groups are very similar. Thus, for patients with medically controlled angle-closure glaucoma and cataract, the benefit of combined phacoemulsification and trabeculectomy is not sufficient to justify the additional complications. For this reason, phacoemulsification alone may be indicated in such a group.

Uncontrolled Angle-Closure Glaucoma With Cataract

When considering the best procedure for medically uncontrolled angle-closure glaucoma with cataract, we can consult a smaller series of Tham's randomized trial.⁸ The study also found that combined phacoemulsification and trabeculectomy generated a greater IOP-lowering effect (1.97 mm Hg) than phacoemulsification alone, and the combination therapy enabled patients to reduce their medications. Again, however, combined phacoemulsification and trabeculectomy was found to produce significantly more complications, and I therefore recommend phaco surgery alone for patients who are at higher risk for trabeculectomy complications as well as for those who are not willing to accept the higher risk of complications. I would advise a combined procedure for patients with poor compliance, drug allergy, or a lack of access to drugs.

Angle-Closure Glaucoma in Eyes Without Cataract

In considering angle-closure glaucoma in eyes without cataracts, we can once again subdivide these patients into those whose condition is medically controlled or not. For medically controlled angle-closure glaucoma, I think it is fairly easy to maintain the medication regimen, unless the patient expresses a desire to discontinue it. For uncontrolled angle-closure glaucoma, I feel the current evidence is insufficient to correctly identify the lens

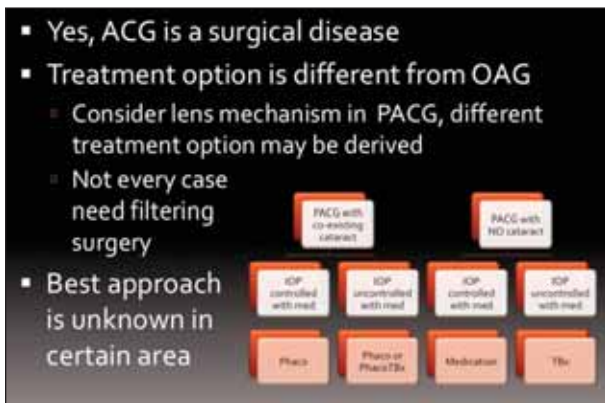


Figure 4. Conclusions.

mechanism. Therefore, I feel a reserved approach is warranted and that we must address this group similarly to eyes with primary open-angle glaucoma. Remember, cataract extraction alone may yield a substantial IOP reduction in selected angle-closure cases.

CONCLUSION

I think angle-closure glaucoma is indeed a surgical disease that has treatment options distinct from those used in primary open-angle glaucoma with coexisting cataract. If the IOP is controlled with medications, we can perform phacoemulsification alone; if not, then

combined phacoemulsification and trabeculectomy may be indicated. For angle-closure glaucoma patients without coexisting cataract, I advise continuing a regimen of medication as long as it can control the IOP. For uncontrolled angle-closure glaucoma without cataract, trabeculectomy may be a better option, and lens removal must be reserved for those eyes whose lens component can be correctly documented. ■

Prin Rojanapongpun, MD, is chairman of the Department of Ophthalmology at Chulalongkorn University, Bangkok, Thailand. He acknowledged no financial interest in the products or companies described herein. Dr. Rojanapongpun may be reached at phone: +(66) 2-256-4421; e-mail: prinoph@gmail.com.

1. South East Asia Glaucoma Interest Group. Asia Pacific Glaucoma Guidelines, 2nd ed. *Scientific Communications International*, 208:1-117.
2. Preferred Practice Patterns, Primary Angle Closure, American Academy of Ophthalmology, Oct. 2010.
3. Aung T, Ang LP, Chan SP, Chew PT. Acute primary angle closure: long term intraocular pressure outcome in Asian eyes. *Am J Ophthalmol*. 2001;131(1):7-12.
4. Sihota R, Sood A, Gupta V, et al. A prospective longterm study of primary chronic angle closure glaucoma. *Acta Ophthalmol Scand*. 2004;82(2):209-213.
5. Maris PJ Jr, Ishida K, Netland PA. Comparison of trabeculectomy with Ex-PRESS miniature glaucoma device implanted under scleral flap. *J Glaucoma*. 2007;16 (1):14-19.
6. Kanner EM, Netland PA, Sarkisian SR Jr, Du H. Ex-PRESS miniature glaucoma device implanted under a scleral flap alone or combined with phacoemulsification cataract surgery. *J Glaucoma*. 2009;18(6):488-491.
7. Tham CC, Kwong YY, Leung DY, et al. Phacoemulsification versus combined phacotrabeculectomy in medically controlled chronic angle closure glaucoma with cataract. *Ophthalmology*. 2008;115(12):2167-2173.
8. Tham CC, Kwong YY, Leung DY, et al. Phacoemulsification versus combined phacotrabeculectomy in medically uncontrolled chronic angle closure glaucoma with cataracts.

For international (Non-USA) use only. Not for distribution in the U.S.

Cataract & Refractive Surgery
EUROPE **TODAY**

EXP10582JSEU