

Phacoemulsification in the Vitrectomized Eye

Simple modifications to a small-incision technique can minimize surgical difficulty.

BY ARUP CHAKRABARTI, MS

Cataract formation is one of the most common complications of pars plana vitrectomy (PPV), with rates varying from 12.5% to 80.0% reported in the literature.¹⁻⁷ Because the indications for PPV are expanding and new surgical techniques have improved postoperative results, the number of patients undergoing PPV is on the rise. However, because vitrectomized eyes are anatomically different from unoperated eyes, they are at increased risk for intra- and postoperative complications.

For these reasons, retinal surgeons are especially careful performing PPV in older patients,^{7,8} in those with a high degree of preoperative nuclear sclerosis⁹ or diabetic retinopathy,² and in eyes in which silicone oil injection was previously performed,¹⁰ as all are risk factors for the development or progression of cataract. Cataract formation can also result after lens touch with intraocular instruments, in response to the introduction of intraocular tamponading agents such as silicone oil and gas, and if crystallization on the anterior hyaloid or posterior capsule results in posterior capsular lens feathering and inflammation. The latter can lead to free radical release in the posterior segment.

RISE TO THE CHALLENGE

Vitrectomized patients account for some of the most challenging cataract surgery cases. They present higher risks for complications due to residual effects of previous surgery, inflammation, and associated comorbidities; have an increased likelihood for denser cataract; and lack the physical support of the vitreous gel. Several pre-, intra-, and postoperative considerations can help surgeons achieve successful outcomes in these difficult cases.

A detailed patient history including the nature of the vitreoretinal pathology and extent of previous surgery are mandatory to alert the surgeon to potential dangers or complications that can occur during phacoemulsification. Preoperative examination should be performed with an indirect ophthalmoscope whenever possible;

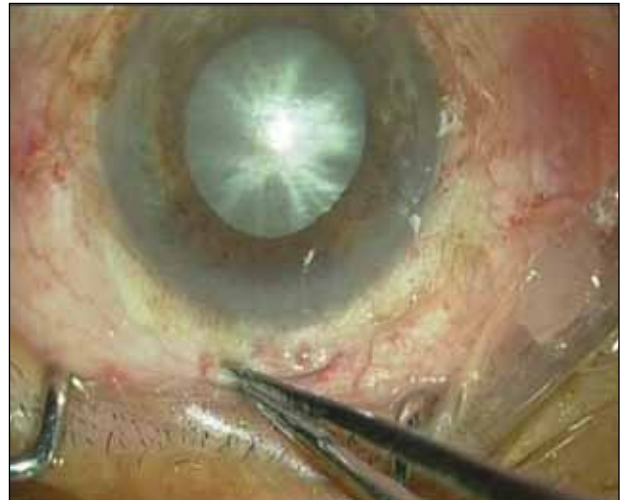

Figure 1. Conjunctival scarring can be seen in this eye.

however, in the case of an advanced cataract it may be necessary to rely on B-scan ultrasound imaging.

Paying special attention to any signs of compromised ocular health, structural changes resulting from trauma of the previous surgery, and complaints of poor visual quality can help the surgeon to formulate the best surgical strategy and achieve the best visual outcome for the patient. Signs can include the presence of conjunctival and episcleral scarring, low endothelial cell count, a deep anterior chamber with or without the presence of emulsified silicone oil bubbles, iridophacodonesis indicating compromised zonules, poor pupillary status and integrity of the macula, and presence of open retinal breaks. The most notable of these factors to consider before attempting phacoemulsification are described below.

Factor No. 1: Conjunctival scarring. Dissection of the conjunctiva for a scleral tunnel is especially difficult in the presence of conjunctival scarring (Figure 1). Creating the tunnel becomes even more challenging if the patient has previously undergone a scleral buckling procedure, as

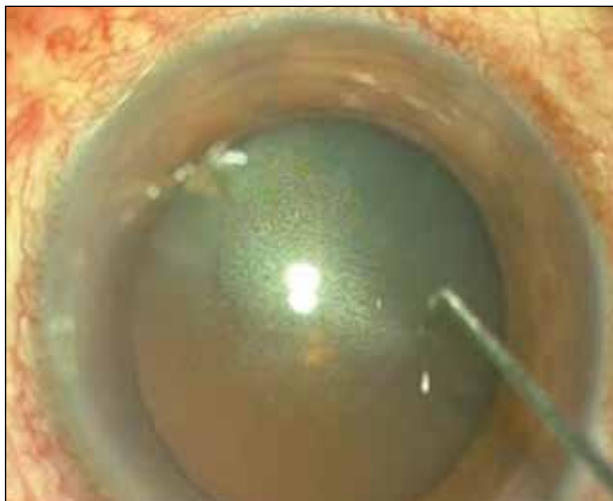

Figure 2. Silicone oil is seen in the anterior chamber.

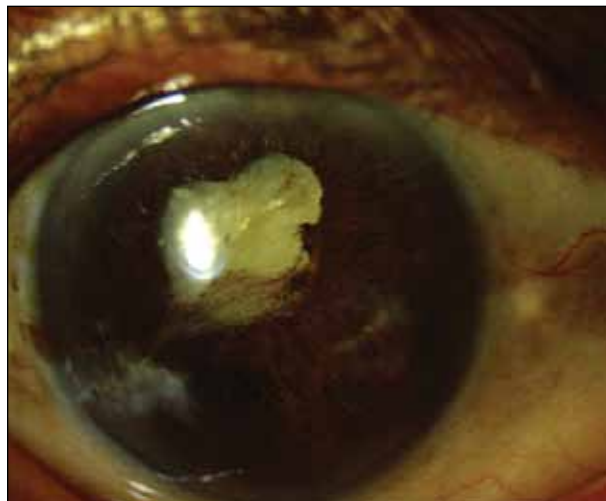

Figure 3. This eye shows poor pupil dilatation.

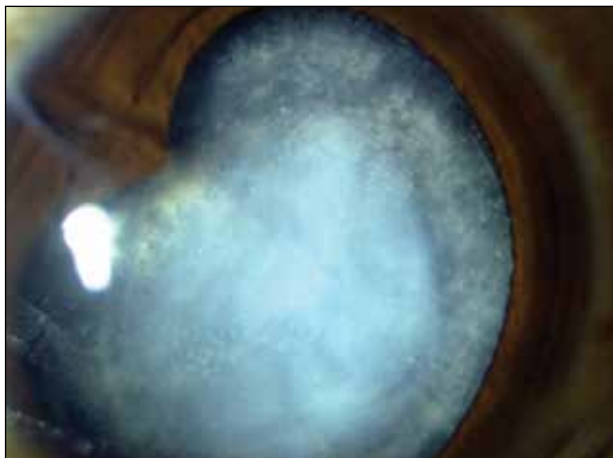


Figure 4. A posterior capsular dehiscence is identified.

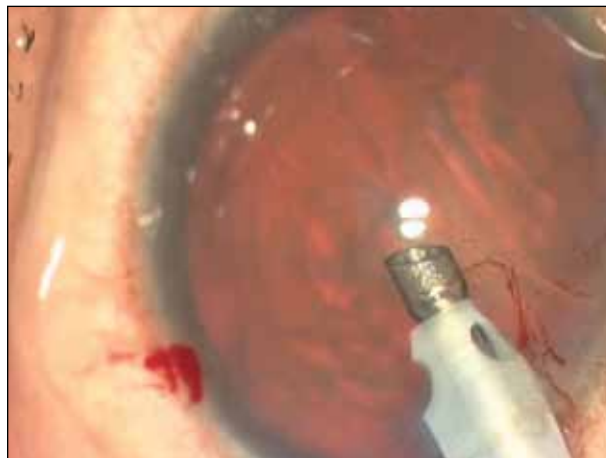


Figure 5. Increased lens-iris diaphragm retropulsion is noted in this eye.

scarring around the bridled extraocular muscle can make exposure difficult or insufficient. Because increased episcleral scarring and bleeding are common in these patients, it is wisest to perform phacoemulsification through a clear corneal incision rather than a scleral tunnel. If a rigid IOL is implanted thereafter, enlargement of the incision and suturing the lens to the bag may be required.

Factor No. 2: Compromised corneal endothelium. After PPV—particularly when silicone oil is present in the anterior chamber (Figure 2)—the corneal endothelium is often compromised, with resulting endothelial cell loss and corneal edema.

Factor No. 3: Poor pupillary dilation. Even instillation of mydriatics prior to cataract surgery fails to dilate post-vitrectomy eyes in some cases (Figure 3). Strategies for addressing small pupils are detailed below (Factor No. 8, under the heading *Intraoperative Considerations: Surgical Strategy*).

Factor No. 4: Zonular weakness and preexisting posterior capsular rent. A lengthy vitreoretinal procedure, the need for multiple surgeries, and vitrectomy involving vitreous base dissection can increase the risk for zonular weakness, a loose capsular bag, and posterior capsular dehiscence in vitrectomized eyes (Figure 4). An eye that has undergone limited vitrectomy and has an untouched clear anterior vitreous cortex will likely fare better than an eye with complex vitreoretinal pathology that has undergone multiple procedures involving anterior vitreous base excision.

Factor No. 5: Low scleral rigidity. Placement of a Flieringa ring and chamber-maintaining infusion are useful strategies for providing additional capsular support in eyes with low scleral rigidity. This situation is more common in vitrectomized eyes, especially in those with myopia.

TABLE 1. FORMULA TO CORRECT AXIAL LENGTH IN EYES WITH SILICONE OIL

$$\text{VCD1532}^* = \text{AL} - (\text{ACD} + \text{lens})$$

$\text{VCD}_{\text{corrected}} = \text{VCD1532} \times (1/1532) \times 980 \text{ m/s}$
(for 1,000 cSt silicone oil; for 5,000 cSt silicone oil, use 1,040 m/s)

$$\text{AL}_{\text{corrected}} = \text{VCD}_{\text{corrected}} + \text{ACD} + \text{lens}$$

*1532 is the average velocity of sound in aqueous and vitreous

VCD = vitreous cavity depth; AL = axial length;
ACD = anterior chamber depth; cSt = centistoke

Factor No. 6: Cystoid macular edema (CME) and diabetic retinopathy. CME and worsening of preexisting diabetic retinopathy are commonly associated with vitrectomy, and stringent follow-up is essential to detect the exacerbation of diabetic retinopathy symptoms at their earliest manifestation. Additional considerations include performing surgery only after diabetic retinopathy is under control and prescribing preoperative topical NSAID drops prior to surgery in eyes with CME.¹¹

Factor No. 7: Lens-iris diaphragm retropulsion. Eyes that have previously undergone vitrectomy are more likely to experience lens-iris diaphragm retropulsion syndrome, especially if a small-incision phacoemulsification technique is employed (Figure 5).¹² Infusion deviation syndrome is also more likely to develop in these eyes.¹³

OTHER PREOPERATIVE CONSIDERATIONS

Calculation of axial length. The presence of silicone oil in the vitreous can appear to increase axial length and alter the eye's optics. Before the surgeon can calculate the correct IOL power, he or she must convert the apparent axial length to a true measurement. The viscosity of silicone oils vary from 1,000 to 5,000 centistoke (cSt) and, in general, the higher the viscosity, the higher the change in refraction and axial length.^{14,15} According to Sharma et al,¹⁶ correcting the axial length induced by silicone oil with a viscosity of 1,300 cSt can be accomplished by multiplying the measured axial length by a conversion factor of 0.71. The formula to correct axial length in any eye with silicone oil is detailed in Table 1.

In an eye with silicone oil that has an early cataract not impairing fundus examination, partial coherence interferometry with the IOLMaster (Carl Zeiss Meditec) is preferred over ultrasonography to calculate axial length. If the axial length measurement cannot be determined, the

TABLE 2. CALCULATING ADDITIONAL IOL POWER IN EYES WITH SILICONE OIL

$$\text{Additional IOL power} = \{(\text{Ns}-\text{Nv}) / (\text{AL}-\text{ACD})\} \times 1,000$$

Ns = refractive index of silicone oil (1.4034)

Nv = refractive index of vitreous (1.336)

AL = axial length

ACD = anterior chamber depth

axial length measurement from before vitreoretinal surgery and silicone oil injection or after silicone oil removal can be used; alternatively, axial length can be measured in the fellow eye. In eyes with incomplete silicone oil fill, computed tomography images can be used to measure axial length. If these methods fail, a final option is to use a standard-power IOL.

Calculation of IOL power. Because the index of refraction of silicone oil (1.405) is higher than that of the vitreous gel, this optic medium behaves like an intraocular minus lens. When the IOL power is not adjusted to account for this difference, standard theoretical and regression lens power formulas predict a lens power that is less than needed to achieve emmetropia. The result is significant postoperative hyperopic refractive error. As a rule of thumb, the more power incorporated into the posterior surface of the chosen IOL, the greater the postoperative error.

When silicone oil is left in the eye during phacoemulsification and IOL implantation, the surgeon should add between 3.00 and 8.00 D to the calculated IOL power, with the exact amount depending on the specific lens shape. With a convex-plano IOL, add 3.00 D to the calculated IOL power; with a biconvex lens, add 6.00 D. Patients who will have the silicone oil removed at a later date should be warned about the possibility of a myopic shift of 2.00 to 5.00 D. The shift will be greater for an eye with a biconvex lens than for an eye with a planoconvex lens with a posteriorly facing planar surface; the smallest change occurs in eyes with posterior-meniscus IOLs. A suggested modified IOL power calculation formula to find the additional IOL power needed for silicone-oil-filled eyes is detailed in Table 2.

IOL choice. In post-PPV eyes, hydrophobic and hydrophilic acrylic IOLs can have successful outcomes. Rigid PMMA IOLs may also be considered; however, silicone IOLs should never be implanted in vitrectomized eyes. This is also true for IOLs with a one-piece plate haptic design and those with small and ovoid optics. Lenses with a 360° square-edge design and an optic diameter of 6.0 to 6.5 mm provide greater area of fundus visualization and, therefore, are preferable for patients with retinal pathology.

TABLE 3. INTRAOPERATIVE COMPLICATIONS AND REPORTED FREQUENCIES¹⁷

Location	Pathology	Incidence
Cornea	Peripheral corneal injury	2.3%
	Stripped Descemet membrane	2.3%
Anterior chamber	Fluctuations in anterior chamber depth	4.5%
Iris	Iris prolapse	0.0%
	Miotic pupil	0.0%
Lens	Tears in the rhexis margin	4.5%
	Marked zonular laxity/dehiscence	4.5%
	Posterior capsular plaque	22.7%
	Unplanned posterior capsulorrhexis	6.8%
	Posterior capsular rupture	2.3%
	Unplanned anterior chamber IOL	2.3%
Posterior segment	Nuclear drop/dropped lens fragment	2.3%
	Suprachoroidal hemorrhage	2.3%
Other	Conversion from topical to intracameral anesthesia	2.3%

INTRAOPERATIVE CONSIDERATIONS: SURGICAL STRATEGY

Visual outcomes after phacoemulsification can be compromised by intraoperative complications involving the cornea, anterior chamber, iris, lens, or posterior segment (Table 3).¹⁷ Potential complicating factors include ocular hypotony, deep anterior chamber, disturbed vitreous dynamics, compromised zonules, poor pupillary dilation, loose capsular bag, posterior capsular rent or plaque, dropped nuclear fragments, and infusion deviation syndrome. The following surgical factors can be used to help minimize occurrence of complications, and a video demonstration of phacoemulsification in a vitrectomized eye can be viewed at eyetube.net/?v=bumun.



Factor No. 1: NSAIDs. Patients should begin taking long-acting cycloplegic and NSAID drops 1 week before surgery to help maintain adequate mydriasis during the procedure.

Factor No. 2: Anesthesia. Intracameral nonpreserved lidocaine is preferable in eyes with hard cataracts and associated comorbidities including subluxated cataract and small pupils, to avoid discomfort due to stretching

maneuvers. This form of injectable anesthesia increases orbital volume, potentially negating vitreous pressure and reducing the deepening of the anterior chamber.

Factor No. 3: Incisions. Whenever possible, a clear corneal incision is preferred to a scleral tunnel, unless the patient opts for a rigid IOL or if the surgeon is worried that he or she will have to convert to a large-incision, nonphaco technique. If the zonular apparatus appears compromised, creating the incision opposite to the area of zonular dialysis is ideal. Carefully fashioning the phaco and sideport incisions can avoid fluid leakage. Fluid dynamics is crucial in these eyes.

If conjunctival scarring is present, dissection of a fornix-based flap can be difficult. In these cases, the flap should be anchored at the periphery at the conclusion of the procedure.

Factor No. 4: Capsulorrhexis. Staining the anterior capsule with trypan blue dye is helpful to enhance visibility for capsulorrhexis creation, which can be a challenging step because of the increased prevalence of anterior capsular fibrosis after vitrectomy and because posterior segment pathologies can compromise the red fundus reflex.

Capsulorrhexis creation can be completed with a sharp cystotome, but it is also helpful to have a pair of microrhexis forceps and scissors close by, using them when needed to cut any fibrotic areas (Figure 6). Injection of an ophthalmic

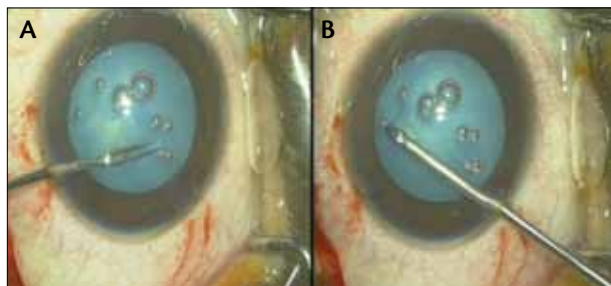


Figure 6. Microrhexis scissors are used to excise a fibrotic anterior capsular rent (A) and to complete the rhexis in the presence of anterior capsular fibrosis (B).

viscosurgical device (OVD) should be done carefully, so as not to excessively deepen the anterior chamber.

The capsulorrhexis should be large—between 5.0 and 5.5 mm—to facilitate phacoemulsification and reduce the incidence of posterior capsular opacification and capsular phimosis. This also promotes adequate fundus visualization during subsequent follow-up visits.

Factor No. 5: Hydrodissection. Because of the risk for posterior capsular rent, hydrodissection should be slow and gentle and interrupted by frequent decompression. Adequate nuclear rotation should be ensured to prevent further stress on the capsulozonular apparatus, which is already compromised in post-PPV eyes. In eyes with white cataract, because of the risk for lens touch and occult capsular rupture, gentle hydrodelineation or hydro-free dissection can be used in place of hydrodissection.

Factor No. 6: Phacoemulsification. As with any case, phacoemulsification should be performed as atraumatically as possible in postvitrectomy eyes. In many cases, these eyes have denser nuclei than typical age-related cataract, requiring more time for phacoemulsification. The best technique depends on the surgeon's experience and comfort level. I use direct phaco chop, but stop-and-chop or divide-and-conquer techniques are also appropriate choices. Whatever method is chosen, a general rule of thumb is to avoid applying excessive force to the lens during emulsification.

Fluctuating anterior chamber depth, caused by increased movement of the lens-iris diaphragm, is likely to occur in vitrectomized eyes, especially if the anterior vitreous cortex has been removed. One strategy to avoid excessive fluctuations is to use a low bottle height and maintain irrigation whenever the phaco or I/A probes are in the eye. Another effective strategy would be to introduce the phaco handpiece in a dry manner, switching the irrigation on only after the pupillary margin is elevated off the anterior capsular surface with a cyclodialysis spatula working through a paracentesis. This strategy avoids a reverse pupillary block by preventing the build-

up of a pressure gradient in the anterior chamber and prevents excessive deepening of the anterior chamber.

Vitrectomized eyes are also at risk for infusion deviation syndrome, in which fluid migrates posteriorly through the weakened zonules and increases the volume of the vitreous compartment, shallowing the anterior chamber. Raising the infusion bottle has the paradoxical effect of further shallowing the anterior chamber and should be avoided.

Factor No. 7: Cortical clean-up. Using a bimanual approach with low I/A parameters and circumferential stripping for cortical clean-up can reduce zonular stress. Gently polishing the posterior capsule can reduce the incidence of postoperative posterior capsular opacification.

Factor No. 8: Small pupil strategy. If preoperative long-acting cycloplegic drops do not result in adequate mydriasis, a stepwise approach to small pupil management that minimizes ocular manipulation is best. Intraoperative pupil-expansion steps can include posterior synechiolysis, viscomydrisis, pupillary membrane dissection, stretch pupilloplasty, and iris hooks. The Malyugin Ring (MicroSurgical Technology, Inc.) is another option.

Factor No. 9: Dense posterior capsular plaques. One side effect of silicone oil injection is marked posterior capsular fibrosis and plaque (Figure 7). Any centrally located plaques are likely visually significant and should be removed with capsular polishing or dissection with a 26-gauge needle. Utrata forceps are adequate to peel off the edges in most cases; however, very dense plaques may require extra attention. Often, dense plaques can be managed by including them in a primary posterior capsulorrhexis.

Factor No. 10: IOL implantation. Placement of the IOL must be gentle. Ideally, excessive rotational maneuvers should be avoided and the lens implanted in a position that ensures long-term fixation and stability. Optimum posterior segment visualization is key in eyes with retinal pathology. In the presence of zonular dialysis, a capsular tension ring can be implanted prior to lens implantation to create even distension of the capsular bag. The IOL should then be implanted with one haptic oriented in the direction of the dehiscence.

Finally, re-formation of the anterior chamber and a watertight incision can prevent hypotony. Note that these altered eyes, with low scleral rigidity and perilimbal scarring, may require sutures to close the phaco and sideport incisions.

POSTOPERATIVE CONSIDERATIONS: COMPLICATIONS MANAGEMENT

The best way to prevent postoperative complications such as CME, worsening of diabetic retinopathy, inflammation, secondary glaucoma, and posterior synechiae is to adhere to a rigorous follow-up schedule. Prescribing topical steroid, NSAID, and cycloplegic drops is manda-

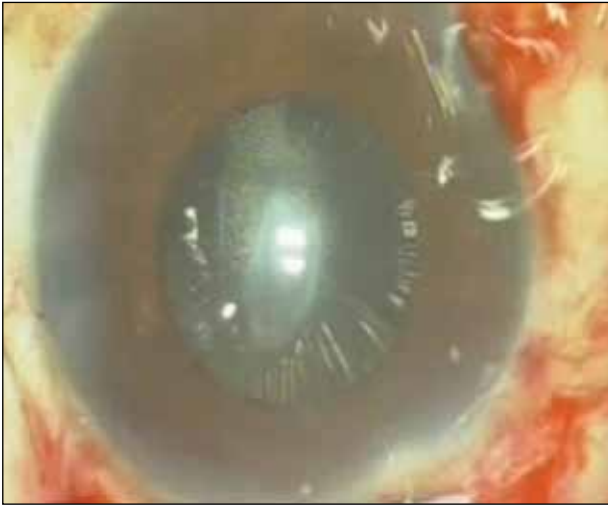


Figure 7. Posterior capsular plaque is seen in this eye.

tory, and frequent follow-up is advised. Subconjunctival injection of mydriatic agents and steroids can be considered in eyes with uncontrolled intraocular inflammation, and intracameral injection of tissue plasminogen activator can be used to manage postoperative fibrin.

Factor No. 1: Early postoperative complications. In the first postoperative week, complications can include blepharoptosis, moderate to severe corneal edema, intraocular pressure spike, wound leak, peaked pupil with vitreous in the wound, moderate to severe iritis or iris prolapse, incorrect IOL power, IOL decentration or dislocation, endophthalmitis, macular phototoxicity, retinal detachment, and vitreous hemorrhage.

Factor No. 2: Late postoperative complications. In the anterior segment, late complications can include blepharoptosis, moderate to severe corneal edema, pseudophakic bullous keratopathy, chronic iritis, irregular pupil, neovascularization of the iris, capsulorhexis contraction, IOL decentration, and posterior capsular opacification. Complications in the posterior segment can include new or persistent macular edema, persistent recurrent choroidal neovascular membrane, proliferative diabetic retinopathy, reopened macular hole, retinal detachment, visually significant epiretinal membrane, and vitreous hemorrhage.

CONCLUSION

The physiologic state of vitrectomized eyes is different from that of eyes presenting with age-related cataracts. Therefore, cataract surgery in these cases is more challenging and requires careful consideration of multiple factors during the pre-, intra-, and postoperative periods. The surgeon should always consider the nature of the patient's previous vitreoretinal pathology when planning

TAKE-HOME MESSAGE

- A detailed patient history including the nature of the vitreoretinal pathology and extent of previous surgery are mandatory to alert the surgeon to potential dangers or complications that can occur during phacoemulsification.
- Signs of compromised ocular health include the presence of conjunctival and episcleral scarring, low endothelial cell count, a deep anterior chamber, iridophacodonesis, poor pupillary status and integrity of the macula, and presence of open retinal breaks.
- Adherence to the guidelines outlined in this article ensures minimization of intraoperative difficulties and postoperative complications.

surgery and, when possible, undertake a modified small-incision phacoemulsification technique using the factors described above. Adherence to the guidelines given above ensures minimization of intraoperative difficulties and postoperative complications. ■

Arup Chakrabarti, MS, is in private practice at Chakrabarti Eye Care Centre, Cataract and Glaucoma Services, in Kerala, India. Dr. Chakrabarti states that he has no financial interest in the products or companies mentioned. He may be reached at tel: +91 471 2555530/2449599; fax: +91 471 2558530; e-mail: arupeye@gmail.com.

1. Novack MA, Rice TA, Michels RG, et al. The crystalline lens after vitrectomy for diabetic retinopathy. *Ophthalmology*. 1984;91:1480-1484.
2. Blakenship GW, Machermer R. Long term diabetic vitrectomy results. Report of 10 year follow-up. *Ophthalmology*. 1985;92:503-506.
3. Margherio RR, Cox MS, Trese MT, et al. Removal of epiretinal membranes. *Ophthalmology*. 1985;92:1075-1083.
4. deBustros S, Thompson JT, Michels RG, et al. Nuclear sclerosis after vitrectomy for epiretinal membranes. *Am J Ophthalmol*. 1988;105:160-164.
5. Cherfan GM, Michels RG, de Bustros S, et al. Nuclear sclerotic cataract after vitrectomy for idiopathic epiretinal membranes causing macular pucker. *Am J Ophthalmol*. 1991;111:434-438.
6. Thompson JT, Glaser BM, Sjaarda RN, et al. Progression of nuclear sclerosis and long-term visual results of vitrectomy with transforming growth factor beta-2 for macular holes. *Am J Ophthalmol*. 1995;119:48-54.
7. Melberg NS, Thomas MA. Nuclear sclerotic cataract after vitrectomy for patients younger than 50 years. *Ophthalmology*. 1995;102:1466-1471.
8. Ogura Y, Takanashi T, Ishigooka H, Ogino, N. Quantitative analysis of lens changes after vitrectomy by fluorophotometry. *Am J Ophthalmol*. 1991;111:179-183.
9. de Bustros S, Thompson JT, Michels RG, Enger C, Rice TA, Glaser BM. Nuclear sclerosis after vitrectomy for idiopathic ERMs. *Am J Ophthalmol*. 1988;105:160-164.
10. Lucke KH, Foerster MH, Laqua H. Long-term results of vitrectomy and silicone oil in 500 cases of complicated retinal detachments. *Am J Ophthalmol*. 1987;104:624-633.
11. Miyake K. The significance of inflammatory reaction following cataract surgery and IOL implantation. *J Cataract Refract Surg*. 1996;22(Suppl):759-868.
12. Cionni RJ, Barros MG, Osher RH. Management of lens-diaphragm retropulsion syndrome during phacoemulsification. *J Cataract Refract Surg*. 2004;30(5):953-956.
13. Nichamin LD. Phacoemulsification following vitreoretinal surgery. In: *Cataract Surgery in Complicated Cases*. Burrato L, ed. Thorofore, NJ: Slack Inc.; 2000:268-270.
14. Shammash HJ. *IOL Power Calculation*. Avoiding errors. Glendale; New Circle Publishing House; 1996.
15. Seo MS, Lim ST, Kim HD, Park BI. Changes in refraction and axial length according to the viscosity of intraocular silicone oil. *Korean J Ophthalmol*. 1999;13(1):25-29.
16. Sharma NP, Pal N, Vardhan Azad R, Vajpayee RB. Phacoemulsification in eyes following vitreoretinal surgery. In: *Phacoemulsification Surgery*. New Delhi; Jaypee Brothers; 2005;343-347.
17. Grusha YO, Masket S, Miller K, et al. Phacoemulsification and lens implantation after pars plana vitrectomy. *Ophthalmology*. 1998;105:287-294.