

# ADVANCES IN CORNEAL INLAY IMPLANTATION OVER THE YEARS

Changes in technique have a direct correlation with decreases in a corneal inlay's removal rate.

BY MINORU TOMITA MD, PhD



Having implanted more than 13,000 Kamra corneal inlays (AcuFocus) in the past 5 years, my experience with this technology accounts for about 80% of all international cases. Given these facts, it is fair to say that I have helped to refine not only the technique for implantation but also the technology itself. With such a vested interest in the Kamra corneal inlay, I was excited to hear of its recent approval by the FDA. In my opinion, the Kamra affords patients improvements in near and intermediate visual acuity, better contrast sensitivity than an accommodating or diffractive multifocal IOL,<sup>1</sup> and minimal compromise to distance vision.

## METHODS OF IMPLANTATION

I began using the Kamra during my time as the executive medical director at Shinagawa LASIK Center in Tokyo, and I continue to use the device now that I am in private practice at the Minoru Tomita Eye Clinic Ginza. In my early experience, the inlay was implanted using a technique that the company called *combined LASIK-Kamra* (CLK), whereby the inlay was implanted simultaneously with LASIK under a 200- $\mu$ m lamellar flap. CLK was subsequently abandoned, as operating under a thick flap proved to have obvious disadvantages for patients (induction of dry eye, slow visual recovery) and surgeons (difficulty centering the inlay for implantation, extensive postoperative management). Furthermore, AcuFocus global registry data showed that the incidence of a wound-healing response was 17% with the CLK technique (data on file with AcuFocus), and my explantation rate in nearly 4,000 cases was approximately 5%. I found that the reasons for removal included patients' dissatisfaction with their vision and/or failure to adapt to their vision with the inlay.

Today, the inlay is implanted into a lamellar pocket at or deeper than 200  $\mu$ m, and, in 90% of cases, the device is combined with LASIK using a dual-interface technique. In this approach, the excimer laser correction is performed under a

thin flap, and the inlay is implanted at least 100  $\mu$ m below the LASIK interface, inside a corneal pocket. The pocket is created with a femtosecond laser using a spot/line separation of 6 X 6 (or the equivalent) because my fellow investigators and I have concluded that this produces smoother beds and better post-operative outcomes than other spot/line separations.

I have implanted about 9,000 corneal inlays with the corneal pocket technique, and my overall explantation rate is somewhere between 1% and 2% within 3 years of implantation (see *Retrospective Analysis of Inlay Removal* and *FDA Clinical Trial Data on Reasons for Explantation*). In a recent study of 223 eyes undergoing the corneal pocket procedure, the mean near UCVA improved by 4 lines, from J8 preoperatively to J2 at 6 months postoperatively ( $P < .001$ ), and patients' spectacle dependence and satisfaction with spectacle-free reading improved significantly.<sup>2</sup>

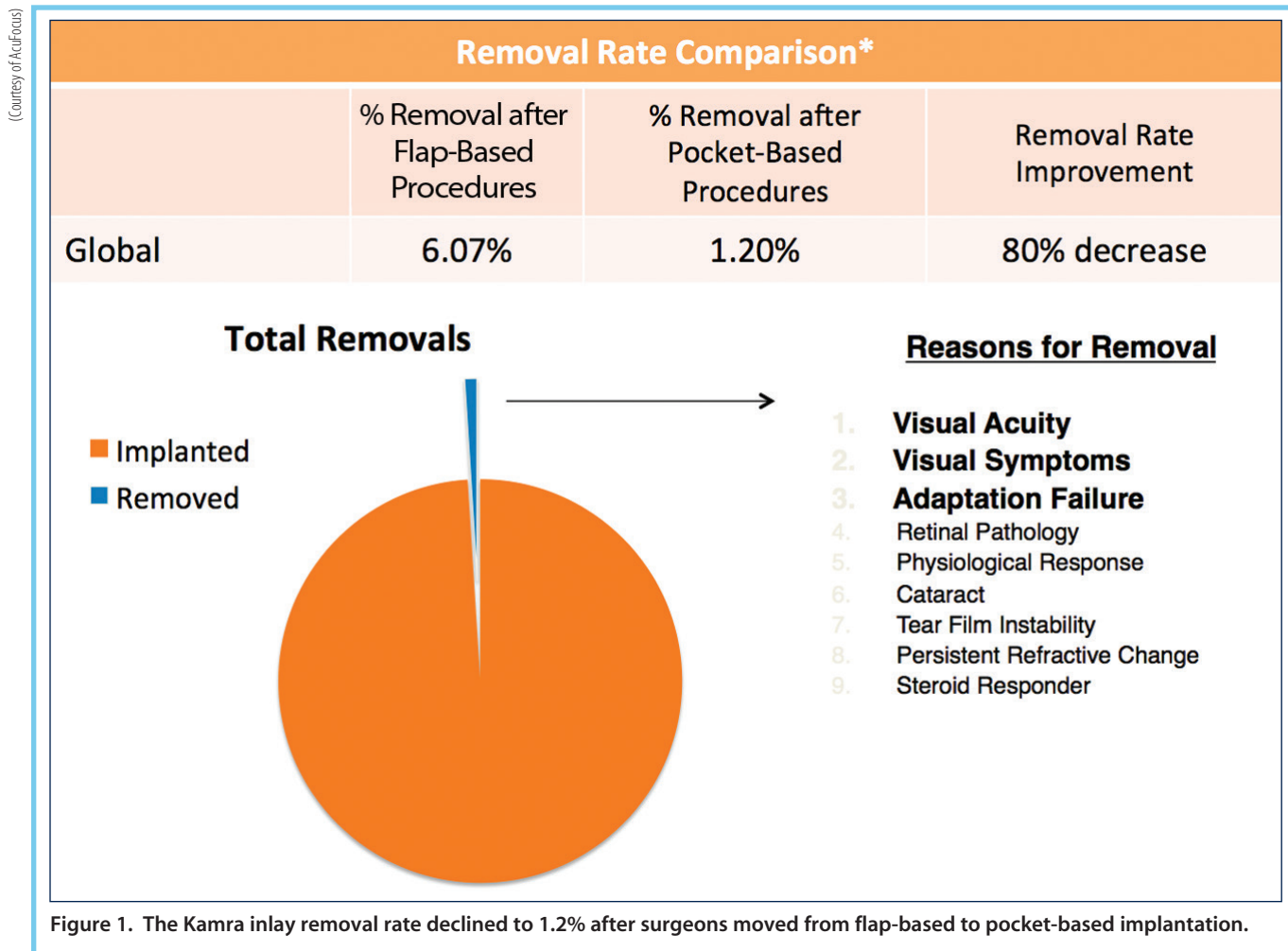
The advantages a dual-interface technique include the ability to fine-tune patients' refractions and to capitalize on the advantages of thin-flap LASIK and deep-pocket corneal inlay implantation. With that said, some patients (4%) still

(Continued on page 32)



## AT A GLANCE

- Initially, corneal inlay implantation was performed simultaneously with LASIK under a 200- $\mu$ m lamellar flap. The combined LASIK-Kamra technique was subsequently abandoned, as operating under a thick flap proved to have obvious disadvantages for patients and surgeons.
- Today, the inlay is implanted into a lamellar pocket at or deeper than 200  $\mu$ m and is typically combined with LASIK using a dual-interface technique.
- The advantages a dual-interface technique include the ability to fine-tune patients' refractions and to capitalize on the advantages of thin-flap LASIK and deep-pocket corneal inlay implantation.



## RETROSPECTIVE ANALYSIS OF INLAY REMOVAL

By **Laura Straub, Editor-in-Chief**

A retrospective review of visual recovery following removal of the Kamra corneal inlay (AcuFocus) indicated that most patients recovered their distance and near visual acuities to preinlay levels within 6 months of explantation.<sup>1</sup>

Srividhya Vilupuru, MD, and Minoru Tomita, MD, PhD, followed 63 patients who had their inlays removed within 12 months ( $11.3 \pm 7.4$  months) of the initial procedure. By 6 months after inlay removal, mean distance UCVA was 0.08 logMAR ( $\pm 0.22$  standard deviation [SD]), compared with 0.13 logMAR ( $\pm 0.26$  SD) prerule, and mean near

UCVA was 0.41 logMAR ( $\pm 0.30$  SD), compared with 0.33 ( $\pm 0.25$  SD) prerule ( $P=.37$  and  $.21$ , respectively). Also by 6 months, distance BCVA recovered to preinlay levels in all but two patients, who each lost 1 line. Furthermore, the manifest refraction spherical equivalent was  $-0.18 \pm 0.78$  D at 6 months postremoval, compared with  $-0.54 \pm 0.27$  D prerule.

Drs. Vilupuru and Tomita also reported that both UCVA and BCVA had recovered within 1 month and stabilized within 3 months of inlay removal.

1. Vilupuru S, Tomita M. Visual recovery following removal of small aperture intracorneal inlay. Poster presented at: the ARVO Annual Meeting; May 4-8, 2014; Orlando, Florida.

## FDA Clinical Trial Data on Reasons for Explantation

Through 60 months, 45 of 508 patients elected to have the Kamra corneal inlay removed.\*

**4.4%**

Appearance of the inlay in situ

**8.9%**

Medical indication

- Folds in inlay at the time of implantation (2.2%)
- Stromal thinning due to foreign body, trauma (2.2%)
- Posterior vitreous detachment (large floater in eye; 2.2%)
- Sustained loss of vision due to scar in visual axis (2.2%)

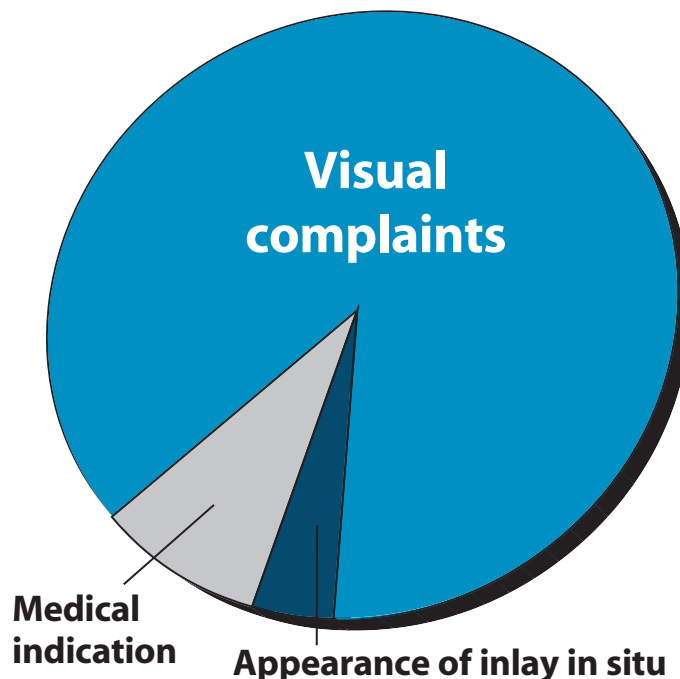
**86.7%**

Visual complaints

- Hyperopic shift (55.6%)
- Myopic shift (4.4%)
- Induced astigmatism (2.2%)
- Inadequate benefit/inability to adapt (15.6%)
- Inlay not centered (4.4%)
- Inlay placed in dominant eye (2.2%)

\* All but one patient in the study had 20/20 or better distance BCVA after inlay removal; the one patient who had 20/25 distance BCVA after removal had a small corneal scar.

Source: AcuFocus



(Continued from page 30)

experience an aggressive wound-healing response characterized by stromal thickening over the inlay, central flattening, the development of haze over the inlay annulus, and a hyperopic shift after inlay implantation with a corneal pocket technique. In the vast majority of these patients, however, the wound-healing response can be resolved with steroid therapy.<sup>3</sup> Inlay explantation should be considered if the eye either does not respond to steroids or rebounds after treatment.

### REMOVAL RATE

As previously mentioned, my removal rate with the Kamra corneal inlay decreased from 5% with the CLK technique to between 1% and 2% with pocket implantation. This closely reflects data from the AcuFocus global registry (6% with CLK and 1.2% with pocket implantation; Figure 1). These removal rates are comparable to the reversal rate of monovision<sup>4,5</sup> and approach the rate of IOL exchange.<sup>6</sup>

For this reason, and because of the advantages of pocket implantation outlined earlier, the AcuFocus Global Medical Advisory Board now recommends that the Kamra always be implanted in a corneal pocket.

### OVERALL EXPERIENCE

Although a small percentage of patients experience a hyperopic shift postoperatively, in general, presbyopes who are

motivated to achieve spectacle independence do well with the Kamra corneal inlay implanted in their nondominant eye. Compared with the other available corneal inlays, I believe that the Kamra is the best option for my patients. This is mainly because the Kamra is the only technology that can maintain a distance visual acuity of 20/20 and provide patients with near and intermediate visual acuity in the range of J1 to J2 (personal experience). Additionally, surgical complications are rare and have decreased with advances in implantation technique.<sup>7,8</sup> ■

1. Pepose J. Comparison of depth of focus and mesopic contrast sensitivity in small-aperture inlay, accommodating IOL, and multifocal IOL patients. Poster presented at: The 2014 ASCRS/ASOA Symposium & Congress; April 25–29, 2014; Boston, MA.
2. Tomita M, Kanamori T, Waring GO IV, et al. Small-aperture corneal inlay implantation to treat presbyopia after laser in situ keratomileusis. *J Cataract Refract Surg*. 2013;39(6):898–905.
3. Dexl AK, Jell G, Strohmaier C, et al. Long-term outcomes after monocular corneal inlay implantation for the surgical compensation of presbyopia. *J Cataract Refract Surg*. 2015;41:566–575.
4. Reilly CD, Lee WB, Alvarenga L, et al. Surgical monovision and monovision reversal in LASIK. *Cornea*. 2006;25(2):136–138.
5. Braun EH, Lee J, Steinert RF. Monovision in LASIK. *Ophthalmology*. 2008;115(7):1196–1202.
6. Marketscope 2012: IOL report.
7. Tomita M, Waring GO IV. One-year results of simultaneous laser in situ keratomileusis and small-aperture corneal inlay implantation for hyperopic presbyopia: Comparison by age. *J Cataract Refract Surg*. 2015;41(1):152–161.
8. Tomita M, Kanamori T, Waring GO IV, et al. Simultaneous corneal inlay implantation and laser in situ keratomileusis for presbyopia in patients with hyperopia, myopia, or emmetropia: Six-month results. *J Cataract Refract Surg*. 2012;38(3):495–506.

#### Minoru Tomita, MD, PhD

- CEO, Eye Can Medical Group
- Medical Director, Minoru Tomita Eye Clinic Ginza, Tokyo, Japan
- Adjunct Clinical Professor of Ophthalmology, Wenzhou University, Wenzhou, Zhejiang, Japan
- harvardmedical1972@gmail.com
- Financial disclosure: Global Medical Advisory Board (AcuFocus)