

The Downside of Femto Laser Flaps

Surgeons must not forget the potential for intra- and postoperative complications.

BY WAYNE CREWE-BROWN, MD

Femtosecond laser technology arrived on the refractive surgery scene several years ago, and surgeons responded positively to what they viewed as a quantum leap in flap-making technology. Since this time, femtosecond use has exploded exponentially, with promises to revolutionize how we conduct laser surgery.

Many practices no longer use a bladed microkeratome and, as occurred with intra- and extracapsular cataract surgery after the introduction of phacoemulsification, there will soon be generations of laser eye surgeons who will not know how to use a mechanical microkeratome. As is the case with so many new technologies, the transition can be fraught with problems and a learning curve—things that many surgeons do not consider amid all of the advantages that this technology offers. This article provides brief but balanced view of the difficulties associated with making the change from mechanical microkeratome to femtosecond laser. I also review some of the complications associated with femtosecond flaps.

COST

One of the biggest obstacles to entry into the femtosecond world is cost. Many European ophthalmologists partake in refractive surgery on a part-time basis, combining it with work in other subspecialties. For these surgeons, the cost of acquiring femtosecond technology can be prohibitive, unless they group together with other surgeons to share a machine or use a mobile fee-per-procedure platform. The tendency for larger commercial laser practices to offer femtosecond flaps places additional pressure on the solo refractive surgeon to embrace the technology.

Femtosecond platforms currently on the market are the Femto LDV (Ziemer Group, Port, Switzerland), IntraLase FS60/iFS femtosecond laser (Abbott Medical Optics Inc., Santa Ana, California), Technolas 520F (Technolas Perfect Vision GmbH, Munich, Germany), and the VisuMax (Carl Zeiss Meditec, Jena, Germany). Other models are under development, including the Wavelight FS-200 (Erlangen, Germany), which may be released as early as September.




Figure 1. (A) Hard or early OBL spreads ahead of the raster pattern. (B) Soft or late OBL appears as opaque patches in areas where the raster pattern has already been completed.

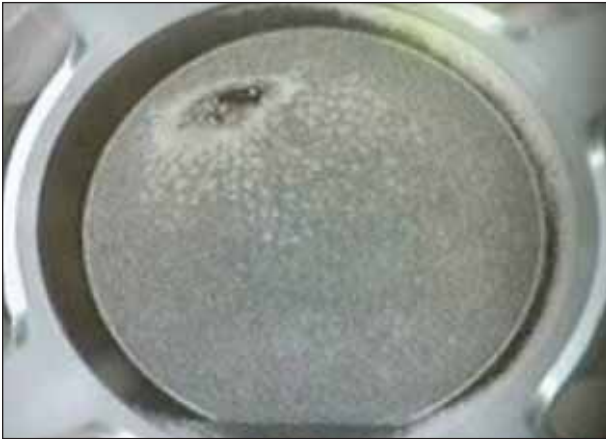

Figure 2. Vertical gas breakthrough can occur if the flap is too thin or if there is a focal break or scar in Bowman's membrane.

INTRAOPERATIVE COMPLICATIONS

Femtosecond flap complications can be divided broadly into two categories, intraoperative and postoperative events. Intraoperative complications include opaque bubble layer (OBL), vertical gas breakthrough, thin flaps, horizontal gas breakthrough, suction break, gas bubbles in the anterior chamber, and decentered flaps.

OBL. This complication is a collection of gas bubbles in the intralamellar spaces above and below the resection plane. Early or hard OBL (Figure 1A) spreads ahead of the raster pattern, and late or soft OBL (Figure 1B) appears as opaque patches in areas where the raster pattern has already passed through.

Early OBL can interfere with the effectiveness of additional laser pulses and make flap lifting more difficult. Excessive OBL can impede some excimer laser tracking systems and can obstruct or distort ultrasound measurements taken during intraoperative pachymetry. The surgeon can avoid OBL by adjusting the pocket depth, pocket width, pocket spot/line separation, and hinge angle, all in an effort to optimize gas evacuation. Some surgeons have found that lighter applanation also reduces OBL. In some corneas, starting the pattern near the limbus can allow gas to collect circumferentially in the perilimbal area, reducing OBL. Lastly, modifying the raster energy and/or spot/line separation can potentially minimize OBL.

Vertical gas breakthrough. Although uncommon, vertical gas break-

TAKE-HOME MESSAGE

- The learning curve with femtosecond laser technology can be challenging.
- Many European ophthalmologists practice refractive surgery only part time, making the cost of the femtosecond laser a major barrier to its adoption.
- Associated drawbacks, including intra- and postoperative complications, are not as commonly discussed as the benefits of femtosecond technology.

through (incidence, 0.1%; Figure 2) can occur if the laser flap is programmed too thin—generally 100 μm or less—or if there is a focal break or scar in Bowman's membrane.

Thin flaps. This complication (Figure 3) is similar in cause and effect to vertical gas breakthrough. To verify a safe flap thickness, the surgeon should use the bubble pachymetry technique prior to lifting.

Horizontal gas breakthrough (HGB). Occurring when the pocket is overly efficient and the gas is vented in quick bursts, HGB can potentially leave an irregular pattern on the stromal bed. The likelihood of HGB can be decreased with good docking techniques and appropriate raster and pocket settings.

Suction break. Management occurs in one of two ways: Either the procedure is repeated immediately using the same cone or the procedure is abandoned and repeated after a variable period of days to weeks. In these situations, there is a profound difference and advantage over an incomplete microkeratome flap, in which immediate abandonment is mandatory and the subsequent treatment is inevitably a surface procedure after a much longer delay. Some would say that this is the single-most important reason for converting to femtosecond flaps. Suction breaks can be avoided in several ways:

- Assure proper centration and suction before docking;

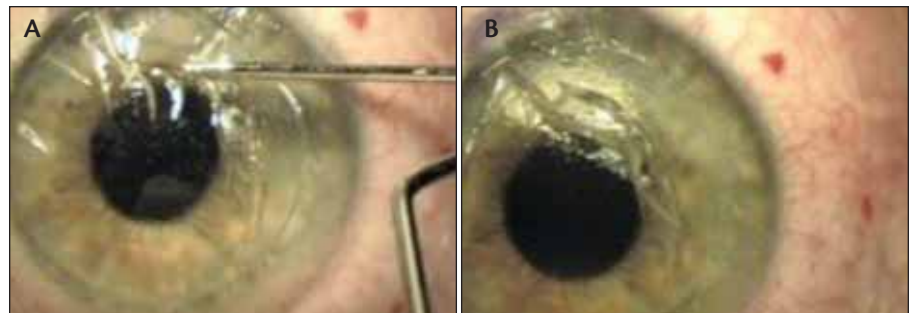


Figure 3. (A) A thin flap being lifted. (B) A thin flap torn and fragmented after lifting.

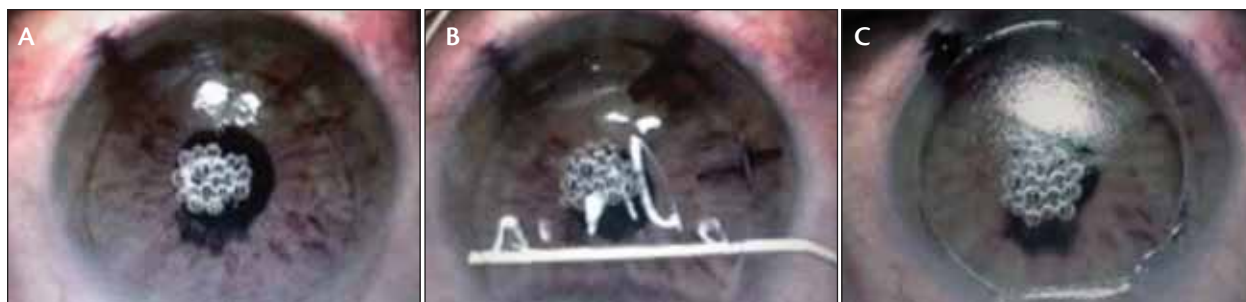

Figure 4. (A, B) Gas bubbles are visible underneath the flap. (C) They are still visible once the flap has been lifted.

- Avoid all horizontal and vertical movements of the gantry as soon as the cone is docked;
- Avoid major hand movements when holding the suction ring assembly;
- Continually monitor the applanated area after the downward movement is completed; and
- Reassure the patient while the laser is firing to keep him calm and relaxed.

Gas bubbles in the anterior chamber. The presence of gas bubbles in the anterior chamber (Figure 4) is a relatively rare complication of femtosecond flaps. When it occurs, gas bubbles diffuse into the anterior chamber during flap creation. Some may not regard this as a true complication; however, the bubbles may disrupt the excimer laser's tracking system. Treatment is delayed by several minutes to several hours while waiting for the bubbles to fully dissipate.

Decentered flaps. The following techniques help avoid decentered flaps:

- Prescreen patients to identify larger shifts in their angle kappa;
- Mark the visual axis as a target for the suction ring;
- Eliminate all horizontal and vertical movements of the gantry as the cone is docked; and
- When applanation is complete, verify that the suction ring assembly is level.

Do not accept an effective loss in flap diameter of greater than 0.5 mm, as this may compromise the effectiveness of your laser treatment.

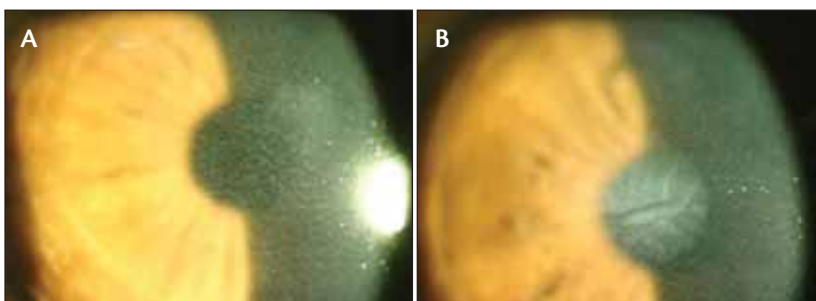


Figure 5. (A, B) DLK presents as an inflammatory reaction in the interface.

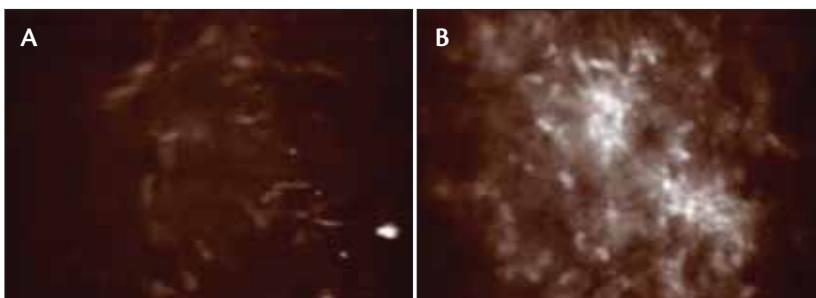


Figure 6. Confocal image of the post-LASIK interface of (A) an asymptomatic patient and (B) a patient with TLSS where probable activated keratocytes are present.

POSTOPERATIVE EVENTS

Inflammation or diffuse lamellar keratitis (DLK), photophobia and transient light sensitivity syndrome (TLSS), striae, and epithelial ingrowth have all been associated with femtosecond laser flap creation.

Inflammation or DLK. Associated with LASIK, DLK (Figure 5) is characterized by appearance of a noninfectious inflammatory reaction in the interface, usually noticeable 1 to 5 days after LASIK. The etiology and pathogenesis is multifaceted. The incidence is lower with newer, lower-energy femtosecond lasers such as the 60-kHz IntraLase. Management of DLK includes intense steroid drop therapy or flap washout, depending on the severity or grading.

Photophobia and TLSS. These are rare phenomena usu-

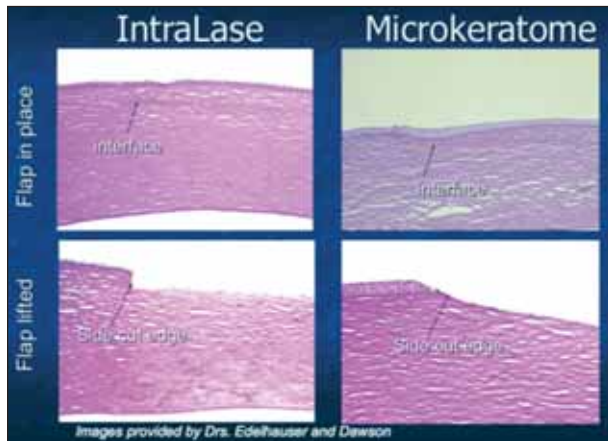


Figure 7. Histology slide demonstrating the effect of flap biomechanics with IntraLase and mechanical microkeratome.

ally appearing 2 to 6 weeks postoperatively. Patients can present with moderate to extreme light sensitivity, a good UCVA, and no slit-lamp findings. As it may be related to energy and keratocyte activation (Figure 6), TLSS too has nearly disappeared with the production of lower-energy femtosecond lasers.

Striae and epithelial ingrowth. Although they can occur with microkeratome and femtosecond flaps alike,

striae and epithelial ingrowth (Figure 7) are less likely to occur with the femtosecond laser due to flap biomechanics. The beveled flap-edge angle provides greater flap stability due to the so-called *manhole cover effect*. Management follows the same protocol as for microkeratome-related striae and epithelial ingrowth.

CONCLUSION

Most refractive surgeons, and even cataract surgeons, are aware of the benefits associated with the use of the femtosecond laser; however, the drawbacks are not commonly mentioned. When weighing the pros and cons of transitioning to femtosecond laser technology for flap creation, such drawbacks as the cost and complications should not be overlooked. ■

Wayne Crewe-Brown, MD, is a Consultant Ophthalmic Surgeon at Kirkwood Fyfe Clinic, UKSH NHS Treatment Centre, and the Director of Visiocare Consultants Ltd., both in the United Kingdom, and a Consultant Ophthalmic Surgeon at Optilase Laser Eye Clinics, in Ireland. Dr. Crewe-Brown states that he is a paid physician trainer for Abbott Medical Optics Inc., but otherwise has no financial interest in the products or companies mentioned. He may be reached at e-mail: waynecrewbrown@aol.com.

2nd International course on ophthalmic and oculoplastic reconstruction and trauma surgery

advanced
Ophthalmic
trainings

In-depth lectures and 12 hours of highly realistic hands-on trainings on the unmodified human tissue
VIENNA, January 12th-14th 2011, Vienna General Hospital / Neurosurgical Laboratory

Hosted by

Univ.-Prof. Ursula Schmidt-Erfurth, MD
Chair of the Department of Ophthalmology
Medical University Vienna

Course directors

Univ.-Prof. Franz-Josef Steinkogler, MD
Head of oculoplastic and lacrimal surgery
Medical University Vienna

Ass. Prof. Stephan Kaminski, MD
Head of cornea bank
Medical University Vienna

Information and registration at www.ophtalmictrainings.com

Supported in part by:



BAUSCH+LOMB

ETHICON
a Johnson & Johnson company

Cataract & Refractive Surgery
EUROPE TODAY

In cooperation with:

