Monovision Strategies

In addition to conventional monovision, several modified methods are in use today.

BY KIMIYA SHIMIZU, MD, PHD

While advancing surgical techniques continually improve modern cataract surgery, the rise of refractive surgery also plays a part in elevating patients' expectations for presbyopia correction today. Current lens-based options to combat the onset of presbyopia include premium IOLs (multifocal and accommodating) and monovision. But regardless of the technique we use, today's patients expect an improvement in their quality of vision and a rejuvenation of their accommodation.

Depending on the selected strategy, however, this may be challenging. With bilateral multifocal IOL implantation, changes in pupil diameter can affect visual performance and may cause visual discomfort. Additionally, earlier multifocal IOL designs brought unwanted photic phenomena including glare and halos.[1] Despite the introduction of improved refractive multifocal and apodized diffractive multifocal IOLs, these lenses remain imperfect and sometimes necessitate the use of spectacles and contact lenses postoperatively. With accommodating IOLs, we can obtain only pseudoaccommodation at best, and the risk for posterior capsular opacification (PCO) after surgery is high. Therefore, monovision strategies remain viable for correction of presbyopia. This article reviews the monovision methods available to us today.

Monovision correction results in artificial anisometropia, an intentionally created difference in refractive powers between the patient's two eyes. When differences in bilateral visual acuity are identified before surgery, however, the visual performance of the eyes must be balanced to allow adjustment tests to ensure maintaining the patient's visual performance after surgery.

A key point for success of monovision is patient selection.[2] For successful monovision outcomes, the following conditions should be met: Patients should have excellent distance UCVA in the dominant eye, near exophoria of less than 10 prism diopters, age greater than 60 years, and small pupil diameter to enhance near vision performance. At our center, we do not use the monovision method in patients with ocular disease or large amounts of corneal astigmatism, and we choose monovision carefully in patients with large exophorias such as vertical deviation or strabismus. If the patient has more than 1.00 D of astigmatism but desires pseudophakic monovision, we choose from one of the following strategies: cataract surgery with a limbal relaxing incision, photoastigmatic keratectomy, or implantation of a toric IOL.

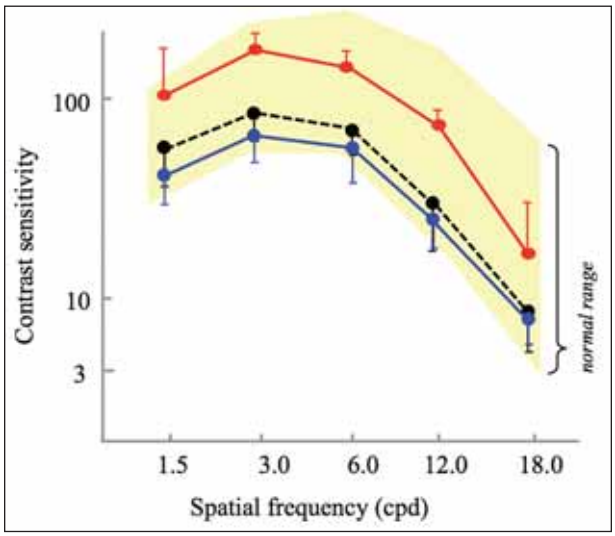

Figure 1. Binocular contrast sensitivity.
(red line = monovision; blue line = bilateral refractive multifocal IOL implantation; dotted black line = bilateral diffractive multifocal IOL implantation)

MONOVISION STRATEGIES

Conventional monovision. We prefer conventional monovision, correcting the dominant eye for distance and the nondominant eye for near vision. To test for

the appropriateness of using this method, we use pattern visual evoked cortical potentials (VECPs) to assess the interaction of binocular signals in the visual cortex (Figure 1); when the strength of ocular dominance is weak, divergent visual signals can be processed more smoothly by the brain. Weak ocular dominance is important for the success of monovision. There continues to be debate on the application of monovision due to the complexity of evaluating ocular dominance.

Pseudophakic monovision. The use of standard monofocal IOLs for monovision in the pseudophakic eye is limited because these IOLs do not preserve natural accommodation. In our practice, the target refraction is emetropia in the dominant eye and myopia (-1.50 to -2.50 D) in the nondominant. A large degree of anisometropia is needed to obtain excellent near visual acuity, and a resulting relative decrease of near stereopsis occurs. Additionally, the evaluation of ocular dominance in these eyes is complex. We have, however, performed pseudophakic monovision with good results. In our experience, 81% of patients are satisfied after surgery. Satisfaction is age-dependent; among those less than 60 years old, 64% are satisfied; between 60 and 70 years, 87%; and over 70 years, 94%.

Customized monovision. As an alternative to pseudophakic monovision, we prefer customized monovision with multifocal IOLs. This strategy achieves the same effect as standard monovision but with less anisometropia.

In our practice, the target refraction is emmetropia in the dominant eye and slight myopia (-1.00 D) in the nondominant. Although near stereopsis is typically within the normal range, contrast sensitivity is likely to decrease, and the ability to read smaller characters is diminished in comparison with pseudophakic monovision. When multifocal IOLs are used with this strategy, adequate pupil diameter is essential. Although age-related decrease in pupil diameter is common, no serious complaints regarding near vision with this strategy have been noted.

Mild monovision. We currently use monovision with pseudoaccommodation in patients with pupil diameters of less than 2.5 mm.[3] In our practice, the target refraction is emmetropia in the dominant eye and slight myopia (-1.00 to 1.50 D) in the nondominant if the pupil diameter is 2.5 mm or less. This method achieves the same positive effects, maintains contrast sensitivity and stereopsis, and causes less anisometropia. In our experience, at least 90% of patients are satisfied with mild monovision. Pupil diameter decreases with age, and therefore this approach to monovision is more beneficial for elderly patients.

TAKE-HOME MESSAGE

- Monovision correction results in artificial anisometropia, an intentionally created difference in refractive powers between the patient's two eyes.
- Satisfaction with monovision is age dependent. For instance, mild monovision is beneficial for elderly patients, whereas hybrid monovision is preferable for patients under the age of 60 years.

Hybrid monovision. Conventional pseudophakic monovision generally provides little benefit to patients under age 60 years in terms of the degree of satisfaction and the rate of spectacle independence. Since 2009, we have been using hybrid monovision. In this strategy, we implant a monofocal IOL in the dominant eye and a diffractive multifocal IOL in the nondominant eye. With this type of binocular vision, patients do not complain of discomfort, and more than 85% are satisfied with their results. We have noticed a relative decrease in stereopsis; however, the normal range was maintained in 63% of patients. No serious complaints have been reported after hybrid monovision.

CONCLUSION

Monovision can effectively compensate for accommodative loss after cataract surgery when a careful patient selection process is followed. Further research is crucial regarding the effects of monovision not only in the optical system but in the brain, where visual signals undergo integrated processing.

Over the years, monofocal IOLs have continually provided excellent visual results. When we consider the prevalence of age-related ocular diseases that reduce retinal sensitivity, it is perhaps even preferable to remain with the monovision method and avoid the loss of contrast sensitivity that multifocal IOLs incur. However, a number of new IOLs are expected to enhance the diversity of effective presbyopic treatment in the near future. ■

Kimiya Shimizu, MD, PhD, practices in the Department of Ophthalmology, School of Medicine, Kitasato University, Kanagawa, Japan. Dr. Shimizu states that he has no financial interest in the products or companies mentioned. He may be reached at tel: +81 42 778 8464; fax. +81 42 778 2357; e-mail: kimiyas@med.kitasato-u.ac.jp.

1. Hunkeler JD, Coffman TM, Paugh J, Lang A, Smith P, Tarantino N. Characterization of visual phenomena with the Array multifocal intraocular lens. *J Cataract Refract Surg*. 2002;28:1195-1204.
2. Ito M, Shimizu K. Pseudophakic monovision. *CRST Europe*. 2009;4:64-66.
3. Kawamorita T, Uozato H, Handa T, Ito M, Shimizu K. Effect of pupil size on visual acuity in a laboratory model of pseudophakic monovision. *J Refract Surg*. 2010;25:1-3.