Case Study: ZEISS AT LISA tri IOL

BY JORGE L. ALIO, MD, PHD
Alicante, Spain

Prof. Dr Jorge Alio has been Professor and Chairman of Ophthalmology since 1987, first at the University of Alicante and since 2002 at the University Miguel Hernandez de Elche, also in Alicante, Spain.

Successful treatment of an unhappy monovision patient with the trifocal AT LISA tri

In this report we describe the special case of a patient with monovision following refractive lens exchange. Unhappy with the outcome, his monofocal lenses were successfully explanted and the patient was bilaterally re-implanted with the trifocal AT LISA tri 839MP, in the capsular bag. 1 month after the lens exchange, the patient was extremely satisfied with the outcome.

Introduction

Monovision is a very popular method to compensate pseudophakic presbyopia. This technique is used both in cataract surgery and refractive lens exchange. Usually, emmetropia is targeted in the patient's dominant eye to correct distance vision, and myopia (-1.5 to -2.0 D) is targeted in the non-dominant eye to correct near vision.

Astigmatism is also targeted during the surgery with relaxing incisions or toric intraocular lens. The patient's brain normally learns within 4-6 weeks to use the distance focused eye for distance viewing and the near focused eye for near viewing.

The case reported here is a patient who underwent a pseudophakic monovision procedure and after 3 months of follow up, came to us for a second opinion. The patient was dissatisfied with the outcome.

Case report

The patient was a 65-year-old male, suffering from moderate hyperopia of +3 D in each eye. Previous reports indicate that with his corrective spectacle lenses the patient achieved 1 dec. for far in each eye and J1 for near. A previous surgeon had offered the patient refractive lens exchange with monovision, an alternative that the patient accepted. Surgery was performed with no reported complications. However, 3 months following the surgery, the patient came for a second opinion as he was dissatisfied with the outcome.

His vision quality with monovision was not satisfactory and he wanted to see for both far and near with each eye in normal conditions. He felt that he had lost binocularity and his performance in his favorite sport, golf, had been negatively affected by the outcome.

In the clinical examination the patient showed an uncorrected visual acuity in the right eye of 0.2 dec, which reached 20/20 with (-2 -0.5 x 90), while the left eye showed an uncorrected vision of 0.8 dec. which improved to 1 dec. with (-0.5 -0.5 x 85).

Slit lamp examination demonstrated a properly performed refractive lens exchange in both eyes. The monofocal intraocular lenses implanted were properly centred, with a capsulorhexis of 5 mm, and a lens diameter of 6 mm. No complications appeared in the anterior chamber.

Pupil dynamics were normal and photopic pupil (infrared pupilometry) reached a diameter of 3.5 mm. The rest of the ocular examination was unremarkable.

The patient was informed that any correction of his residual refractive error for far vision was going to lead to near

vision loss with continuous use of near vision glasses. The patient refused this alternative.

We informed the patient that one option was to transform his monofocal pseudophakia into a multifocal pseudophakia with the use of the trifocal AT LISA tri 839MP. We extensively explained to the patient the pros and cons of this procedure and the surgical risks involved. The patient accepted this indication.

The surgery was prepared targeting emmetropia in both eyes. The patient's right eye was first operated under sedation with local anesthesia.

We used cohesive viscoelastic, Lester hooks, and a spatula to dissect the capsular bag. The monofocal lens was easily separated from the capsular bag and was correctly explanted by creating a radial incision and rotating it at the axis of this incision, placed at the positive meridian of the corneal curvature (Fig 1).

Once emptied, the capsular bag was insufflated with more cohesive viscoelastic and the multifocal lens was injected and implanted through an incision of 2.5 mm. The full intervention was performed with no complications.

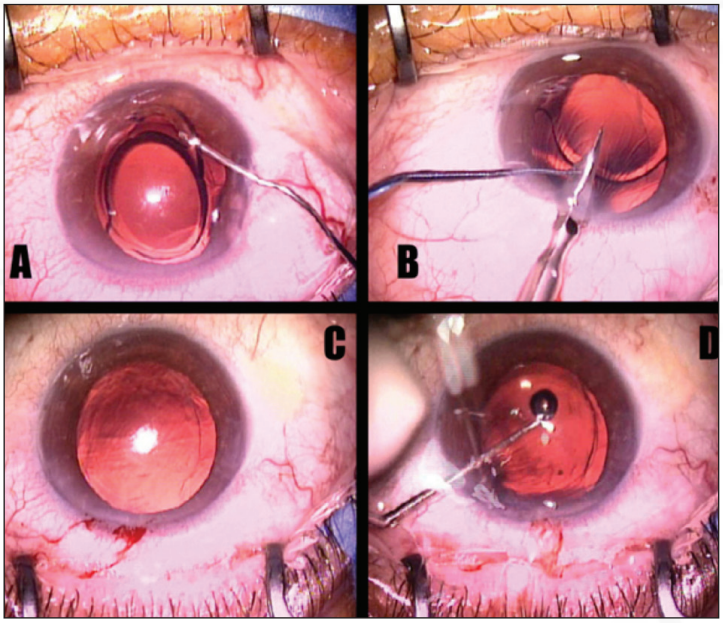

Fig.1

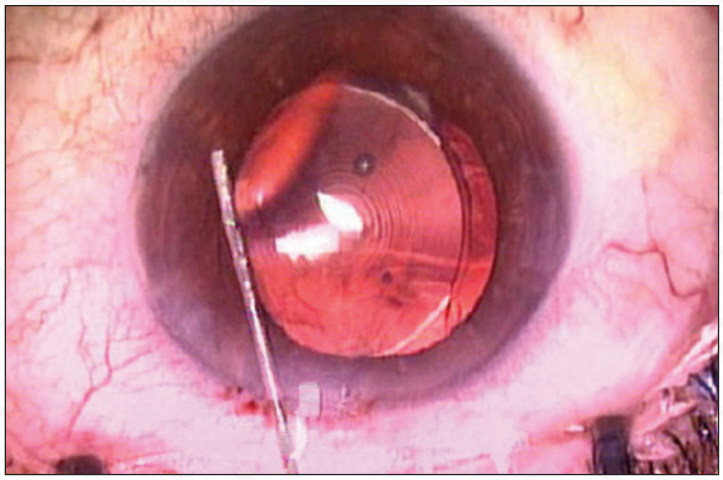

Fig.2

Three weeks after the successful implantation of the right eye, we performed the same procedure, also successfully, in the left eye (Fig 2).

Three days after the second procedure, the patient was very happy as he could reach 20/20, in uncorrected binocular conditions, while each eye individually was 0.8 dec. Uncorrected, binocular near vision was J3.

One month later, the patient was 20/20 for far monocular and binocular 1.25 dec.. Near vision was 20/25 (0.8 in the LogRad charts). Extreme patient satisfaction was achieved. The patient was spectacle independent for all distances.

Minimum halos and no glare were reported by the patient, who was overall very happy with the outcome.

Conclusion

Conversion of monofocal pseudophakia into multifocal pseudophakia using the AT LISA tri 839MP is an excellent alternative in cases of patient dissatisfaction following monovision procedure.

References

Alio JL, Grzybowski A, El Aswad A, Romaniuk D. Refractive lens exchange, Surv Ophthalmol. 2014;59:579-98
Alio J.L.; Pikkel J.;Multifocal Intraocular Lenses.
The Art and the Practice: Springer. ISBN: 978-3-319-09218-8 (First Edition: 2014)

EN_32_021_00051