Intraoperative OCT-Guided Closure in Revisional Macular Hole Surgery

BY MAHI MUQIT, MD
United Kingdom
Mahi Muqit PhD FRCOphth is a Consultant Ophthalmologist, Cataract and Vitreoretinal Surgeon at Moorfields Eye Hospital, and an Honorary Clinical Lecturer at the Institute of Ophthalmology at UCL, London. His research interests include diabetic retinopathy, vitreoretinal surgery, artificial retinal prosthesis, OCT and retinal laser.
Contact: Mahi.Muqit@Moorfields.nhs.uk

Patient History

A 78 year-old female had failed phacovitrectomy, internal limiting membrane (ILM) peel with C3F8 gas surgery for a very large full-thickness macular hole (FTMH). She underwent revisional vitrectomy surgery for an open hole.

Planned Treatment Without Intraoperative OCT

During 23-G vitrectomy surgery without OCT, there were no obvious signs of residual ILM identified using macular blue stain.

Treatment With Intraoperative OCT

The OPMI LUMERA 700 and intraoperative OCT RESCAN 700 from ZEISS was essential to assist in visualization of the remnants of ILM that were inducing persisting traction and keeping the macular hole open. A collar of residual ILM was located at the edge of the macular hole using intraoperative OCT guidance, and the ILM tissue was removed successfully with intraoperative OCT. The technique of localized foveal retinal detachment using balance salt solution was performed but the endpoint of raised macular hole edges was difficult to judge. The intraoperative OCT system supported accurate calculation of the size of foveal retinal detachment. The raised edges of the FTMH were significantly elevated at the end of surgery to maximize the chances of hole closure and the maximum diameter of the FTMH assessed. Based on the intraoperative size of the macular hole using intraoperative OCT, a short-acting gas bubble was used for the surgery. The FTMH remained closed at 6 months after surgery with improved vision of 20 / 80.

Conclusion

The macular hole closed after intraoperative OCT-guided vitrectomy, ILM peeling and SF6 gas tamponade surgery. The critical steps that determine the surgical end-points for revisional macular hole surgery were easily visualized using intraoperative OCT. The ILM tissue landmarks and macular hole dimensions were evaluated using intraoperative OCT to allow successful surgery.

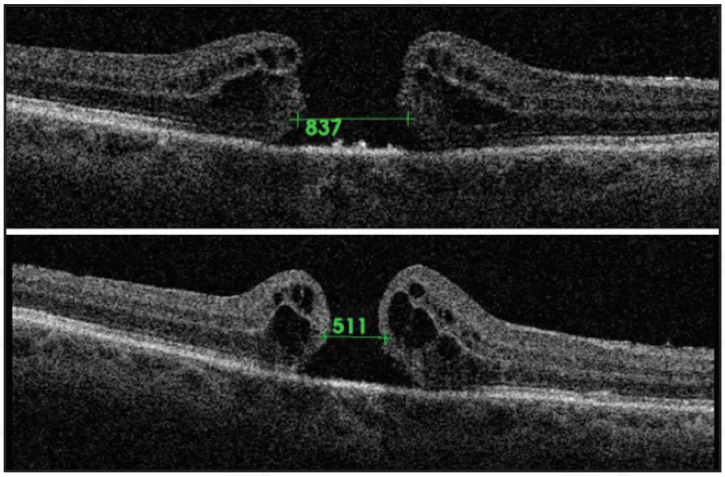

Figure 1

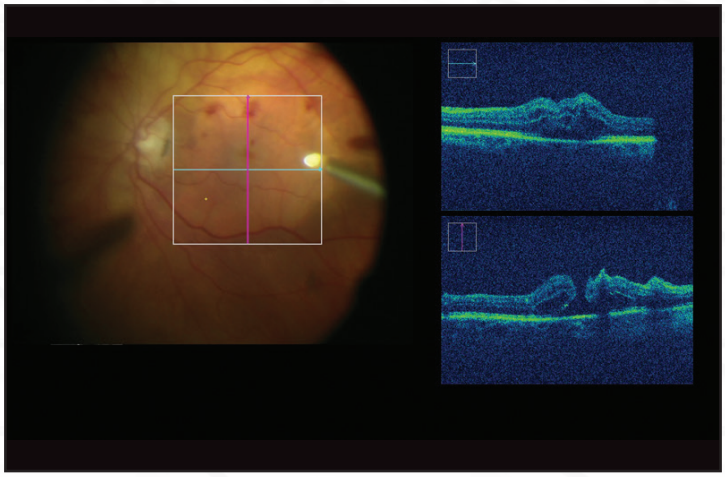

Figure 2

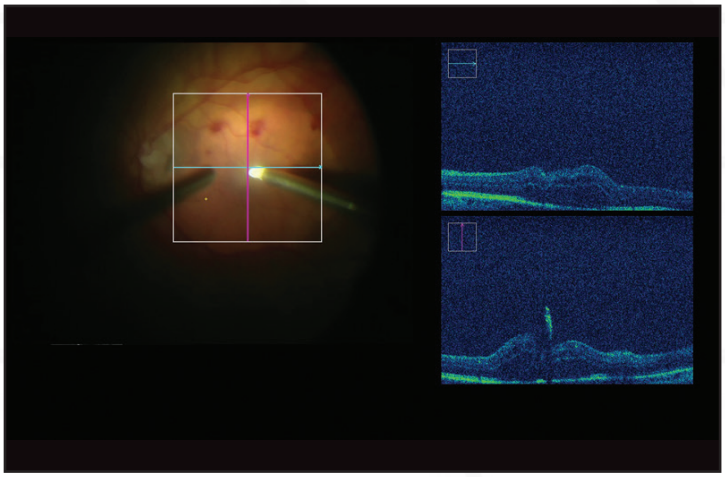

Figure 3

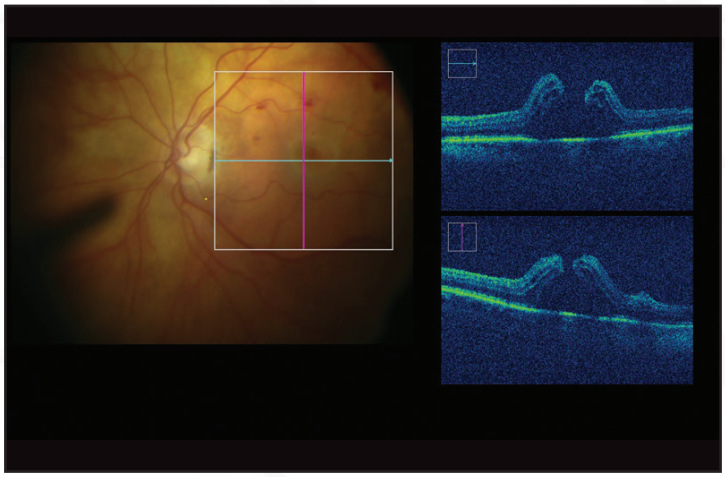

Figure 4

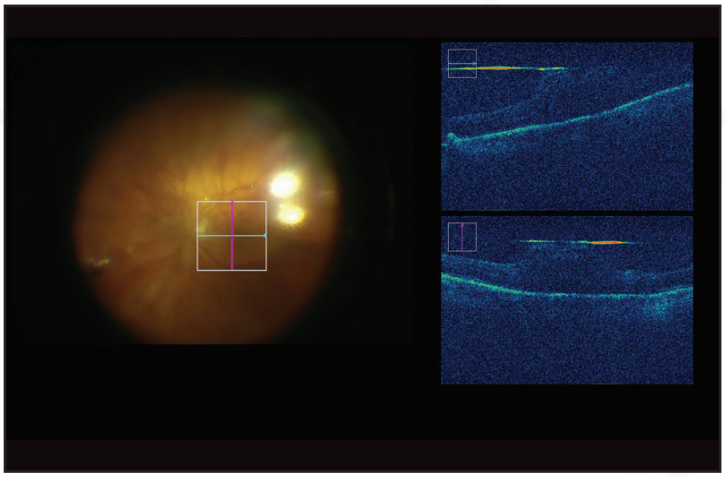

Figure 5

Figure 1. Intraoperative OCT shows very large FTMH with 20/200 vision. Lower OCT shows hole status after first surgery failed

Figure 2. The intraoperative OCT localizes the remnant of ILM that can be seen protruding from the right side of the macular hole

Figure 3. The ILM is brushed off using diamond-dusted Tano instrumentation, and the intraoperative OCT is able to visualize this ILM tissue dissection

Figure 4. After foveal detachment using BSS, the elevated macular hole edges are seen clearly on intraoperative OCT

Figure 5. After air-fluid exchange, the elevated edges of the macular hole can be visualized with intraoperative OCT

EN_31_021_00071