Intraoperative OCT Assisted Re-DSAEK with ZEISS LUMERA 700 and RESCAN 700

BY MARTA CALATAYUD, MD
Institut Catala de Retina 'ICR'
Barcelona, Spain
Dr. Marta Calatayud made her ophthalmic training in the Ophthalmology department at Vall D'Hebron Hospital in Barcelona, Spain. She has been working as a consultant in the cornea and ocular surface unit of this Universitary Hospital during the last 16 years, combining the public practice and resident's training with research in the field of regenerative therapies in corneal transplantation .
She is also working at Instituto Oftalmologico Quirón Barcelona as head of cornea and ocular surface section.

Patient History

Male, 62 year-old, with no specified corneal opacities and a previous failed DSAEK. The patient has a severe cardiopathy with antiplatelet treatment. BCVA is hand movement.

Planned treatment without intraoperative OCT

The patient would be discarded for lamellar surgery because of the corneal opacities and edema of unknown etiology. Antiplatelet treatment should be removed and a penetrating keratoplasty would be performed assuming the risk of massive choroidal haemorrhage and vitreous wicking syndrome. Recovery would be delayed until the suture removal.

Treatment with intraoperative OCT

The patient is treated with a new DSAEK, with special care taken to peel off all the descemet´s membrane remains. After the removal of the graft, the anterior chamber becomes clear and the intraoperative OCT image is sharper, allowing the surgeon to work comfortably. Intraoperative OCT changes surgical indications, since it reduces the impact of secondary problems like clouding, corneal opacity, peripheral folds in the graft or any other condition which could potentially lead to failure of the procedure. The most prominent complication of DSAEK, lenticle dislocation, is prevented by carefully evaluating the whole graft with a real view of graft interface and periphery. Any vitreous wicking can also be detected by primary or secondary signs observed in the OCT real-time images.

Conclusion

Intraoperative OCT tips the scales towards the improvement of corneal lamellar surgery, it increases the indications to the detriment of penetrating keratoplasty. The use of intraoperative OCT bypasses the corneal edema and minimizes the difficulties associated with this type of complicated procedures, making lamellar corneal transplantation easier. Another advantage of intraoperative OCT is the chance to see the iridocorneal angle, to detect any closure during the surgery on the 360 degrees, indicating a retropupilary bubble.

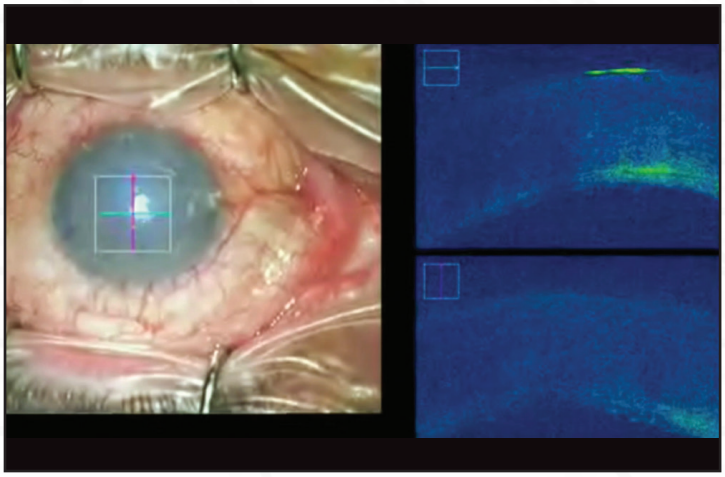

Figure 1

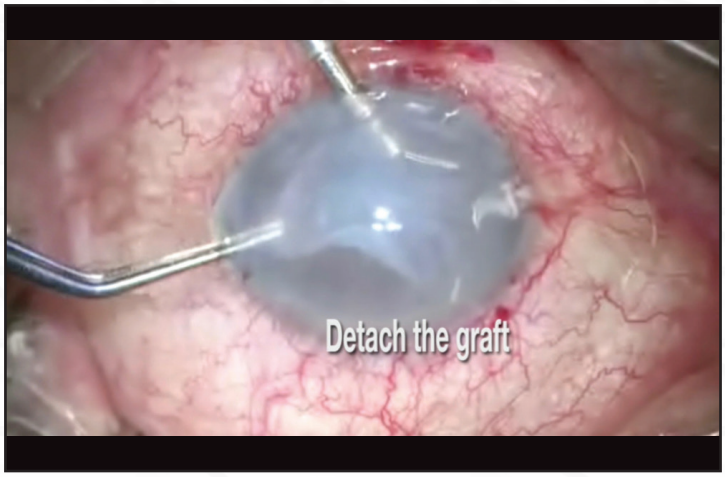

Figure 2

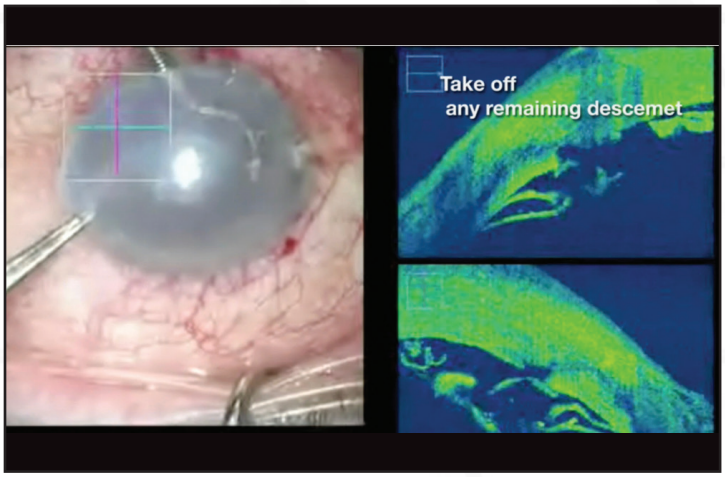

Figure 3

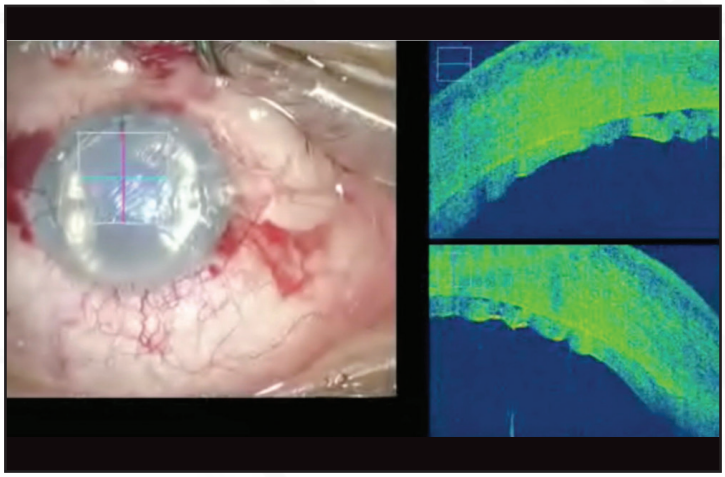

Figure 4

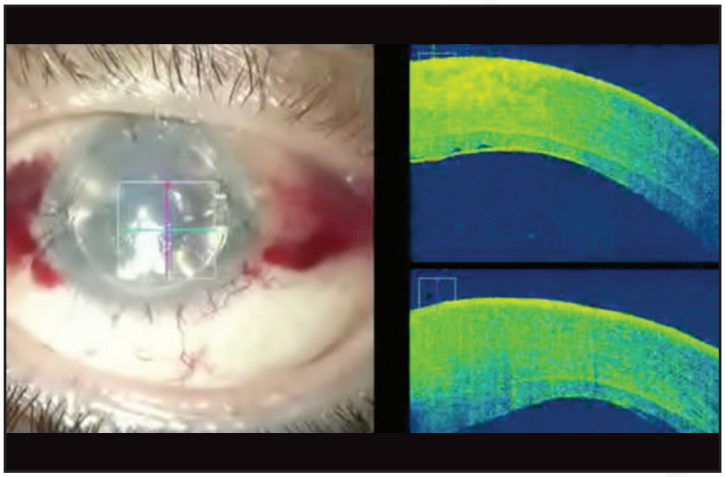

Figure 5

Figure 1. Cloudy cornea prevents seeing any structure in the anterior chamber. Intraoperative OCT allows one to identify the graft and to manipulate it.

Figure 2. The graft is detached and removed with forceps.

Figure 3. Even though visibility of the anterior chamber structures is compromised, intraoperative OCT provides a clear image and enables one to eliminate any remaining Descemet membrane.

Figure 4. The graft is attached to the stroma, but with folds and thicker than described in the report from the eyebank.

Figure 5. After rolling the cornea under high pressure, the graft is thinner and without any folds.

EN_32_021_00271