MY MOST MEMORABLE KERARING CASE

Instrastromal corneal ring restored vision in a one-eyed patient with keratoconus.

BY EFEKAN COSKUNSEVEN, MD

Correcting the distorted vision caused by the corneal bulging and thinning seen in keratoconus can be a challenge. Spectacles and soft contact lenses usually suffice in the early stage of keratoconus, but the level of vision correction they provide tends to decrease as the disease progresses. When this occurs, the patient can turn to rigid gas permeable contact lenses as an alternative surgery-free correction method. However, when contact lenses can no longer be tolerated, surgical options must be considered.

In such cases, implantation of the Keraring intrastromal corneal ring (Mediphacos) is the option I choose for many keratoconus patients. In fact, I have implanted approximately 5,000 Kerarings to date. It is my preferred surgical correction method because it delivers the type of improvement in visual acuity that can transform the lives of patients who feel that a corneal transplant is the only way they will ever see clearly again.

CASE REPORT

A case in point is that of a 23-year-old woman I treated 10 years ago (see *Case Presentation*). She worked as a farmer in a village in eastern Turkey and had lost her right eye due to traumatic perforation. Unfortunately, her other eye was keratoconic, with a UCVA and BCVA of just 0.1 (Snellen decimal).

This patient's vision was so bad that she struggled to work, and her dusty work environment made using contact lenses impossible. She came to see me because doctors in the rural part of eastern Turkey where she lived had little experience with corneal ring implantation and advised her to undergo a corneal transplant—something she was intensely afraid of doing. By the time we met, she felt hopelessly stuck with her failing vision.

On examining her remaining left eye, I found that it had good corneal thickness and was suitable for ring implantation. I implanted a single Keraring into her left eye. The next day, she returned with a UCVA of 0.6 and BCVA of 0.8. She was crying tears of joy, and the transformation in her is something I shall never forget.

I saw the patient again 1 month later, at which time I performed CXL to arrest further disease progression. Her vision was still excellent and she had no complications. I have continued following her over the years, and she remains happy with stable vision.

CASE PRESENTATION

Pre- (left) and postoperative (right) corneal topographies in the keratoconic left eye of a 23-year-old. Preoperatively, BCVA was 0.1 and the inferior cone was clearly seen. Postoperatively, BCVA improved to 0.8, and corneal topography normalized.

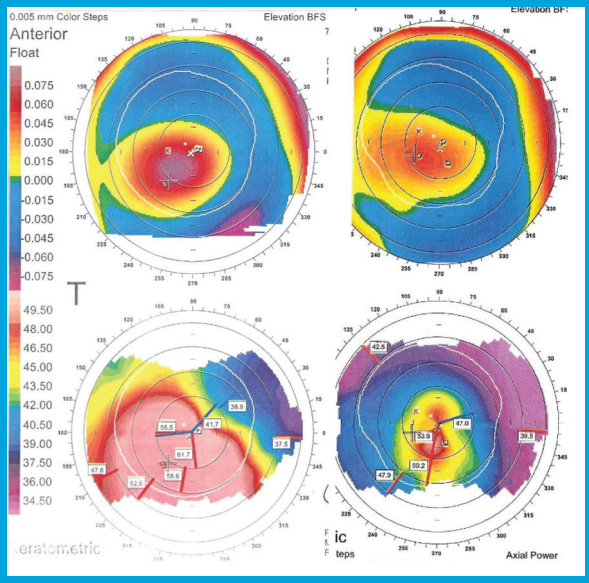

LIFE-CHANGING SURGERY

This patient's case exemplifies how ophthalmic specialists can change the lives of keratoconus patients using a simple procedure such as intrastromal corneal ring implantation. Like my patient, many others believe their only options are external aids such as spectacles or more intricate surgical procedures such as a corneal transplant. In fact, Keraring implantation presents a less invasive method to provide the exemplary visual outcomes many of these patients need. ■

Efekan Coskunseven, MD
- Director of Refractive Surgery, Dunya Eye Hospital, Istanbul, Turkey
- efekan.coskunseven@dunyagoz.com
- Financial disclosure: Consultant (Mediphacos)