BEST KEPT SECRETS

Femtis Laser Lens

The Expert

DETLEF HOLLAND, MD
- Cataract and refractive surgeon, Augenklinik Bellevue, Kiel, Germany
- Member, *CRST Europe* Editorial Board
- d.holland@augenklinik-bellevue.de
- Financial disclosure: The multicenter study mentioned in this article was financed by Oculentis

Use of the femtosecond laser in ophthalmology is growing all over the world. In cataract surgery, these lasers offer many advantages, including a decrease in effective phacoemulsification time and the possibility to reduce corneal astigmatism by creation of arcuate incisions. Perhaps the greatest advantage of this new technology, however, is the laser's ability to create a perfect capsulotomy.

The literature suggests that laser capsulotomy is superior to manual capsulorrhexis in ensuring roundness, centration, and the overlapping of the IOL optic by the capsule, and also in preventing lens tilt. Furthermore, there seems to be a potential reduction in postoperative aberrations. In data from more than 3 years of experience with laser-assisted cataract surgery (LACS) at our center, the strength of the laser capsulotomy (Figure 1) and the incidence of capsular tears are comparable to those with traditional capsulorrhexis.

The rare need for surgical revision after cataract surgery happens mostly in patients with IOL decentration or tilt due to capsular phimosis or a capsulotomy that was made too big or too small (Figure 2). The perfect, predictable diameter, centration, and roundness of laser capsulotomies has now led to the design of a new IOL that uses these qualities to further optimize lens function.

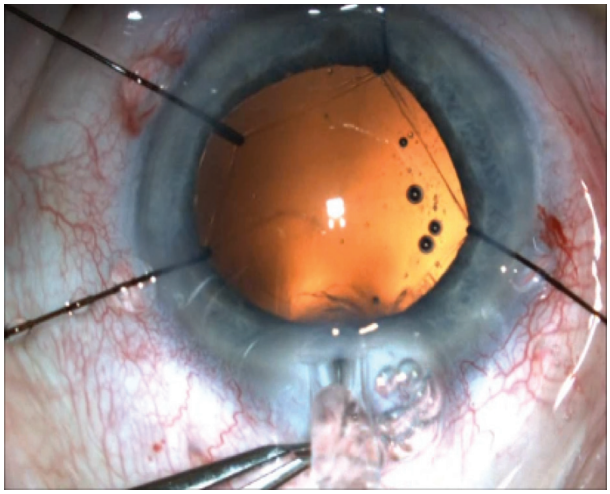

Figure 1. Iris hooks stabilize the capsule in an eye after femtosecond laser capsulotomy. Note the stretching of the capsule.

A NEW APPROACH

I have been using the Femtis Laser Lens (Oculentis) for more than 2 years now,[1] and, in more than 100 implantations, have not had one lens-related complication. The key to the design of the IOL is that the lens' four additional anterior haptics—two large longitudinal and two smaller latitudinal—are easily enclaved in front of the capsulotomy. The learning curve for the positioning of the four additional haptics is short, and the surgeon needs only a simple hook as an extra instrument.

In my opinion, the best diameter for the capsulotomy is around 4.8 to 5 mm. Implantation of the lens into the capsulotomy can be performed under an OVD, which is injected into the anterior chamber for stabilization. For the enclavation of the additional four haptics, I recommend use of an OVD, keeping in mind that it must then

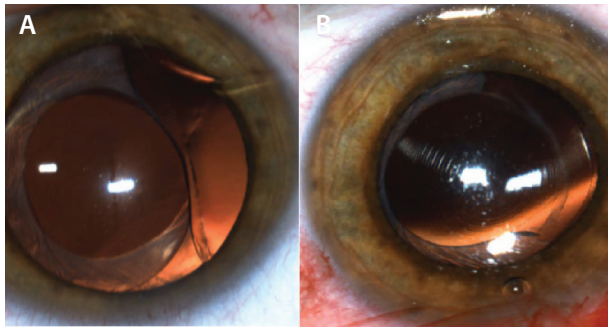

Figure 2. Decentration of a multifocal IOL before (A) and after (B) rotation.

The Lens

Femtis Laser Lens

OCULENTIS

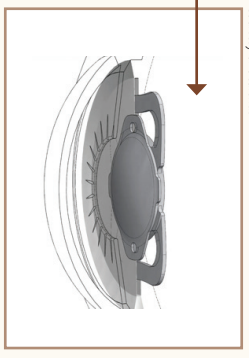

Courtesy of Oculentis

- Overall diameter 10.5 mm; optic diameter 5.7 mm
- Hydrophilic acrylic material with 25% water content
- Modified plate haptic design in hydophilic acrylic material with sharp posterior edge
- Four additional anterior haptics (two large longitudinal and two smaller latitudinal) are enclaved into the capsulotomy to secure and center the IOL
- Aberration-neutral aspheric optic design
- Biconvex at 22.00 D equiconvex

For more information:
http://bit.ly/oculentis0117

be removed completely, even from behind the IOL. This maneuver is as easy as with any other lens of a plate-haptic design, and, after a short learning curve, it takes an average of not more than 30 seconds.

Figure 3. Femtis Laser Lens 24 month after implantation.

FEMTIS STUDY

I performed a study of the Femtis in more than 90 eyes of 66 cataract patients (mean age, 75 years) with follow-up of up to 24 months (Figure 3). The Lensar Laser System (Lensar) was used for capsulotomy creation and the OS3 system (Oertli Instrumente) for phacoemulsification in all cases. No lens-related problems were seen with implantation into the capsular bag or with enclavation of the four additional haptics of the Femtis IOL. Because I use Mydriasert (tropicamide and phenylephrine HCl; Thea Pharmaceuticals) in every femtosecond laser case, eyes have on average a pupil diameter greater than 6 mm, so enclavation is easy and the risk of iris capture is small. Even in pupils smaller than 5 mm, enclavation is possible, but it takes more time.

The safety profile is important in early experience with a new IOL design, and there were no issues with intraoperative safety with this IOL in this case series. There were also no safety problems postoperatively, particularly with postoperative iris capture; however, other centers have reported that this occurred in some cases immediately postoperatively. One explanation is that this happens only if the iris capture occurs in the operating room. Therefore, the surgeon must look carefully in every single case to ensure that the two large longitudinal haptics are not in front of the iris.

Regarding refractive and functional results, all measures were comparable to those in our standard cataract surgery population. The average IOL power in the Femtis IOL series was 20.00 D. Spherical equivalent

AT A GLANCE

- The design of the Femtis Laser Lens is characterized by four additional haptics that are enclaved in front of the capsulotomy.
- In the author's study, there were no signs of pigment epithelium problems or pigmentary glaucoma.
- Another promising idea that may result from the IOL design of the Femtis is the possibility of using the additional anterior haptics for the fixation of a new type of sulcus-independent add-on IOL.

preoperatively was a mean 0.34 D (range, -5.50 to 3.50 D) and postoperatively a mean 0.26 D (range, -0.50 to 0.75 D). CDVA increased from 0.5 preoperatively to 0.9 postoperatively.

Lens decentration was not seen in any cases during follow-up. The enclavation of the capsulotomy behind the additional haptics led to no complications, and the optic was free of any overlapping of the anterior capsule in all cases.

In our initial experience with this new design, we were somewhat concerned about the question of pigment dispersion due to possibility of the haptics in front of the capsular bag touching the iris pigment. During follow-up, this concern disappeared, as we saw no case with either pigment epithelium problems or pigmentary glaucoma. In general, our concerns in this regard were not significant because we have used a supplementary IOL with sulcus implantation for years. With these lenses, the entire optic and haptic are in front of the capsule, and we have seen no iris-related problems.

LOOKING FORWARD

Summarizing these key preliminary findings, it is fair to say that the Femtis Laser Lens design is safe intra- and postoperatively.

A multicenter study of this lens is ongoing, but I believe that the design will prove to be stable regarding postoperative rotation, which will be a benefit for toric versions of this IOL. Additionally, the possibility of experiencing less IOL tilt and decentration may be a benefit in multifocal versions, and the lack of overlap of the anterior capsule over the lens optic may be advantageous in younger patients with large pupils, leading to less risk of dysphotopsia.

I have also started to use the Comfort model of the Laser Lens with promising results, which must be verified in a prospective comparison to the standard model. The Lentis Comfort IOL models (Oculentis) provide improved depth of focus, contrast, and color performance over the standard Lentis IOL models, according to the manufacturer.

IDEAL CANDIDATE

In general, every patient undergoing LACS is a candidate for the Femtis. Even highly myopic patients with large-diameter capsular bags may benefit from this design due to the reduced risk of decentration.

In situations that result in a smaller-diameter capsulotomy (less than 4.5 mm), problems regarding enclavation may be encountered. Also, patients with loose or weak zonules are not recommended for this plate haptic–based IOL system because the implantation into the bag and the extra maneuvers for the enclavation of the four additional haptics may lead to increased stress on the zonules.

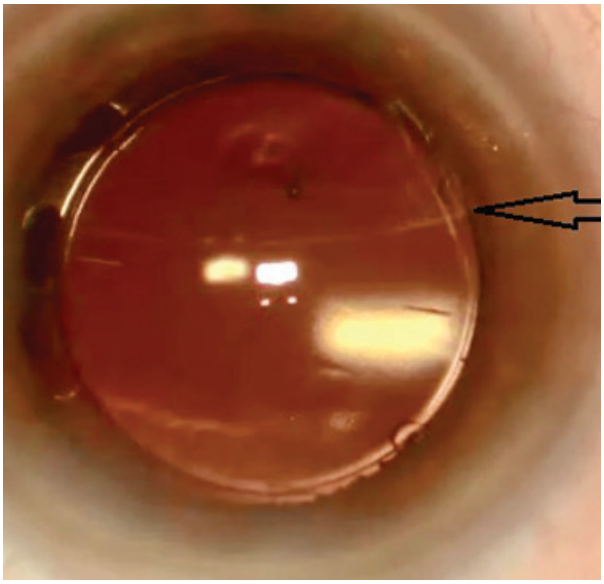

Figure 4. Femtis Laser Lens in an eye with rupture of the posterior capsule (arrow).

It will be interesting to observe the performance of this lens in the event of defects in the posterior capsule. Even if posterior capsular rupture is rare, it occurs in every surgeon's daily life from time to time. I recently implanted the Femtis Laser Lens in an eye with a moderate rupture in the capsular bag and was able to enclave the additional haptics without problems (Figure 4).

More experience is necessary to determine whether the additional haptics may help to stabilize the lens sufficiently, decreasing the need for sulcus-fixated lenses in the event of posterior capsular rupture.

Another promising idea that may result from this design is the possibility of using the additional anterior haptics for the fixation of a new type of sulcus-independent add-on IOL, which could be monofocal, multifocal, or toric. I hope to be able to report on this idea in future.

TAKE-HOME MESSAGE

The new Femtis Laser Lens has four additional haptics that are enclaved into the capsulotomy to allow perfect centration in the center of capsulotomy. Results with this novel lens design have been promising in regard to safety and efficacy. ■

1. Holland D. First experiences with the Lentis Laser Lens at the Augenklinik Bellevue in Kiel, Germany. Paper presented at: the European Society of Cataract and Refractive Surgeons Annual Meeting; September 13-17, 2014; London.