THE ABCs OF ACEs

A variety of surgical approaches has been described in the management of advanced corneal ectasia.

BY PRAFULLA K. MAHARANA, MD; VISHAL JHANJI, MD; AND RASIK B. VAJPAYEE, FRCS(EDIN), FRANZCO

Corneal ectasia is a general term to describe a group of disorders characterized by progressive thinning, bulging, and distortion of the cornea. The corneal ectatic disorders commonly encountered in clinical practice are keratoconus, pellucid marginal degeneration (PMD), Terrien marginal degeneration (TMD), keratoglobus, and ectasias occurring after corneal refractive surgery (PRK, RK, and LASIK) or PKP.[1]

The term *advanced corneal ectasia* (ACE) is well defined in the case of keratoconus, but, in other disorders such as PMD or TMD, there are no defining criteria. According to the classification proposed by Krumeich et al, an eye with advanced keratoconus has a keratometry reading (K) of greater than 55.00 D, an unmeasurable refraction, central corneal scarring, and corneal thickness less than 200 µm at the thinnest point.[2] For other disorders, it can be said that advanced ectasia is the stage at which routine procedures are not sufficient to treat the underlying condition.

The management of such cases is a major challenge for the corneal surgeon because it not only affects visual acuity but also decreases corneal strength. The aim of treatment in such cases is to improve visual acuity and to provide tectonic support to the cornea. The management of early corneal ectasia is well established in the literature, but management of ACE is still challenging because there are no definitive guidelines. This article describes our approach to the management of ACE, including diagnosis and treatment options.

AT A GLANCE

- The management of advanced corneal ectasia (ACE) is a major challenge because it not only affects visual acuity but also decreases corneal strength.
- Surgical options for the management of ACE include ICRSs; large-diameter PKP; LK alone; LK in several combinations with PKP; TILK; and wedge resection.
- The choice of procedure must be based on the clinical severity of the ectasia and the surgeon's experience.

PREOPERATIVE INVESTIGATIONS

A detailed investigation of these cases is required before proceeding to surgery, with the following parameters assessed.

Corneal thickness and areas of maximum thinning. This information is important in order to plan the type of surgery and to be aware of the site where the chance of perforation is greatest during surgery. Ultrasonic pachymetry, Orbscan II (Bausch + Lomb), Pentacam (Oculus), and anterior segment OCT can be used for this purpose.[1]

Corneal topography. Various tools can be used to map corneal topography, including Placido disc–based videokeratography, slit-scanning (Orbscan II), and Scheimpflug imaging (Pentacam). The Pentacam offers the advantage of providing precise corneal thickness and posterior elevation measurements with good repeatability.[1,3]

NONSURGICAL MANAGEMENT OPTIONS

Treatment of ACE is challenging. Various treatment options, both nonsurgical and surgical, have been tried. There are two main nonsurgical management options, described below.

Optical correction. Spectacle correction has little or no role in ACE. Spectacles may be prescribed to selected patients who are intolerant of contact lenses and are not willing to undergo surgery.

Contact lenses. Newer-generation lenses such as Rose K lenses (Menicon), scleral lenses, Prosthetic Replacement of the Ocular Surface Ecosystem (PROSE; BostonSight), and the Boston Ocular Surface Prosthesis (BOSP; BostonSight) have shown promise in ACE in early studies.[4] These lenses, which offer improvements in visual acuity and good stability, may be an option for patients for whom conventional treatments have failed (see *Scleral Contact Lens Options in ACE*).

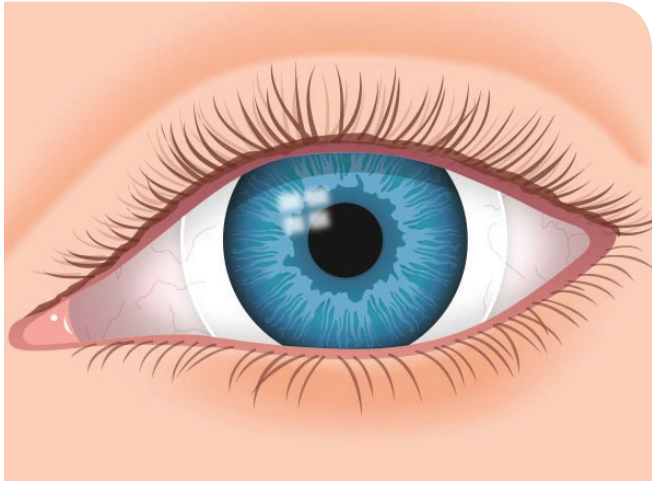

Image courtesy of All About Vision

SCLERAL CONTACT LENS OPTIONS IN ACE

SCLERAL LENSES

What: Rest on the sclera and do not touch the cornea and limbus, leaving a clear area between the lens and the cornea and thereby avoiding the major complications associated with rigid gas permeable lens–fitting in ACE

Why: Good centration and stability and improved visual acuity

Why not: High cost; reduced tear exchange; and insertion and removal, which require considerable practice[1]

PROSE

What: Nonfenestrated scleral lens filled with fluid prior to insertion in the eye

Why: High success rate in terms of satisfactory fit and impact on visual acuity

When: Alternative to PKP for patients with corneal ectasia who are contact lens–intolerant[1,2]

BOSP

What: Fluid-filled scleral lens

When: Useful in patients with irregular astigmatism for whom the fitting of a regular contact lens is not possible[1,2]

1. Maharana PK, Dubey A, Jhanji V, Sharma N, Das S, Vajpayee RB. Management of advanced corneal ectasias. *Br J Ophthalmol*. 2015;100(1):34-40.
2. Lee JC, Chiu GB, Bach D, et al. Functional and visual improvement with prosthetic replacement of the ocular surface ecosystem scleral lenses for irregular corneas. *Cornea.* 2013;32:1540-1543.

SURGICAL MANAGEMENT OPTIONS

Most cases of ACE require surgery for visual rehabilitation and for improving corneal strength. Three challenges in surgical management of ACE are prevalent:

- Due to the involvement of the paracentral and peripheral cornea, a large graft with increased proximity to the limbus is required, increasing the chances of graft rejection;
- Extreme corneal thinning makes suturing difficult and increases the chances of intraoperative Descemet membrane perforation; and
- All the procedures (described below) are technically difficult with a steep learning curve.

Intrastromal corneal ring segment (ICRS). ICRS implantation is a method of improving contact lens tolerance and BCVA for patients with corneal ectasia and a clear cornea.[1,5] ICRSs are commonly indicated for patients with moderate ectasia. Recently, Intacs SK (Addition Technology) for severe keratoconus has been introduced, and this device can be useful in ACE. Intacs SK segments have a smaller inner diameter, 6 mm, compared with 6.8 mm for standard Intacs. They also have an elliptical cross-section, in contrast with the hexagonal cross-section of standard Intacs.[1,5] Since the introduction of Intacs SK, many authors have used the segments in eyes with ACE with favorable outcomes and without significant complications. However, the long-term results and their role in indications other than keratoconus need further validation.

Large-diameter PKP. A large-diameter PKP is done in eyes with ACE so as to include the thinned-out corneal periphery.[1,6] Problems with such grafts include an increased risk of rejection due to proximity to the limbus and severe postoperative astigmatism associated with a decentered graft.

Lamellar keratoplasty (LK). Crescentic LK, compressive C-shaped LK, and modified deep LK are variations of the LK technique that have been described for treatment of ACE. In general, a match-and-patch lamellar graft procedure is done. Precise lamellar dissection of the recipient bed is done to achieve vertical margins and an even stromal bed depth. A lamellar donor, undersized by 0.25 to 0.50 mm, is then sutured to the recipient bed. This results in flattening and reduction of ectasia.[1,7]

LK with PKP. This combination procedure unites the advantages of a lamellar graft and a full-thickness graft. A large-diameter lamellar graft can provide tectonic support to the weakened peripheral host cornea, and a central small-diameter, full-thickness graft can provide excellent visual outcomes.[1]

Simultaneous peripheral crescentic LK and central PKP. In this combination, LK and PKP are done in the same sitting. The LK is done first to restore normal thickness to the peripherally thinned cornea and to enable good edge-to-edge apposition at the time of PKP, which is performed immediately subsequent.[8] The advantage of this approach is that it avoids the need for two separate donor

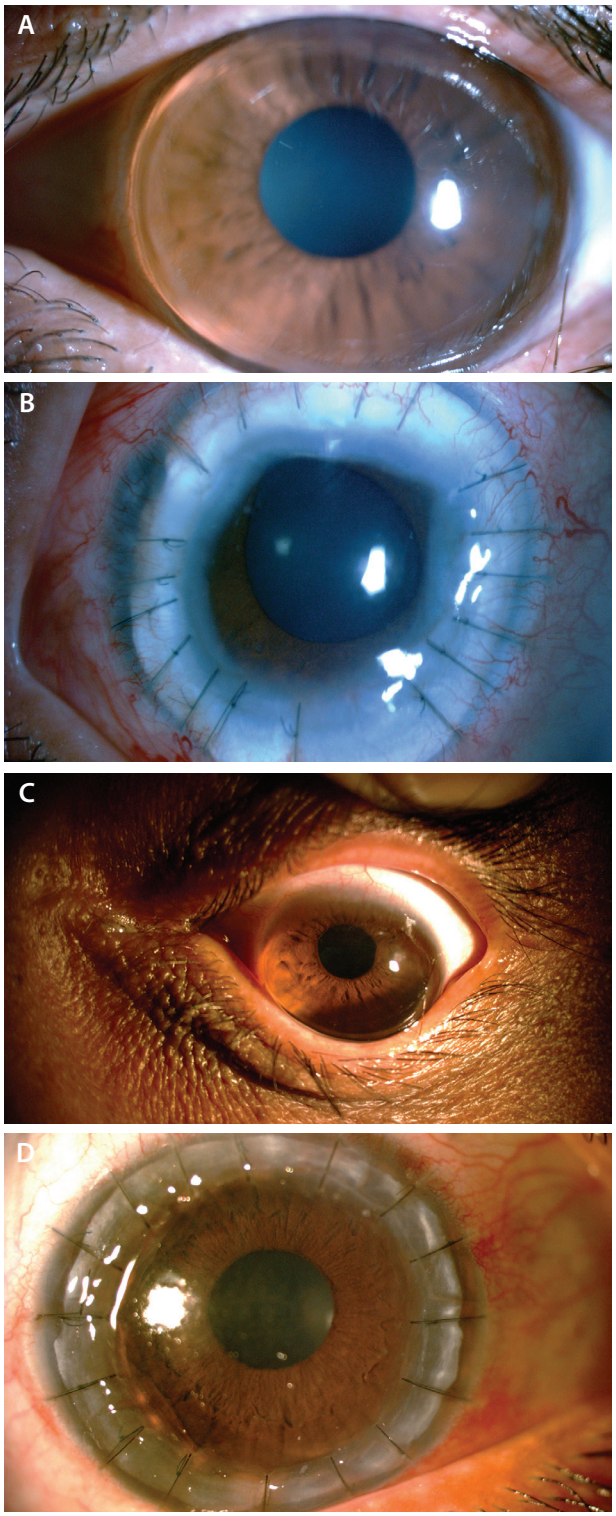

Figure 1. TILK in two eyes (A, C) with advanced corneal ectasia. The flange of the donor lenticule is tucked into the intrastromal pocket of the host cornea, and the graft is sutured to the host (B, D).

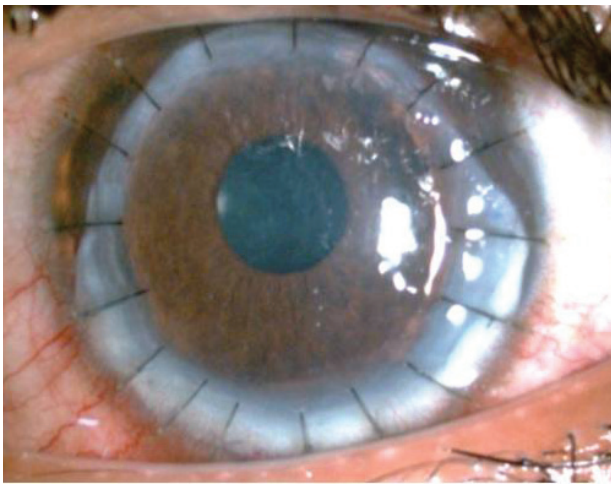

Figure 2. In cases of PMD only, tucking is done for 180° inferiorly.

corneas, as would be the case with sequential LK followed by PKP. The chief drawback of this surgery is its technical difficulty.[1]

Tectonic LK followed by secondary PKP. In this approach, a tectonic LK is performed, and secondary PKP is done in a second surgical session, usually after 6 months.[9]

Tuck-in lamellar keratoplasty (TILK). TILK is a special technique of LK for use in eyes with advanced peripheral corneal–thinning disorders such as PMD, keratoglobus, post-PKP ectasia, and eyes with a combination of keratoconus and PMD.[10,11] It involves central anterior stromal lamellar resection followed by creation of a peripheral intrastromal pocket circumferentially in the corneal periphery up to a point 0.5 mm from the limbus. The donor tissue is prepared so that it has a central full-thickness graft with a peripheral partial-thickness flange of about 2.5 to 3 mm. The flange of the donor lenticule is tucked into the intrastromal pocket of the host cornea, and the graft is sutured to the host (Figure 1). In cases of PMD only, tucking is done for 180° inferiorly (Figure 2).

The central full-thickness graft provides tectonic support to the central cornea, while the thin peripheral flange tucked into the intrastromal pocket integrates into the host and provides tectonic support to the peripheral cornea. Moreover, there is no damage to the recipient's limbal stem cells, as dissection of the limbal region is avoided; this subsequently promotes healing of the epithelium at the graft-host junction. The limitations of this technique are its steep learning curve and the residual stroma that can affect the quality of final visual acuity.

In a series including keratoconic eyes with PMD (n=8) and keratoglobus (n=4), we obtained excellent results following TILK. Postoperatively, all patients had BCVA better

PREVENTION OF ACE

Midstromal isolated Bowman layer transplantation is a new surgical technique intended to stabilize ectasia in eyes with advanced keratoconus.[1-3] It involves transplantation of an isolated donor Bowman layer of 9 to 11 mm diameter into a stromal pocket using a special glide. The midstromal pocket is created over 360° using manual dissection.

Midstromal transplantation of the isolated Bowman layer leads to stabilization of the ectasia due to the wound-healing effect between the host stroma and the transplanted Bowman layer. Additionally, the Bowman layer itself adds to the tectonic strength of the cornea.[2,3] Van Dijk et al have reported reduction and stabilization of corneal ectasia with this technique in two published series; one study included 20 eyes, and the other included 10 eyes with progressive, advanced keratoconus.[2,3] Although initial results are encouraging, long-term studies are needed to establish the safety and efficacy of this procedure.

1. Maharana PK, Dubey A, Jhanji V, Sharma N, Das S, Vajpayee RB. Management of advanced corneal ectasias. *Br J Ophthalmol.* 2015;100(1):34-40.
2. Van DK, Liarakos VS, Parker J, et al. Bowman layer transplantation to reduce and stabilize progressive, advanced keratoconus. *Ophthalmology*. 2015;14:161-164.
3. Van DK, Parker J, Tong CM, et al. Midstromal isolated Bowman layer graft for reduction of advanced keratoconus: a technique to postpone penetrating or deep anterior lamellar keratoplasty. *JAMA Ophthalmol*. 2014;132:495-501.

than 20/80, mean K decreased from 57.54 to 46.36 D, and mean spherical equivalent decreased from -7.80 to 1.23 D.[12] Similarly, in another series including cases of post-PKP corneal ectasia (n=4), mean K decreased from 59.67 to 43.50 D, with significant improvement in BCVA from a mean of 0.05 to 0.34 (Snellen decimal).[11]

Wedge resection. This technique is useful when ectasia is confined to a small sector of corneal periphery.[12,13] It has several advantages over corneal graft, including preservation of normal central cornea, no risk of graft rejection or interface haze, better wound strength, and shorter visual rehabilitation time.[12,13] However, postoperative unstable astigmatism is an issue due to persistent tension at the sutured wound. Various modifications have been described to improve the outcome of wedge resection, such as wedge resection followed by complete (limbus to limbus) or partial host deep lamellar dissection; and corneal wedge resection combined with paired, opposed clear corneal penetrating relaxing incisions. The relaxing incisions prevent the astigmatic drift normally seen following wedge resection.[1]

CONCLUSION

Management of ACE is a challenge for any corneal surgeon. Over the past decade, several new surgical techniques have evolved with varying success. We have been performing our preferred technique, TILK, for the past 10 years in eyes with ACEs with excellent results. However, it must be emphasized that one's choice of procedure must be based on the clinical severity of the ectasia and on the surgeon's experience. ■

1. Maharana PK, Dubey A, Jhanji V, Sharma N, Das S, Vajpayee RB. Management of advanced corneal ectasias. *Br J Ophthalmol.* 2015;100(1):34-40.
2. Ishii R, Kamiya K, Igarashi A, et al. Correlation of corneal elevation with severity of keratoconus by means of anterior and posterior topographic analysis. *Cornea*. 2012;31:253-258.
3. Belin MW, Ambrosio R. Scheimpflug imaging for keratoconus and ectatic disease. *Indian J Ophthalmol*. 2013;61:401-406.
4. Velazquez FFJ. Kerasoft IC compared to Rose-K in the management of corneal ectasias. *Cont Lens Anterior Eye*. 2012;35:175-179.
5. Lee JC, Chiu GB, Bach D, et al. Functional and visual improvement with prosthetic replacement of the ocular surface ecosystem scleral lenses for irregular corneas. *Cornea*. 2013;32:1540-1543.
6. Speaker MG, Arentsen JJ, Laibson PR. Long-term survival of large diameter penetrating keratoplasties for keratoconus and pellucid marginal degeneration. *Acta Ophthalmol Suppl.* 1989;192:17-19.
7. Cheng CL, Theng JT, Tan DT. Compressive C-shaped lamellar keratoplasty: a surgical alternative for the management of severe astigmatism from peripheral corneal degeneration. *Ophthalmology*. 2005;112:425-430.
8. Rasheed K, Rabinowitz YS. Surgical treatment of advanced pellucid marginal degeneration. *Ophthalmology*. 2000;107:1836-1840.
9. Lake D, Hamada S, Khan S, et al. Deep anterior lamellar keratoplasty over penetrating keratoplasty for host rim thinning and ectasia. *Cornea*. 2009;28:489-492.
10. Kaushal S, Jhanji V, Sharma N, et al. "Tuck in" lamellar keratoplasty (TILK) for corneal ectasias involving corneal periphery. *Br J Ophthalmol*. 2008;92(2):286-290.
11. Vajpayee RB, Jhanji V, Beltz J, et al. "Tuck In" lamellar keratoplasty for tectonic management of post keratoplasty corneal ectasia with peripheral corneal involvement. *Cornea*. 2011;30:171-174.
12. Busin M, Kerdraon Y, Scorcia V et al. Combined wedge resection and beveled penetrating relaxing incisions for the treatment of pellucid marginal corneal degeneration. *Cornea*. 2008;27:595-600.
13. Maccheron LJ, Daya SM. Wedge resection and lamellar dissection for pellucid marginal degeneration. *Cornea*. 2012;31:708-715.

Vishal Jhanji, MD
- Associate Professor, Departments of Ophthalmology and Visual Sciences, The Chinese University of Hong Kong, Hong Kong
- vishaljhanji@gmail.com
- Financial disclosure: None acknowledged

Prafulla K. Maharana, MD
- Assistant Professor, Department of Ophthalmology, All India Institute of Medical Sciences, Bhubaneswar, India
- drpraful13@gmail.com
- Financial disclosure: None acknowledged

Rasik B. Vajpayee, FRCS(Edin), FRANZCO
- Professor of Ophthalmology, Vision Eye Institute, Royal Victorian Eye and Ear Hospital, North West Academic Centre, University of Melbourne, Australia
- rasikv@unimelb.edu.au
- Financial disclosure: None acknowledged