BUFFET OR À LA CARTE FOR LASER ENHANCEMENTS?

Pricing options, strategies for talking to patients, and clinical pearls for mastering enhancements after cataract surgery.

BY EVA LIANG, MD; AND SHANNON M. WONG, MD


Every refractive cataract surgeon wrestles with the question of how to accommodate the occasional need for laser vision correction (LVC) after cataract surgery. Surgeons must determine the best way to price enhancements (in other words, to include them in a refractive package or not), they must convey enhancement policies upfront to patients, and they must choose the most appropriate procedure. This article discusses two ways of approaching enhancements and shares clinical pearls for performing LVC in a refractive cataract surgery practice.

BUFFET VERSUS Á LA CARTE

Buffet pricing. Including LVC enhancements in a laser-assisted cataract surgery (LACS) or premium IOL package is the "all-you-can-eat buffet" approach. Many surgeons find that this method adds value to their refractive packages and simplifies patient counseling, but it can get expensive for the surgeon if his or her enhancement rate is high. The approach may work best for practices with an older patient population. These patients may be highly reassured by the all-inclusive rate. They also may be less likely to pursue enhancements because they are willing to tolerate small amounts of residual refractive error or are simply more conservative about undergoing additional surgery.

À la carte. A second approach is to charge patients a separate (but reduced) fee for LVC enhancement, making touch-ups an "à la carte" option that patients pay for only when needed. Many surgeons feel this is more fair to patients and that it reinforces the message that surgical services are not free. This method may make it easier to price the premium or LACS package competitively, and it gives the surgeon great discretion in waiving or reducing the enhancement fee in the case of an upset patient or surprise outcome (Figure 1).

SET THE TABLE

Transparency in explaining the enhancement policy to

GOOD **Conventional Cataract Surgery**

Cataract surgery is performed with manual instruments and traditional blades combined with a conventional intraocular lens implant. Glasses should be expected for reading, working on the computer and perhaps even at distance.

Optional Selection ORA – Intraoperative Wavefront Aberrometry-Verification of Lens Power

BETTER **Custom Cataract Surgery**

The Custom Cataract package includes additional diagnostic testing and advanced pre-surgical planning beyond those required for conventional surgery. Includes ORA (Intraoperative Wavefront Aberrometry-Verification of Lens Power)

The use of Femtosecond Laser in refractive cataract surgery to create arcuate corneal incisions to surgically correct low to mid-level astigmatism with a conventional intraocular lens.
OR
Intraocular lens upgrade from a conventional lens to a presbyopia correcting or astigmatism-correcting lens.

BEST **Premium Cataract Surgery**

The Premium Cataract Surgery Package includes additional diagnostic testing and advanced pre-surgical planning beyond those required for conventional surgery. Includes ORA (Intraoperative Aberrometry-Verification of Lens Power) and extended post-operative care to include Laser Vision Correction if needed.

The use of a Femtosecond laser in refractive cataract surgery to create arcuate corneal incisions to surgically correct low to mid-level astigmatism **COMBINED** with an Intraocular lens upgrade from a conventional lens to presbyopia correcting or astigmatism-correcting lens(for higher levels of astigmatism)

Figure 1. A key difference between the *better* and *best* strategies on this pricing menu is the use of both a femtosecond laser and a premium lens in the *best* package, whereas the *better* package includes only one of those upgrades. Both the *better* and *best* packages include LVC enhancement if needed.

(Courtesy of Eva Liang, MD.)

AT A GLANCE

- Transparency in explaining the enhancement policy to patients is essential, and it is prudent to discuss with patients the likelihood of needing LVC after cataract surgery.
- Refractive cataract surgeons who own an excimer laser are at an advantage in terms of cost, flexibility, and patient perceptions.

patients is essential, particularly in practices taking the à la carte approach. It is prudent to discuss with patients the likelihood of needing LVC after cataract surgery and the price of the procedure before the initial cataract surgery is performed to avoid bad feelings if a touch-up is needed. When discussing refractive cataract packages, it may be helpful to show the portion of the procedure covered by insurance for a medically necessary cataract, so that patients realize they are getting a discount on refractive surgery because of their cataracts.

Practices taking the buffet approach may want to market the all-inclusive nature of their packages as a practice differentiator, or they may want to mitigate costs by simply performing enhancements at no charge but not encouraging enhancements by advertising that fact.

ENHANCEMENT TIPS

Refractive cataract surgeons who own an excimer laser and can perform the full range of LVC procedures are at a distinct advantage in terms of cost, flexibility, and patient perceptions. Even if one is referring enhancement patients to a colleague or performing just the occasional surface procedure, it is helpful to understand some common scenarios and considerations for LVC enhancement.

Tip No. 1: Consider LASIK as the first option. PRK is an effective LVC option and one that cataract surgeons may be more comfortable learning than LASIK, but the delayed healing is a disadvantage, especially in young patients with high expectations. If either is an option, in most cases, there is no reason not to do LASIK.

Tip No. 2: An enhancement should follow suit of the prior refractive surgery. A prior LASIK flap, even

(Continued on page 29)

WATCH IT NOW

Using the iFs laser, Eva Liang, MD, creates a LASIK flap in an eye with a previous limbal relaxing incision (A) and then lifts the flap (B).

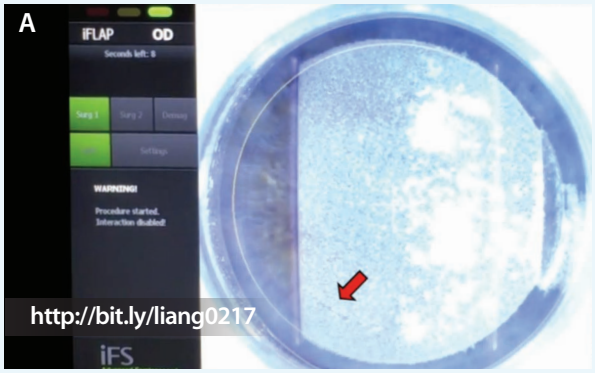

ICING ON THE CAKE

By Shannon M. Wong, MD

My staff and I have developed a great source of free marketing for our practice: **Right after we remove the draping and the patient is sitting up, staffers take a smartphone photo of me with the patient, both of us smiling and giving a thumbs-up** (Figure 1). In the photos, my practice's website is clearly visible on the surgical microscope in the background. My staff emails these photos to patients so they can easily post them to Facebook, the most common social media platform for those aged older than 50 years. A patient might get 50 to 100 "likes" for that postoperative photo—likes that, more often than not, are coming from people in the same age group who are also potential surgical candidates.

Figure 1. Dr. Wong and a happy postoperative patient pose in front of the microscope.

THE PICTURE FRAME AND SCREWDRIVER MANEUVERS AND OTHER HELPFUL TIPS

Successful strategies with the Malyugin Ring 2.0.

BY BORIS MALYUGIN, MD, PHD

When I developed the Malyugin Ring (MicroSurgical Technology) as a means to ensure uniform dilation of the pupil and to provide circumferential protection of the iris, I did not realize just how popular the device would become. Yet, over the years, many of my colleagues have shared with me how frequently they rely on the device in both routine and challenging cataract cases.

I often hear from colleagues about the ease with which the Malyugin Ring can be implanted. I also hear, however, criticisms that the device cannot fit through a corneal incision smaller than 2.2 mm. This is true, unless the technically challenging wound-assisted injection technique is employed. In an attempt to create an even friendlier device, the original Malyugin Ring has been remodeled and reengineered so that it can be implanted through a smaller incision. Right now that incision size is 2 mm (Figure 1A), but, in the future, there is hope that it will fit through an even smaller incision.

The dimensions of the Malyugin Ring 2.0 are similar to those of the original device, with slightly smaller thread and scrolls. The ring is still supplied with its own injector, but the injector design is new, in order to allow the ring to be inserted more easily through the smaller incision (Figure 1B). The latest version of the Malyugin Ring is made from 5-0 polypropylene, which is thinner and more flexible than the 4-0 polypropylene of the original. The device continues to be available in diameters of 6.25 and 7 mm.

HELPFUL TIPS

Tip No. 1. I have found it helpful to inject a highly viscous OVD such as Healon5 (Abbott) behind the iris at four points corresponding to the intended position of the scrolls on the iris margin.

Tip No. 2. When injecting the leading scroll, I position the injector tip close to the iris margin, in order to better control engagement of the scroll with the iris.

Tip No. 3. In cases of unexpected intraoperative miosis, the Malyugin Ring must be implanted after the anterior capsulorrhexis is created. In this situation, it is important to ensure that the ring is not engaging the anterior capsule margin. I have found that a technique I call the *picture frame maneuver* is extremely helpful. Using the sideport instrument, the ring can be displaced in any direction, much like moving a picture frame. Restricted movement in certain directions usually corresponds with areas where the scroll is catching the anterior capsule. Once this is recognized, I use the ring manipulating tool to catch the scroll and retract it toward the center of the anterior chamber, disengaging it from the iris and capsule. Then I can lift and position the ring back in contact with the pupillary edge. This technique can be repeated if more than one of the ring's scrolls is catching the anterior capsule. I also use the picture frame maneuver to ensure correct positioning of the Malyugin Ring.

Tip No. 4. As soon as the IOL is positioned in the capsular bag, I remove the Malyugin Ring with a technique that I call the *screwdriver maneuver*. First, I introduce the ring manipulating tool through either the main or sideport incision. Second, once

AT A GLANCE

- The Malyugin Ring has been modified to enable surgeons to insert the device through a 2-mm incision.
- The new model is easier to implant and to remove than its predecessor.
- The enhanced flexibility of the device is friendlier to iris tissue compared with the previous version of the device.

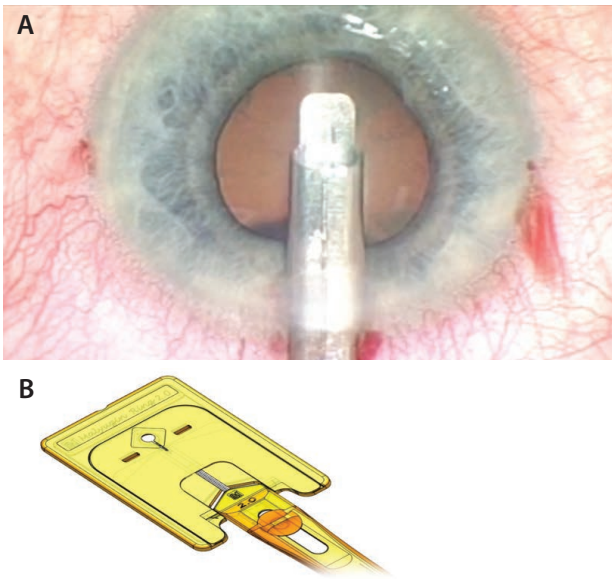

Figure 1. The Malyugin Ring 2.0 is injected through a 2-mm incision (A). A new injector and holder allow the ring to be inserted more easily through the smaller incision (B).

the ring manipulating tool catches one of the scrolls, I pull it toward the center of the pupil, then, lifting the scroll slightly, place it on top of the anterior surface of the iris. Next I rotate the ring counter-clockwise to disengage the next scroll. Once the newly released scroll is caught by the manipulator, I again rotate the entire ring counter-clockwise, releasing the next scroll. Once all scrolls are released from the iris margin, the Malyugin Ring will be positioned flat on top of the iris. I then use the inserter to remove the ring from the eye and completely remove the OVD from the anterior chamber.

USE IN LACS

The Malyugin Ring 2.0 can also be used in laser-assisted cataract surgery (LACS) to help combat the inflammation and subsequent pupillary miosis that can occur as a response to the laser energy. In some cases, pupil size can constrict to 3 mm after the applanation with the patient interface and during the initiation of phacoemulsification.

During LACS, when the pupil is not wide enough, I place the patient under the laser only after the Malyugin Ring is inserted. In such cases, ideally, the incision will be self-sealing and as small as possible to avoid chamber collapse in the time leading up to laser docking. ■

Boris Malyugin, MD, PhD
- Professor of Ophthalmology and Deputy Director General, S. Fyodorov Eye Microsurgery State Institution, Russia
- Member, *CRST Europe* Editorial Board
- boris.malyugin@gmail.com
- Financial disclosure: Royalties (MicroSurgical Technology)

(Continued from page 25)

an old one, can usually be lifted for an enhancement. If the patient has had prior PRK surgery, any enhancement should also be a surface procedure. A slightly thicker than usual (120 µm) femtosecond laser flap can be created over old RK incisions, as long as there are no more than eight incisions; otherwise, we opt for PRK. LASIK is also possible in the presence of astigmatic keratotomy (AK) incisions performed during LACS. In many cases, the limbal relaxing or AK incisions will be located within the LASIK flap's diameter, and the iFS femtosecond laser (Abbott) can easily cut through the limbal relaxing or AK incisions.

Tip No. 3: Use custom enhancements whenever possible. We prefer custom enhancements whenever possible. Most pseudophakic eyes, including those with presbyopia-correcting or toric IOLs, can be captured and treated with either the WaveScan or iDesign aberrometer (both from Abbott). Taking extra care during refractive cataract surgery to polish the posterior surface of the anterior capsule will help prevent any opacification that might obscure wavefront imaging in the future.

Tip No. 4: Know when to perform the enhancement. Timing may depend on the age and expectations of the patient population. Although many surgeons prefer to wait 3 months after cataract surgery, others perform enhancements as early as 1 month postoperatively to achieve the final visual acuity quicker. It is essential that refractive stability be reached prior to enhancement.

LVC after Crystalens implantation. An Nd:YAG capsulotomy should almost always be performed prior to an LVC enhancement in an eye that has a Crystalens (Bausch + Lomb) to avoid a capsulotomy-related refractive shift after LVC. In these cases, if the patient is mildly myopic, it may also be beneficial to conduct a 1-week contact lens trial to make sure the patient understands the effect of losing near vision.

CONCLUSION

Becoming more comfortable with LVC enhancements will increase your confidence in performing LACS and implanting premium IOLs. We have found it enormously freeing to know that, if the outcome of a refractive cataract surgery procedure is not as expected or desired, the problem can be fixed for the patient. As long as enhancement plans are thought out in advance and clearly communicated to the patient, everyone wins. ■

Eva Liang, MD
- Medical Director, Center for Sight, Las Vegas
- eva.liang@c4slv.com
- Financial disclosure: Consultant (Abbott, Bausch + Lomb)

Shannnon M. Wong, MD
- Austin Eye Clinic, Texas
- shannon@austineye.com
- Financial disclosure: None acknowledged