ROCK STARS

GOOD, BETTER, AND BEST:

Rating Phaco Chop Techniques

Even in the age of the femtosecond laser, chopping remains vital for hard cataracts.

BY CYRES KEIKI MEHTA, MS(OPHTH), MCH(OPHTH)

Dismembering the nucleus is a key maneuver in phacoemulsification. When confronted with anything harder than an aspirable grade 1 nucleus, splitting the lens into bits greatly decreases the quantum of ultrasound expended in the eye. Howard V. Gimbel, MD, first published his technique of divide and conquer nucleofractis in 1991.[1] In that landmark article, he described trenching for softer cataracts and cratering followed by division for harder cataracts. Trenching relied on visualizing the red reflex and debulking the central part of the lens so that, when force was applied by a spatula held parallel to the phaco tip, the nucleus divided in half.

With the advent of the horizontal direct chop technique of Kunihiro Nagahara, MD, in 1993, nuclear handling changed again.[2] Chopping in its many variants is basically a combination of the original Nagahara horizontal chop, the quick chop of Nichamin,[3] and the lens salute chop of Mehta,[4] in which the chopper moves from the posterior of the lens to the anterior. The lens salute chop technique has been published in a number of textbooks and presented at more than 50 instructional courses conducted by me at both the European Society of Cataract and Refractive Surgeons (ESCRS) and American Society of Cataract and Refractive Surgery (ASCRS) meetings from 2003 to 2012.

This article provides my own personal rating of a number of chopping techniques. For the purpose of this article, a position of 1 on the volume dial indicates the technique works poorly in hard cataracts, and a position of 10 on the volume dial means it works excellently.

HORIZONTAL PHACO CHOP

In a video at the 1993 ASCRS annual meeting, Nagahara described his technique for splitting the nucleus.[2] He used a modified lens hook, pulling it through the nucleus from the periphery toward the phaco tip and, thus, creating a horizontal chop. The only issue with this technique was that sometimes the chopped pieces became gridlocked in the capsular bag, and individual pieces had to be pulled into the anterior chamber for emulsification.

The horizontal chopping technique relies on compressive force to fracture the nucleus. This takes advantage of natural fracture planes in the lens created by the lamellar orientation of the lens fibers. I give this basic technique a volume rating of 6.

The stop and chop method of Koch and Katzen is a combination of Gimbel's trenching and Nagahara's horizontal chopping.[5] The technique begins with sculpting a deep

central trench. The surgeon then chops the heminuclei using a horizontal chop. The advantage of stop and chop is that it simplifies the difficult first chop. Here the phaco tip is positioned within the trough, against the side of the heminucleus that is to be cleaved. This gives it something to embed in and push against while the horizontal chop is performed. I give this technique a volume rating of 4.

Generally speaking, the advantages of chopping techniques are reduction of expended phaco power and the time spent in foot position 3; decreased stress on the zonules, as there is no need to push against the nucleus as in trenching; and minimal reliance on red reflex, as there is no need to gauge trench depth. Tips for a successful horizontal chop include:

- Once the capsulorrhexis is completed, good hydrodissection and hydrodelineation are performed. This outlines the endonucleus that is to be chopped.
- The chopper, always with a blunt tip, is slid under the capsulorrhexis, and the tip is turned vertical and slid into the junction between the endo- and epinucleus. The tip of the chopper should be embedded sufficiently at the equator; otherwise, no chop will happen.
- At the same time, in foot position 3, the phaco tip is embedded deeply into the hardest part of the nucleus, and the surgeon switches back to foot position 2 while maintaining occlusion. This preserves a firm hold.
- The chopper tip, which has been positioned in line with the phaco tip, is then pulled through the lens substance toward the tip. When the phaco and chopper tips reach

AT A GLANCE

- Generally speaking, vertical chopping works best for firm, brittle nuclei, and horizontal chopping is good for eyes in which zonules are weak due to high myopia or trauma.
- The advantages of the lens salute technique, especially in hard cataracts, include that there is no stress on the zonules and the posterior capsule and that it produces a through-and-through chop in any grade of cataract.
- Despite the advantages of LACS in routine cataracts, in hard cataracts, in which the nucleus may extend far beyond the pupillary space, the procedure may not be as effective. Further, once the cataract has been carved by the femtosecond laser into cubes, the phaco tip does not embed easily.

each other, lateral force is applied, separating the two nuclear pieces. Note that the chopper must be deep enough and the phaco tip must be well embedded. The chopper tip must also be in line with the phaco tip; otherwise, the nucleus will rotate, disengaging the phaco tip and dissipating the force applied to make the chop.

- Once the chop is made, the well-hydrodissected nucleus is rotated and a second chop is made. This converts the nucleus into four pieces. The individual pieces can then be pulled into the iris plane and emulsified.

VERTICAL PHACO CHOP

Hideharu Fukasaku, MD, described his technique of phaco snap and split at the 1995 ASCRS meeting and subsequently published it.[6] This direct-splitting technique was renamed phaco quick chop by David Dillman, MD, and subsequently described by Louis D. Nichamin, MD.[3] Steve A. Arshinoff, MD, FRCSC, described his phaco slice and separate method in 1999.[7] These are all examples of vertical chopping.

In these techniques, when the chop is commenced, the instruments move toward each other in the vertical plane, rather than the horizontal. The vertical chopper is used like a maul or blade from above to incise downward into the nucleus, just anterior to the centrally impaled phaco tip. This is different from the horizontal or Nagahara chop, in which the chopper is pulled from the periphery, in line with the phaco tip and toward it, to initiate the chop.

The most important step in vertical chop is to bury the phaco tip as deeply into the center of the endonucleus as possible. The sharp vertical chopper is pushed downward while the nucleus is simultaneously lifted the upward. This generates a shearing force. Imagine two tectonic plates, one rising and one falling in an earthquake, and the fracture line this creates between the two, and you will have a mental image of the technique. This is in contrast to the compressive force produced by horizontal chopping. After initiating a partial-thickness split, the embedded instrument tips are used to pry the two hemisections apart. Just as with horizontal chopping, this sideways separation of the instrument tips extends the fracture deeper and deeper, until the remainder of the nucleus is divided in half. Generally speaking, I give vertical chopping techniques a volume rating of 8.

David F. Chang, MD, provided a great description of the technique in his essay comparing horizontal and vertical chopping techniques.[8] "Slightly elevating the impaled phaco tip … prevents the descending chopper tip from pushing a firm nucleus against the posterior capsule," he noted. "For a brunescent lens, the phaco tip must lollipop into the nucleus as deeply as possible in order to be able to lift it upward. Like spearing a potato with a fork, the phaco tip must aim for the center of the nucleus. Too superficial a tip location will provide insufficient support and leverage. Much like a chisel would be used with a block of ice or granite, the vertical chopper tip can be used to cleave the nucleus into multiple pieces of variable size. The vertically chopped edges may appear sharp, like pieces of broken glass, because the crushing force that characterizes horizontal chop is not used. The sharp vertical chopper tip generally stays central to the capsulorrhexis. Thus, in contrast to horizontal chopping, it is always visualized and does not pass underneath the anterior capsule or behind the iris."

HORIZONTAL VS VERTICAL CHOPPING

- Vertical chopping requires a sharp-tipped chopper to initiate the split.
- In horizontal chopping, a blunt-tipped chopper must be used, as the tip may brush against the posterior capsule or fornix of the bag.
- Vertical chopping works best for firm, brittle nuclei.
- Horizontal chopping is good for eyes in which the zonules are weak due to high myopia or trauma, as the nucleus is pinned against the phaco tip by the chopper and the zonules are spared.

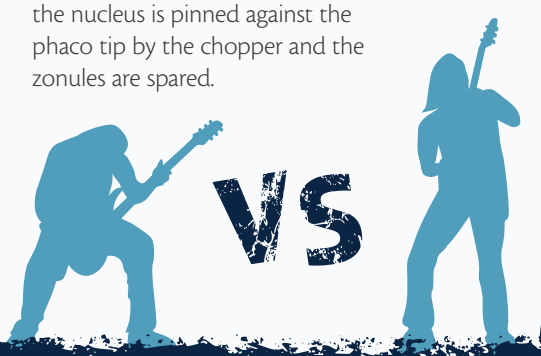

LENS SALUTE CHOP

At multiple meetings from 2002 onward, my father, Keiki Mehta, MD, and I, expounded and published a technique specially for the unique situations faced by Indian ophthalmologists, namely very hard grade 4 brunescent cataracts with weak zonules.[4]

At the time, many patients in India would not present for cataract surgery until their visual acuity had reached hand motion or light perception. These cataracts were brunescent and thick. The posterior plate was leathery and, with time, the zonular support system progressively weakened. A quick chop technique in a lens like

(Continued on page 55)

MY FAVORITE CHOP TECHNIQUE IN HARD CATARACTS

Arup Chakrabarti, MS
- Chakrabarti Eye Care Centre, Kochulloor, Trivandrum, Kerala, India
- arupeye@gmail.com
- Financial disclosure: None acknowledged

I prefer vertical chopping, preceded by some amount of preliminary sculpting. Using a vertical chop technique gives me more space in the anterior chamber, allowing me to perform chopping maneuvers further from the endothelium. Prior debulking of the nucleus also gives me access to a deeper nuclear zone that is easier to crack. Equally important, it gives me an idea of the strength of the zonules and firsthand information about the actual degree of nuclear sclerosis.

In my hands, I typically prefer a 30º standard phaco tip, but for very hard cataracts I prefer the Mega-Tip (Geuder). Both of these tips sculpt well and are also easy to occlude during chopping maneuvers.

Preliminary debulking can take the form of a crater or well (hemicrater; Figure 1), a short but deep trench, or a combination of the two depending on the type of nucleus. In ultrahard leathery cataracts, I like to create a long, deep trench (Figure 2). In other cases, a deep crater or well works just fine. Relatively high phaco power might be required for sculpting at this stage, in order to minimize inadvertent nuclear displacement and avoid zonular stress. Torsional phaco makes the sculpting process effortless. I also remove any fluffy cortical material near the rhexis margin to allow proper depth perception of the chopper tip and to avoid inadvertent trauma to the capsule.

I prefer vertical chopping to horizontal chopping because the former is more efficient and relatively faster in my hands. The distal tip length of most choppers is 1.25 to 1.5 mm, which should sufficiently reach the middle of a standard hard nucleus and create a reliable chop. A harder cataract, often about 5 mm thick, may call for the use of a chopper with a longer, sharp distal end of approximately 1.75 to 2 mm (Figure 3).

TWO VARIATIONS

Depending on the nature of the hard nucleus, I follow one of two variations of the chopping technique.

The brittle, hard nucleus. For a video demonstration of my technique in the brittle, hard nucleus, visit bit.ly/chakrabarti2_0517. After sculpting a deep well in the center of the nucleus, I use burst mode to impale the phaco tip at the deepest level of the nucleus. High vacuum is necessary at this stage for a good hold on the nucleus. The chopper is then buried deep into the substance of the nucleus, near the capsulorrhexis margin, and advanced toward the phaco tip.

I then proceed to crack or split the nucleus with lateral separation. I resist extreme degrees of lateral separation to minimize excessive stretching and distortion of the capsular bag and to avoid capsular-zonular complications. I then rotate the nucleus and repeat the same process until the nucleus is chopped into bite-size pieces. Keeping the tip bevel sideways (not advisable for Alcon Centurion Balanced tips) can provide extra endothelial protection and enhance visibility.

I realize the value of confining all these maneuvers entirely within the capsular bag and below the iris plane. Frequent replenishment of a dispersive OVD may be required for endothelial protection. Finally, care should be exercised by way of lowered parameter settings (vacuum, flow, and power) when removing the last piece of nucleus, as the posterior capsule is vulnerable.

The hard cataract with a posterior leathery nuclear plate. In these cataracts, I slightly modify my phaco maneuvers because the crack or chop line may not extend through and through in the first attempt and may inadvertently result in excessive lateral separation. This can jeopardize zonular integrity.

Here I sculpt a deep, long trench up to the rhexis margin before starting to chop the nucleus. Then I bury the phaco tip at the distal end of the groove before initiating the chopping maneuver. In this

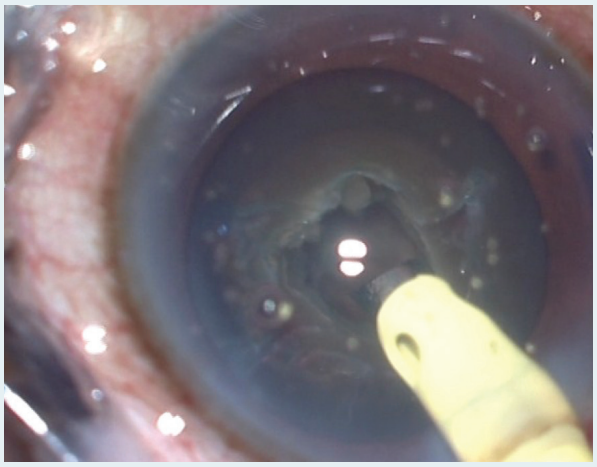

Figure 1. Preliminary debulking in the form of a hemicrater.

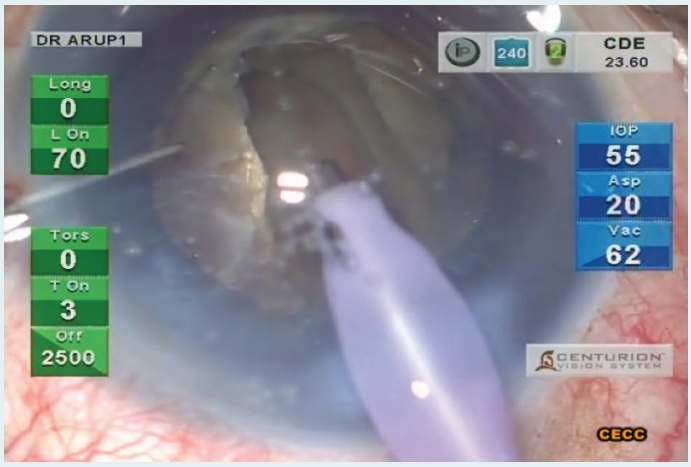

Figure 2. A long, deep trench created in an ultrahard leathery cataract.

WATCH IT NOW

Dr. Chakrabarti demonstrates his chop techniques in the brittle, hard nucleus and in the hard cataract with a posterior leathery nuclear plate.

situation, I prefer to use the long Chang chopper (Rhein Medical). Keeping the phaco tip stationary, I then bury the chopper deep into the nucleus and move it obliquely toward the phaco tip before attempting the lateral separation maneuvers. If the chop line has not extended completely through the entire thickness of the posterior nuclear plate, I rebury the phaco tip into the nucleus at a deeper plane, just anterior to where the crack has extended, and repeat the same chopping technique until a full-thickness crack is achieved. In another Eyetube video (bit.ly/chakrabarti0517), one can see my surgical technique in a hard cataract with a posterior leathery nuclear plate. In this video, I use a Sinskey hook in place of the long-tipped Chang chopper, as this device can be daunting for the beginner.

Early removal of the first piece of nucleus may help to create more space in the bag so that successive subchopping maneuvers are easier. In hypermature cataracts, I prefer not to emulsify the subsequent nucleus pieces until the rest of the nucleus has been completely chopped, since it would empty the capsular bag, exposing the posterior capsule. The smaller nuclear fragments are then consumed using lower vacuum, flow, and power settings. As the chopping progresses, I exchange the long Chang chopper for a Sinskey hook once the first few pieces have been consumed.

It is also important to take care of the intraocular milieu in terms of protecting the endothelium and avoiding trauma to the incision for best outcomes. ■



Figure 3. A long Chang chopper.

Yasser Rifay, MD
- Abtal, Agdal Rabat
- rifayyasser1@gmail.com
- Financial disclosure: None acknowledged

In the presence of a hard cataract, my favorite chop techniques are stop and chop and direct chop. When the capsulorrhexis is large (about 6 mm) and the pupil dilates well, I prefer to do direct chop using high vacuum (550 or 600 mm Hg) with high pressure. If the pupil dilates poorly or the rhexis is small, I use stop and chop. With both techniques, I use the chopper to cut the nucleus as a means to reduce the use of phaco energy (Figure 4). In eyes with hard cataracts and concomitant pseudoexfoliation syndrome, I first try direct chop to put less stress on the zonula. ■

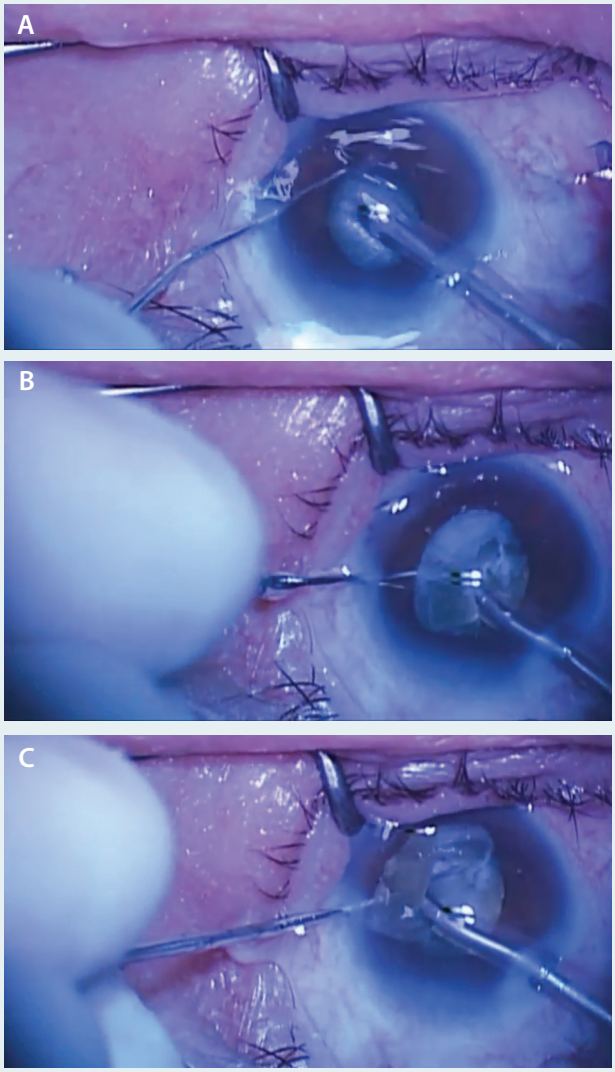

Figure 4. The chopper is used to cut the nucleus, reducing phaco energy in the eye (A–C).

STEP-BY-STEP GUIDE TO THE LENS SALUTE CHOP



Figure 1. The nucleus is prolapsed up in hydrodissection (A). The chopper is slid behind the nucleus (B). The chopper is in position for chopping (C). The chop is initiated (D). The chop is completed (E). The nucleus is rotated for another chop (F). Nuclear pieces are removed with torsional phaco (G).

(Continued from page 52)

this usually does not produce a through-and-through separation, as the posterior part is leathery and adherent. Horizontal chop is difficult as well, as there is no epinucleus and a negligible cortical cushion to allow insertion of the horizontal chopper.

The lens salute for extremely hard cataracts works like this:

- A capsulorrhexis of 5.5 to 6 mm is made, and the nucleus is gently hydrodissected and rotated.
- Once the nucleus moves freely between the 12- and 2-o'clock positions, more hydrodissection is performed while the superior pole of the lens is simultaneously pushed down. This tips the nucleus up toward the 5- or 6-o'clock position (Figure 1A).
- The phaco sleeve is retracted about 2.5 mm, and the phaco tip is then embedded into the central hard substance of the nucleus.
- A blunt chopper is slid around the tipped-up pole of the cataract (Figure 1B) and slid until it is positioned opposite the phaco tip (Figure 1C), separated by the nuclear substance.
- The phaco tip is pushed against the chopper, and the chopper is pulled toward the phaco tip (Figure 1D). Just before the two tips approximate, just as in any other chopping technique, a lateral separation is created (Figure 1E), producing a through-and-through chop. Even if the posterior plate is brown and leathery, it has already been split, with no force applied to the capsular bag.
- The nucleus can then be rotated and the process repeated to create more pieces (Figure 1F). The pieces so created are best emulsified in the iris plane or lower in the bag with torsional phaco (Figure 1G). We recommend emulsifying one piece at a time while the rest lie on the capsular bag for added capsular support.

ADVANTAGES OF THE LENS SALUTE

We have used the lens salute effectively in thousands of cases of hard and leathery cataracts over the years (Figure 2). The advantages, especially for very hard cataracts, include the following: There is no stress on the zonules, as the inferior pole of the nucleus is tipped up and the chopping forces are centrally located between the phaco

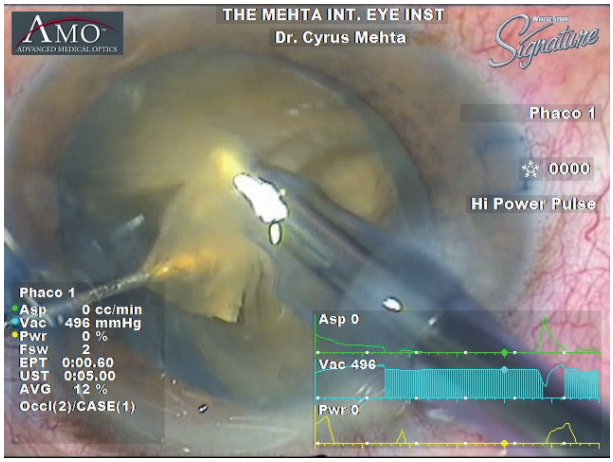

Figure 2. Successful lens salute chop in a hard brown nucleus. Note the chopper position behind the lens.

tip and chopper tip; it produces a through-and-through chop in any grade of cataract; and there is no stress on the posterior capsule, as the chopper is moved toward the phaco tip and not down toward the posterior capsule. I give this technique a volume rating of 10.

CHOPPING IN THE ERA OF LACS

Laser-assisted cataract surgery (LACS) has distinct benefits over standard phacoemulsification. The femtosecond capsulotomy is standardized in size, irrespective of intralenticular pressure. Laser fragmentation creates cleavage planes in the cataract (Figure 3). With a grade 2 or 3 cataract, nuclear hardness is reduced so that a simple split technique can be employed and pieces can be stuffed into the phaco tip with minimal energy expended.

With very hard grade 4 cataracts, however, there are several issues with LACS. The so-called safe margin created by the laser in these cataracts is usually kept to 800 µm or more. Also, the cataract is divided by laser energy only in the pupillary space, whereas the nucleus may extend far beyond that. Once the cataract has been carved by the femtosecond laser into cubes, the phaco tip does not embed easily. In its current form, I give LACS in hard cataracts a volume rating of 8.

At this time, my preferred technique for these cases remains the lens salute maneuver. With this technique, the inferior lens pole is prolapsed during hydrodisection, and the unfragmented posterior part of the lens is split by the chopper passing from posterior to anterior, avoiding the problems encountered when trying to use LACS in these eyes (Figure 4).

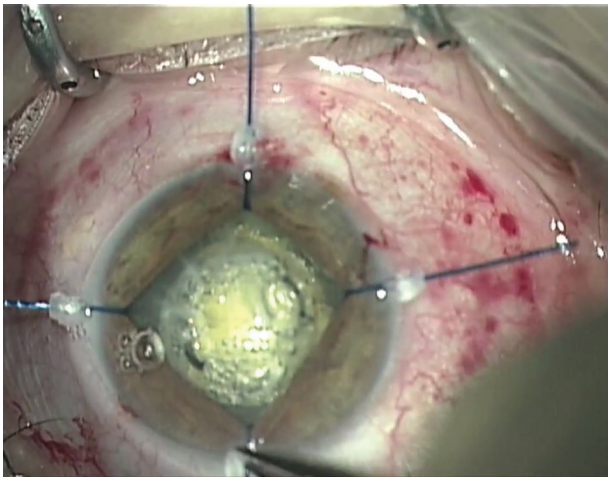

Figure 3. Femtosecond laser rhexis and fragmentation performed in an eye with a small pupil.

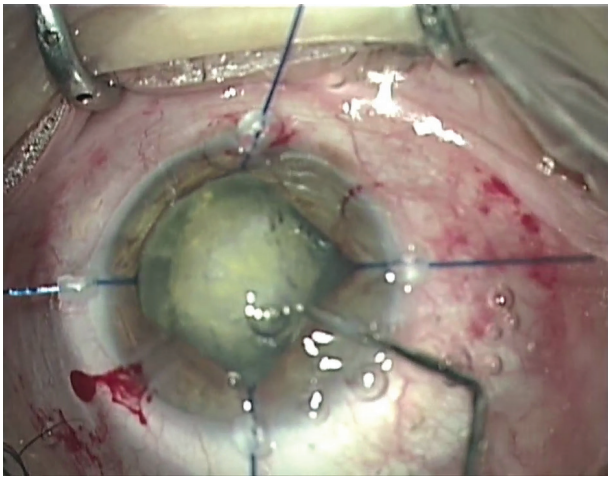

Figure 4. The nucleus is prolapsed by hydrodissection.

CONCLUSION

Chopping has evolved over the years, from the 1990s to the present, and even in the age of LACS it still remains relevant, especially for eyes with very hard cataracts. ■

1. Gimbel HV. Divide and conquer nucleofractis phacoemulsification: development and variations. *J Cataract Refract Surg*. 1991;17(3):281-291.
2. Nagahara K. Phaco chop. Video presented at: American Society of Cataract and Refractive Surgery Annual Meeting; May 8-12, 1993; Seattle.
3. Nichamin LD. Phaco quick-chop. *Cataract and Refractive Surgery Today*. 2002;4:42-43.
4. Mehta CK, Mehta KR. Lens salute microphaco. In: Perez Arteaga A, ed. *The Science & Art: Microincision Cataract Surgery (BIMICS & COMICS)*. Panama City, Panama: Jaypee Highlights; 2013:133-138.
5. Koch PS, Katzen LE. Stop and chop phacoemulsification. *J Cataract Refract Surg*. 1994;20(5):566-570.
6. Fukasaku H. The snap and split phacoemulsification technique. *Techniques in Ophthalmology*. 2004;2:135-136.
7. Arshinoff SA. Phaco slice and separate. *J Cataract Refract Surg*. 1999;25(4):474-478.
8. Chang DF. Phaco chop techniques—comparing horizontal vs vertical chop. *Highlights of Ophthalmology*. 2004;32(4):14-17.

Cyres Keiki Mehta, MS(Ophth), MCh(Ophth)
- Surgical Director and Chief, Dr. Cyres K. Mehta's International Eye Centre, Mumbai, India
- Director, CKM Eye Specialities, Mumbai, India
- cyresmehta@yahoo.com
- Financial disclosure: None acknowledged