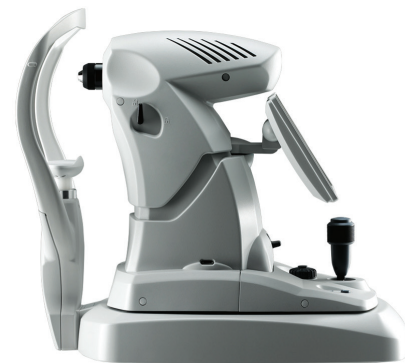

# Automated Gonioscopy Improves the Ability to Review the Angle Anatomy

With the ability to image the iridocorneal angle for up to 360°, automated gonioscopy adds even greater utility to a crucial examination technique.

BY LUIS ABEGÃO PINTO, MD, PhD



The first recorded inspection of the iridocorneal angle (ICA) was by the Greek ophthalmologist Alexios Trantas in the late nineteenth century.<sup>1</sup> While Maximilian Salzmänn is credited with helping to invent the forerunner of the gonioscope, it was Trantas who coined the term gonioscopy, which literally means “inspection of the angle” in Greek.<sup>1</sup>

Despite its established role in examining glaucoma patients, gonioscopy may be underutilized in routine clinical practice due to the fact that it is technically challenging and because of a misplaced perception that it is no longer required. As a consequence, ophthalmologists may be foregoing the gonioscopic examination under the presumption that it has low diagnostic yield.

However, gonioscopy remains an important part of the examination of glaucoma patients, especially in the context of microinvasive glaucoma surgery (MIGS) devices that require a thorough understanding of the ICA anatomy. Meanwhile, the recent availability of an automated gonioscopy platform, the GS-1 Gonioscope (NIDEK), simplifies the process of performing a gonioscopic examination, while also capturing a static image that greatly facilitates interpretation and adds to clinical usefulness.

## THE UNDERAPPRECIATED UTILITY OF GONIOSCOPY

The primary application of gonioscopy is to differentiate open-angle versus angle-closure glaucoma, which has implications for treatment as well as for prognosis for loss of visual ability. Although angle-closure glaucoma constitutes a fraction of the overall glaucoma population (15–20%), it carries a higher risk for blindness, accounting for the majority of the cases of bilateral amaurosis.<sup>2,3</sup> As well, many systemic medications, including several that are more frequently used among elderly individuals, are contraindicated in individuals with angle-closure glaucoma. Thus, while it may be tempting to skip the gonioscopic examination under the presumption that the patient likely has open-angle glaucoma, missing closed-angle etiology may have serious consequences for the patient’s long-term vision and health.

Indeed, patients with suspect glaucoma should undergo a gonioscopic examination at least once in the course of care—and it needs to be repeated if other risk factors are present

(ie, cataract, uveitic glaucoma, history of trauma, or prior surgery that involved manipulation of the angle).<sup>4</sup> However, studies indicate that fewer than 50% of glaucoma patients ever receive a gonioscopic examination.<sup>5,6</sup> Clearly, technology that improves the ability to perform gonioscopy would be welcomed to facilitate better adherence to evidence-based practices for glaucoma management.

## CHALLENGES AND OPPORTUNITIES WITH GONIOSCOPY

In much the same way that IOP and lens status are monitored over time to understand a patient’s risk for converting to glaucoma, the degree of angle closure can be tracked to help inform the clinical impression and subsequent treatment decisions. Yet, gaining an understanding of intervisit variability in the anatomy of the ICA can be challenging. Performing gonioscopy correctly is a learned skill, especially if depression is used, as one must be careful not to artificially open the angle. As well, it requires a compliant patient and the room lighting must be adjusted. Combined, these factors make it difficult to review the angle with a gonioscope, much less perform imaging so that the status of the ICA can be tracked over time.

Nevertheless, gaining an understanding of the ICA anatomy is important for patient selection and surgical planning. Many of the devices used in MIGS procedures involve manipulation of the angle. Being able to identify anatomic landmarks preoperatively helps ensure proper placement when in the OR—and to confirm placement after (*see image gallery on page 2*).

## THE GONIOSCOPE: A BETTER WAY TO PERFORM GONIOSCOPY

Using anterior chamber OCT to help understand ICA anatomy is less than optimal for two reasons: (1) anterior chamber OCT reconstructs a rendering of the angle, and so the accuracy is questionable; and (2) the images are black & white, whereas color images may be helpful in identifying certain pathologies, such as pigment or vessels broaching into the angle.

An automated gonioscopy device that processes an image of the ICA, the GS-1, has recently been introduced. The automated nature of the examination makes it less operator dependent; with the GS-1, the actual exam takes less than 1 minute to complete

for each eye, and the overall time to use the device, including logging the patient's information, is about 5 minutes.

The biggest advantage of the GS-1, though, is that it captures a high-resolution static image for up to 360° of the ICA (Figure). Getting comparable images using a standard gonioscope is, for all intents, impossible. For one, manual gonioscopy is technically challenging and requires a cooperative patient, and so repeating it while imaging in multiple quadrants to construct a montage merely compounds the complexity. In addition, the GS-1 offers far superior magnification over manual gonioscopy, which means the images are of higher quality. Importantly, image quality is much less dependent of the operator.

## CONCLUSIONS

The availability of an automated gonioscopy device has allowed us to expand the indications for the test. Our colleagues in the retina service have started using the GS-1 to look for neovascularization in the angle in patients with diabetes, which would indicate the presence of an ischemic process that might impact treatment decisions. In our uveitis clinic, the GS-1 has shown promise for identifying synechia that is indicative of flare, in which case anti-inflammatory therapy can be directed. Meanwhile, for patients with glaucoma, the GS-1 offers to change how and why the ICA anatomy is reviewed. For patients with glaucoma and cataract, GS-1 is an easy-to-perform test that will definitively demonstrate whether the lens removal will be of benefit.

Fundamentally, the GS-1 addresses concerns that gonioscopy is technically challenging, which gives the examination greater utility. It is true that a picture is worth a thousand words—and in

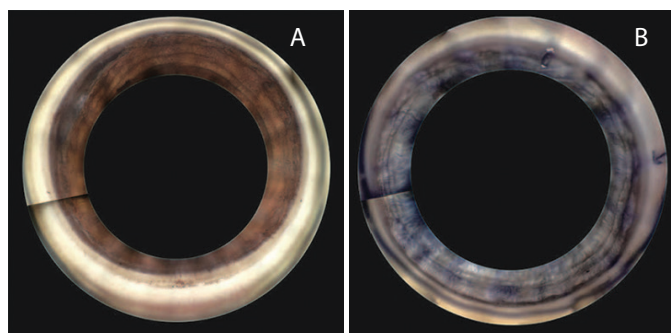


Figure. Example GS-1 images showing 360° of the ICA anatomy: angle recession after angle closure (A) and drainage system implant + IOL (B).

this context, having a color image of the ICA anatomy is extremely beneficial. The continued use of color retinography despite the widespread adoption of OCT provides a useful analogy in this regard. First, no report from an OCT machine, no matter how thorough, can ever replace a real picture; in the same manner, images from the GS-1 permit the ability to calmly review the results offline in order to plan, discuss, and diagnose. Second, the fact that GS-1 produces a color image is important to appreciate. Grey image reconstructions may miss important pathology. Third, while OCT adds to clinical decision making, gaining another perspective with retinography adds additional potentially important information. In a similar fashion, there may still be a role for traditional gonioscopy to inspect the angle in the clinic, but having a static image provides a more thorough and extensive review of the ICA anatomy. ■

Courtesy of Prof. C. Pavessa, MD, Clinica Oculistica D.M.O.G.M.U., University of Genova - Ospedale Policlinico S. Martino, Italy

The GS-1 (NIDEK) offers great utility for evaluating the success of MIGS procedures, even those that involve bypass of traditional outflow mechanisms. The image gallery below provides some examples.

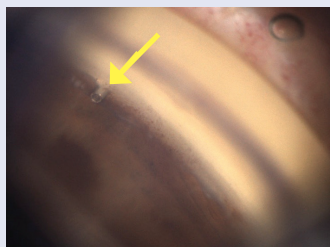


Figure 1. Image of an iStent (Glaukos) confirming proper placement in the angle.

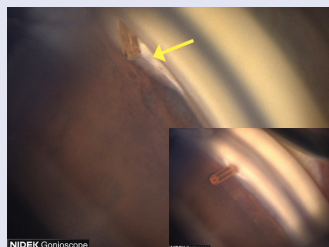


Figure 2. An ab interno view demonstrates that a Xen Gel Stent (Allergan) has created a cleft at the iris/ciliary body and has disinserted from the sclera. By contrast, a properly positioned and open Xen device is demonstrated in the inset image.




Figure 3. Gonio view of an eye postiridotomy. A heterogenous patch of pigment (yellow arrows) from the laser can be detected in the inferior angle. In this case, the angle is open and thus the procedure was successful.

### Luis Abegão Pinto, MD, PhD

- Professor of Medicine at Lisbon University, Department of Ophthalmology, Hospital Santa Maria
- abegaopinto@gmail.com
- Financial disclosure: Consultant (NIDEK)

1. Alward WL. A history of gonioscopy. *Optom Vis Sci.* 2011;88(1):29-35.
2. Tham YC, Li X, Wong TY, et al. Global prevalence of glaucoma and projections of glaucoma burden through 2040: a systematic review and meta-analysis. *Ophthalmology.* 2014;121(11):2081-2990.
3. Jonas JB, Aung T, Bourne RR, et al. Glaucoma. *Lancet.* 2017;390(10108):2183-2193.
4. Prum BE Jr, Herndon LW Jr, Moroi SE, et al. Primary angle closure preferred practice pattern guidelines. *Ophthalmology.* 2016;123(1):P1-P40.
5. Coleman AL1 Yu F, Evans SJ. Use of gonioscopy in medicare beneficiaries before glaucoma surgery. *J Glaucoma.* 2006;15(6):486-493.
6. Varma DK, Simpson SM, Rai AS, Ahmed IK. Undetected angle closure in patients with a diagnosis of open-angle glaucoma. *Can J Ophthalmol.* 2017;52(4):373-378.