

NEURAL ADAPTATION CONSIDERATIONS AND NEGATIVE DYSPHOTOPSIA

SPONSORED BY



Kinetic perimetry readings from the Octopus 900 help to reveal the true extent of the scotoma.

BY NICOLE R. FRAM, MD

As sometimes overlooked patient complaint after uncomplicated cataract surgery is dysphotopsia.¹ Pseudophakic dysphotopsia was first described by Davison in the 1990s with acrylic IOLs.² Dysphotopsias are subjective or undesired optical images that patients experience after surgery, and there are two types—positive and negative. The former is the more common, and it leaves patients complaining that they see streaks of light or arcs, starbursts, flashes or flickers, shimmering and haze. Negative dysphotopsia (ND) is more rare,^{3,4} but some studies suggest that 30,000 to 100,000 new patients per year present in the United States alone.³⁻⁶ Patients commonly describe their symptoms as an arc-shaped shadow or dark crescent usually in the temporal field of vision.

Believe it or not, ND is associated only with anatomically perfect surgery (Figure 1). The condition is stimulated by a temporal peripheral light source, and it may be

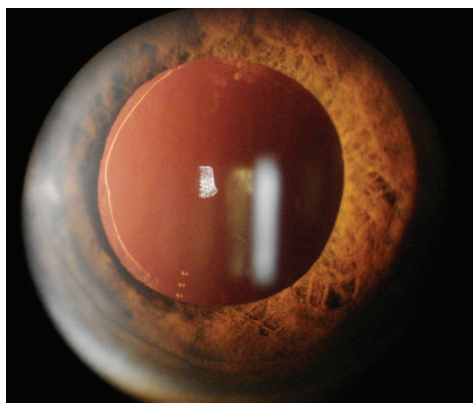


Figure 1. Slit Lamp image of an eye with ND after anatomically perfect cataract surgery.

blocked by the hand or thick eyeglass frames. The symptoms of ND are present from postoperative day 1, but they can get better with time. ND can be either transient or persistent, but symptoms tend to get better when the patient's pupil is dilated and worse when it is constricted.

EASE PATIENTS' FEARS

According to Olson et al,¹ 49% of cataract surgery patients have some form of negative or positive dysphotopsia. There are no objective clinical tests to confirm the presence of ND, and therefore all that clinicians have to go on is patient-reported observations.

The first thing that I do for patients who experience ND is to provide some reassurance. I typically say, "I understand you're having a problem, and it usually improves with time." In one study, the incidence of ND on the first postoperative day was 15.2%, decreasing to 3.2% after 1 year and then 2.4% after 2 and 3 years.⁴

After retinal pathology and any neurological conditions are ruled out, the next step is to dilate the patient and ask, "Are your symptoms better?" Variably he or she will answer affirmatively.

Patients find it reassuring when you explain to them that ND is associated only with anatomically perfect surgery.

CAUSE AND TREATMENTS

The working ray-tracing theory of ND is a temporal dark shadow caused by a narrow band of nonilluminated nasal retina that is bounded posteriorly by intended light refracted by the optic and bounded anteriorly by light that misses the optic. In short, there is an illumination gap, with some rays

that are being focused by the lens and some that miss the lens and create a dark arc.

It is hypothesized that illuminating the dark band of nasal retina or shifting the optic anteriorly will move the dark shadow beyond the functional retina and, as a result, eliminate the patient's symptoms. Today, we believe that any IOL that is implanted in the capsular bag can cause ND, and we manage our surgical technique to address that problem by putting the optic on top of the capsule in a reverse optic capture position, by using a piggyback IOL, or by putting a new lens in the ciliary sulcus or nasal capsulectomy.

According to our study,⁷ ND can be associated with acrylic or silicone IOLs with either square- or round-edge designs. ND was seen in 72% of eyes with a hydrophobic acrylic IOL, 24% with a silicone IOL, and 4% with a hydrophilic acrylic IOL (Figure 2). So we know that the cause of ND is multifactorial.

FINDING NEW EVIDENCE

Visual fields are classically normal in eyes with ND. However, Makhotkina et al⁸ used Goldmann kinetic perimetry testing to

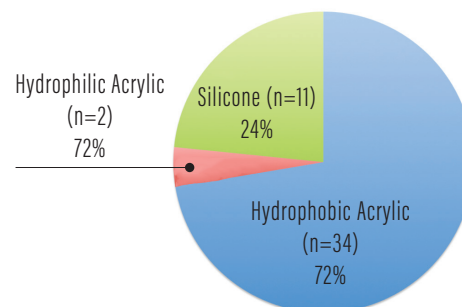


Figure 2. IOL materials associated with ND.

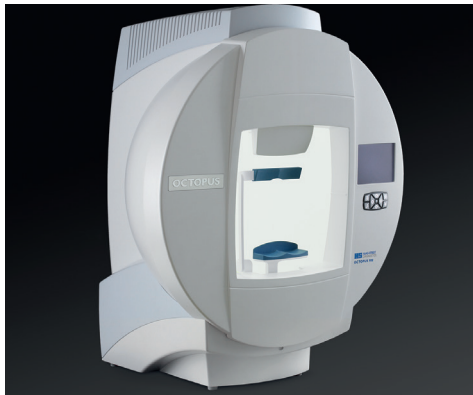

Figure 3. The Octopus 900 (Haag-Streit).

determine that there are subtle differences between eyes that do and do not experience ND, including significantly shorter axial length and higher IOL power.

With this information, Samuel Masket, MD, and colleagues investigated the extent and neural adaptive factors involved with ND. In this study, the ND scotomas from patients' eyes were mapped with the Octopus 900 (Haag-Streit, Figure 3). This technology provides full field static and semi-automated kinetic perimetry. The Octopus 900's semi-automated perimetry allowed us to easily map the scotomas and electronically file the data automatically. In this study we were also able to identify that the scotomas in ND differ from any other visual field defects, including those associated with retinal detachment and glaucoma.

Patients were initially measured with the Octopus 900 and asked to indicate when they saw the target image change, when they saw it come and go, and when it was gone completely. The contralateral, uninvolved, eye was patched with a translucent occlusion during measurement. Interestingly, patients reported decreased ND symptoms subjectively and objectively. When a totally opaque patch was placed over the contralateral eye, the effective improvement was more prominent. During complete occlusion with a pirate patch, 20 of the 25 eyes experienced a reduction in ND symptoms, with a mean subjective improvement in symptoms of 65% (range, 50–95%).

Based on these findings, neural adaptive therapy with an opaque contact lens was tested. The rationale was to attempt to block temporal light that is known to stimulate ND. The opaque contact lens provided a

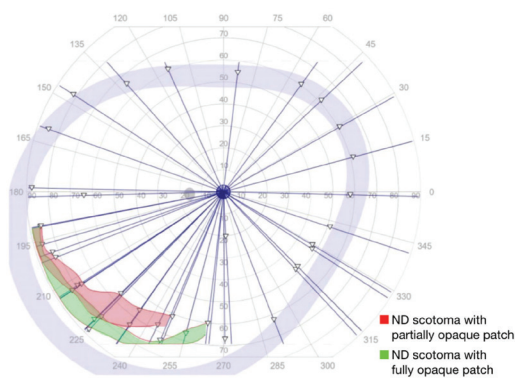


Figure 4. A perimetry map of a patient with ND. The ND scotoma is measurable with a smaller and more peripheral scotoma with fully opaque patching versus partially opaque patching.

temporary effect, improving the symptoms in eight of 10 patients. However, the tolerance to the opaque contact lens was problematic. Figure 4 shows a map of a binocular visual field with a partially occlusive contact lens on the uninvolved contralateral eye. When a pirate patch was applied, the scotoma then got smaller and more peripheral.

Figure 5 shows Octopus 900 perimetry maps of the scotoma in a patient with ND in the left eye only. The patient's binocular unoccluded visual field with ND defect is depicted in Figure 5A, and Figure 5B shows a map of the same patient's binocular visual field with a partially occlusive contact lens on the right eye. When a pirate patch was applied, the scotoma then got smaller and more peripheral.

TAKE-HOME MESSAGE

So what is the take-home message from our review of the literature? We know that negative or positive dysphotopsia occurs transiently in almost 15% of patients on postoperative day 1.³ We know that there are surgical interventions such as reverse optic capture, sulcus placement of an IOL, or piggyback IOL implantation that may decrease the symptoms. However, what if we could use contralateral eye patching as a neural adaptive therapy that may not require surgery to fix?

As an alternative to surgical intervention, we are investigating the potential of contralateral occlusion therapy to promote neural adaptation to ND.

By measuring the scotomas in eyes with ND using semi-automated kinetic

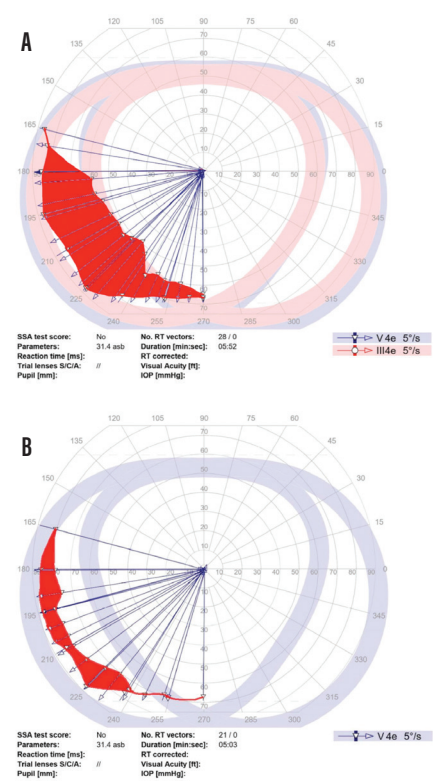


Figure 5. Semi-automated kinetic testing with the Octopus 900, depicting the normal binocular visual field in a patient with ND in the left eye only (A) and the binocular visual field with a partially occlusive contact lens applied to the right eye (B).

perimetry readings from the Octopus 900, we can reveal the true extent of the scotoma and possibly do contralateral inclusion therapy to help patients through the neural adaptation process. ■

- Olson RJ. Consultation section: cataract surgical problem. *J Cataract Refract Surg.* 2005;31:653-654.
- Davidson JA. Positive and negative dysphotopsia in patients with acrylic intraocular lenses. *J Cataract Refract Surg.* 2000;26(9):1346-1355.
- Masket S, Geraghty E, Crandall AS, et al. Undesired light images associated with ovoid intraocular lenses. *J Cataract Refract Surg.* 1993;19:690-694.
- Osher RH. Negative dysphotopsia: long-term study and possible explanation for transient symptoms. *J Cataract Refract Surg.* 2008;34(10):1699-1707.
- Tester R, Pace NL, Samore M, Olson RJ. Dysphotopsia in phakic and pseudophakic patients: incidence and relation to intraocular lens type. *J Cataract Refract Surg.* 2000;26(6):810-816.
- Boumas P, Drazinos S, Kanellas D, Arvanitis M, Vaikoussis E. Dysphotopsia after cataract surgery: comparison of four different intraocular lenses. *Ophthalmologica.* 2007;221(6):378-383.
- Masket S, Fram NR, Cho A, Park I, Pham D. Surgical management of negative dysphotopsia. *J Cataract Refract Surg.* 2018;44:6-18.
- Makhotkina NY, Berendschot TJM, Nuijts RMM. Objective evaluation of negative dysphotopsia with Glodmann kinetic perimetry. *J Cataract Refract Surg.* 2016;42(11):1626-1633.

NICOLE R. FRAM, MD

- Private practice, Advanced Vision Care, Los Angeles
- Clinical Instructor of Ophthalmology, Jules Stein Eye Institute, University of California, Los Angeles
- nicfram@yahoo.com
- Financial disclosure: Speaker (Haag-Streit)