

# ADVANTAGES OF COAXIAL MICRO-INCISION CATARACT SURGERY WITH EASYTIP CO-MICS

BY DANIEL MOJON, MD, FMH, FEBO, EMHSA, PROF. UNIBE



Performing coaxial micro-incision cataract surgery (CO-MICS) through incisions as small as 1.6 mm has gained momentum as intraocular lenses for such small incisions have become broadly available. CO-MICS instruments have evolved as well, allowing surgeons to develop new techniques and optimize outcomes.

I chose to begin doing CO-MICS many years ago, attracted by the potential to reduce induced astigmatism, which is so important for refractive surgery. At first, I was afraid it would be too difficult to work in a 1.6-mm incision, but after 3 months performing CO-MICS, I had no complications and could perform CO-MICS just as quickly as standard surgery. In addition, I had more space in the

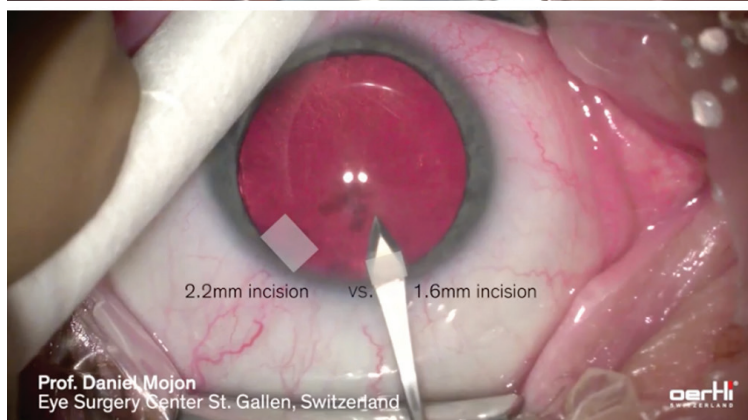
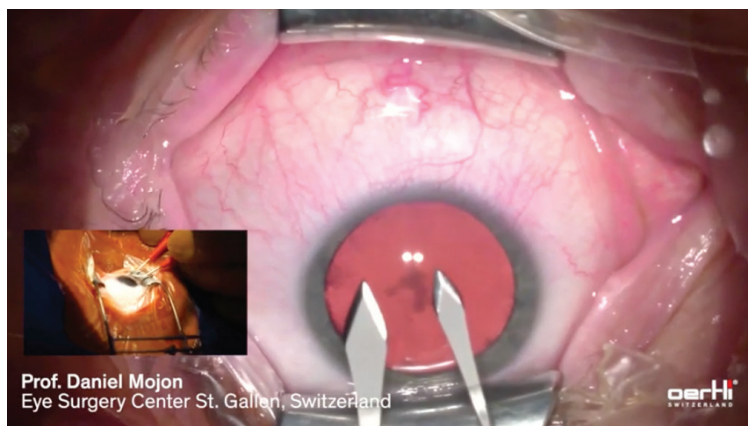


Figure. Incision size versus wound size: The incisions for 2.2-mm and 1.6-mm easyTip CO-MICS differ only 0.6 mm, but the wound for the 2.2 mm is significantly larger because the tunnel is nearly a square.

**"When I'd been doing CO-MICS for 6 months, I realized that I felt much safer during surgery. It was a great experience to see that making smaller incisions improved the stability of the anterior chamber and made cataract surgery even safer."**

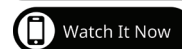anterior chamber, especially in a shallow chamber like we see in a hyperopic patient.

When I'd been doing CO-MICS for 6 months, I realized that I felt much safer during surgery. It was a great experience to see that making smaller incisions improved the stability of the anterior chamber and made cataract surgery even safer.

## THE IMPORTANCE OF INCISION SIZE

CO-MICS instrumentation has evolved continuously since the first 1.6-mm procedure. I use the easyTip CO-MICS (Oertli Instrumente AG, Switzerland), with a specific design that makes 1.6-mm surgery just as comfortable as working through a standard 2.2- or 2.4-mm incision. The tip has an extra-large opening for strong holdability of the lens fragments, permitting efficient removal as well as application for ultrasound. The slim shaft helps to prevent any surge upon occlusion break. The large infusion area around the tip ensures that there is enough irrigation into the eye, keeping the anterior chamber stable, even when working with high settings on the machine.

It's very easy to make a 1.6-mm incision for easyTip CO-MICS. The incision size is 0.6 or 0.8 mm smaller than standard surgery—a difference colleagues sometimes tell me doesn't matter—but that doesn't tell the story of the difference in wound size. With the 1.6-mm easyTip CO-MICS, because the tunnel is nearly a



**"I'm performing a lot of refractive cataract surgery and implanting a significant percentage of toric and multifocal lenses, and I'm observing better results because of the significantly smaller incisions, which no longer affect the surgically induced astigmatism."**

square, the wound will be less than half the size of that created by a 2.4-mm incision (Figure). Wound healing is much faster, and there's no need to close the eye with a patch postoperatively. I'm performing a lot of refractive cataract surgery and implanting a significant percentage of toric and multifocal lenses, and I'm observing better results because of the significantly smaller incisions, which no longer affect the surgically induced astigmatism. To date, I've performed more than 5,000 CO-MICS procedures and developed a technique that allows me to maintain a stable anterior chamber and better control surgical outcomes.

#### **THE VIP TECHNIQUE**

CO-MICS allowed me to develop a new technique 2 years ago called viscoelastic irrigation pressurized surgery (VIP). I like to have the eye pressurized during surgery to avoid a postoperative posterior vitreous detachment or a hypotony that could potentially lead to vision-threatening bleeding, so I developed a way to do that very easily without an anterior chamber maintainer.

To begin, I make the 1.6-mm incision for easyTip CO-MICS 53°. I make side incisions for irrigation, aspiration, and manipulation of the nucleus while performing surgery and capsulorhexis. Next, I do hydrodissection and prepare the nucleus using a chopper. Fluidics also play a big role in the eye. I work with the OS 4 platform

(Oertli Instrumente AG, Switzerland) which provides fluidics based on physics. Due to this elaborate fluidics system, the whole irrigation process is performed through the phaco tip without the need for additional instruments.

As I remove the nucleus, the anterior chamber remains very stable. There are no problems with a small incision, even with a very hard nucleus. The easyTip CO-MICS is available with a 30° or 53° tip; I prefer the 53° tip, which gives me more surface area that provides even stronger holdability.

The VIP begins at this point, as I fill the capsular bag and the anterior chamber with viscoelastic before I retrieve the phaco tip. This stabilization nearly completely avoids anterior movement of the vitreous body, leading to less postoperative posterior vitreous detachment. This is important because vitreous detachment can cause floaters, macular edema, or even retinal detachment, especially in very myopic eyes or those that already have maculopathy. Next, I go on the other side to switch irrigation and aspiration. Again, I go in with the viscoelastic and go out with the irrigation cannula after I have stabilized the anterior chamber.

At this point, a hydroimplantation of the new lens is performed. To close all openings, I partially retrieve the irrigation cannula until its openings are within the tunnel. This allows me to hydrate the side-port paracentesis while simultaneously hydrating the clear cornea incision, followed by the

second side-port paracentesis, using a Sauter Hydrodissection Cannula attached to a syringe filled with balanced salt solution.

At this time, the patient has the smallest possible wound, a centered lens, and no viscoelastic left because of the hydroimplantation technique, and he or she never experienced any anterior movement of the lens-iris diaphragm during the surgical procedure.

#### **CONSIDER THE ADVANTAGES**

CO-MICS surgery minimizes surgically induced astigmatism because the incision is small and the cornea is always held in the physiologic curvature. Because we don't need to patch the eye with such small incisions, peripheral vision remains 180° and depth perception is preserved, so the patient can function more safely. There is no concern about an increase in temperature under the patch, which may encourage bacterial growth.

The VIP technique adds to the list of advantages with reduced postoperative posterior vitreous detachment, better immediate postoperative visual acuity, and a minimized risk of expulsive bleeding. There is also no sudden drop in intraocular pressure and, thus, we observe less Descemet folds. VIP avoids the use of an anterior chamber maintainer, an additional opening, and another bottle of liquid to pressurize the eye during the whole procedure. Overall, CO-MICS surgery has meaningful advantages for patients' clinical outcomes—all in a safe approach that is just as easy to perform as surgery with standard incision sizes. ■

---

#### **DANIEL MOJON, MD, FMH, FEBO, EMHSA, PROF. UNIBE**

- Central Station Eye Centre, St. Gallen, and Airport Medical Center Eye Clinic Zürich Airport, Switzerland
- President of the Association of Eastern Switzerland Ophthalmologists
- Trustee and Program Committee Chair of the Swiss Academy of Ophthalmology
- daniel.mojon@gmail.com
- Financial disclosure: None