Scleral Lenses for Complex Corneas

BY ELISE KRAMER, OD, FAAO, FSLS, FBCLA

Modern designs can provide unique health benefits and increase patient comfort.

The benefits of scleral contact lenses have been well established since descriptions of glass-blown shells appeared in the literature in the late 1800s.[1] Scleral lenses are fit for therapeutic use, the improvement of vision, and the correction of refractive error.

The first successful fitting of scleral lenses made of PMMA was reported in 1939.[2] Complications related to corneal hypoxia, including neovascularization and edema, however, limited the use of scleral lenses until the latter part of the 20th century.[3,4] The development of materials with high oxygen permeability (Dk) renewed interest in scleral lenses. In 1983, Ezekiel first described the successful use of gas permeable scleral lenses, which significantly reduced complications from corneal hypoxia.[5] Other pioneers reported the successful use of gas permeable scleral lenses for postoperative refractive correction and keratoconus.[4,6-11] Since the 1990s, the indications for the use of scleral lenses have been improved and refined. This article describes modern uses of this therapeutic modality.

KNOW THE BASICS

How the lenses work. Scleral lenses provide a smooth anterior ocular surface and neutralize the irregularity of the ocular surface. They have a larger diameter than other contact lenses.

Scleral lenses do not rest on the cornea; they are supported by the conjunctival tissue overlying the sclera. In other words, a large diameter delivers the desired vision benefits without requiring the lens to sit on the cornea itself (Figures 1–3). Lenses that sit on the cornea are typically less comfortable than scleral lenses and are therefore problematic for patients with corneal irritation or irregularly shaped corneas. For eyes with highly irregular corneas, better lens centration and stability may be attained with scleral lenses than corneal lenses. A lack of contact between the scleral lens and the

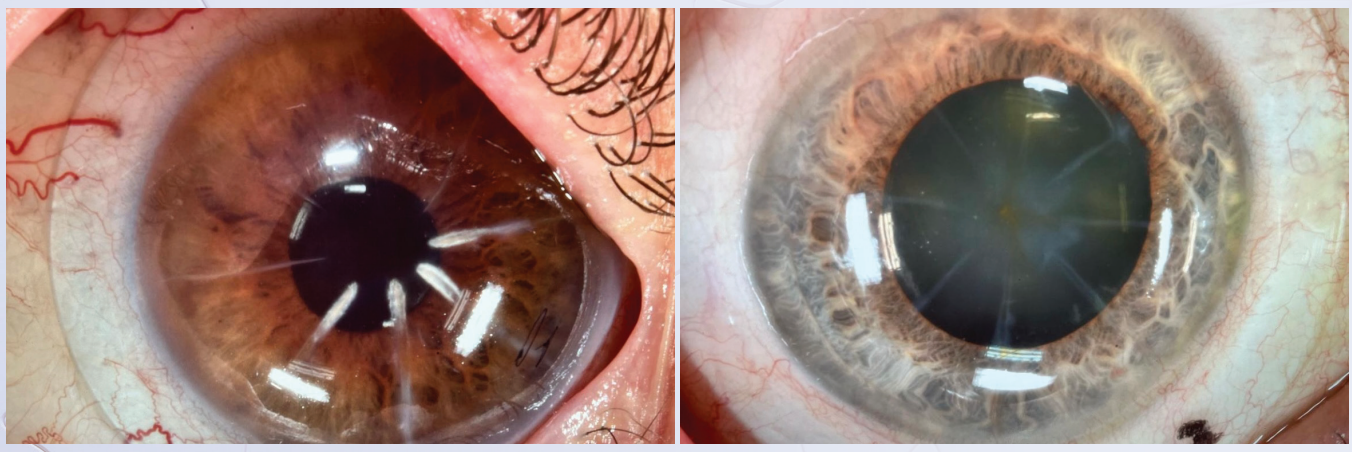

All figures courtesy of Edward Boshnick, MD

Figure 1. Scleral lenses over post-radial keratotomy eyes.

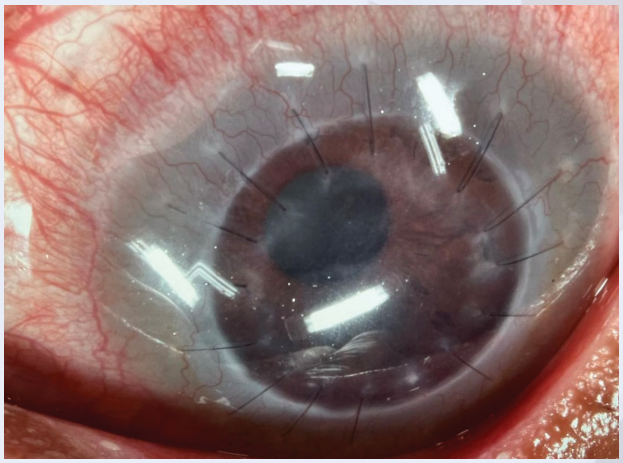

Figure 2. Scleral lens over a post-keratoplasty eye with interrupted sutures and a displaced pupil.

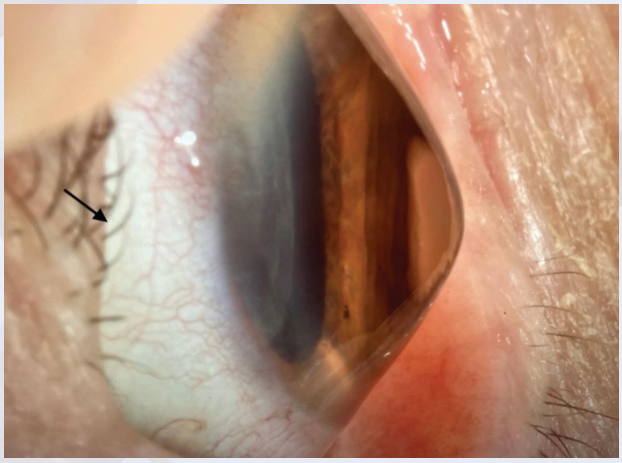

Figure 3. Side view of a scleral lens over an eye with advanced keratoconus.

highly innervated cornea also generally decreases patient awareness of the lens on their eye, increases their comfort, and reduces their lens adaptation time.

Indications. The main indication for scleral lenses is corneal irregularity.[4,12] They can also help in managing ocular surface disease[12-14] and are a good therapeutic option for lid or orbital disorders and refractive correction in otherwise normal, healthy eyes. The clinical indications for scleral lens wear are summarized in the Table.

Scleral lenses can enhance visual quality and comfort[15,16] and thus quality of life.[17,18] In a retrospective review, 18.7% of patients who underwent corneal transplantation between 1999 and 2003 achieved 20/20 or 20/25 VA with scleral lenses.[15] According to DeLoss et al, even eyes with advanced keratoconus may benefit from scleral lenses, and visual outcomes were better and visual recovery was more rapid for patients with stage 4 ectasia who received scleral lenses versus keratoplasty.[17] Koppen

TABLE. INDICATIONS FOR SCLERAL LENS USE

Irregular Cornea	
Primary Corneal Ectasias	Keratoconus
	Pellucid Marginal Degeneration
	Keratoglobus
After Keratoplasty	Penetrating Keratoplasty
	Anterior Lamellar Keratoplasty
After Refractive Surgery	LASIK
	LASEK
	PRK
	Radial Keratotomy
After Pterygium Surgery	
Corneal Scarring	Herpes Simplex Keratitis
	Other Keratitis
	Trauma
Ocular Surface Disease	
Keratitis Sicca	Sjögren Syndrome
	Neurotrophic Keratopathy
	After Irradiation
	Acne Rosacea
	Chemical Burns
	Undifferentiated Dry Eye
Cicatrizing Conjunctivitis	Stevens-Johnson Syndrome
	Ocular Cicatricial Pemphigoid
Corneal Dystrophies and Degenerations	Salzmann Nodular Degeneration
	Terrien Marginal Degeneration
	Recurrent Corneal Erosion
	Lattice Corneal Dystrophy
	Granular Dystrophy
Exposure Keratopathy	Exophthalmos (Graves Disease)
	Nerve Palsies
	After Eyelid Surgery
	Acoustic Neuroma Resection
Graft-Versus-Host Disease	
Atopic Keratoconjunctivitis	
Congenital Corneal Hypoesthesia	

(Table continued on pg 34)

TABLE. INDICATIONS FOR SCLERAL LENS USE (CONTINUED)
Symblepharon
Limbal Stem Cell Deficiency
Vernal Keratopathy
Persistent Epithelial Defects
Lid/Orbit Disorders
After Lid Surgery
Facial Trauma
Dermatochalasis
Crouzon Syndrome
Goldenhar Syndrome
Bulbous Atrophy
Ptosis
Trichiasis
Ectropion
Entropion
Eyelid Coloboma
Refractive Correction and Normal Cornea
Myopia
Hyperopia
Astigmatism
Anisometropia
Presbyopia
Pseudophakia
Aphakia
Cornea Plana
Strabismus
Low Vision
Nystagmus
Sports
Work Environments
Drug Delivery

et al recently demonstrated the successful long-term treatment of severe keratoconus with scleral lenses in patients who otherwise would have needed corneal transplantation.[19]

Patients with poor vision due to an irregular corneal surface and irregular astigmatism can present a treatment challenge. Corneal gas permeable lenses may provide these individuals with excellent visual acuity. If lens centration, stability, or adaptation is insufficient, however, scleral lenses may be a better option.

CONCLUSION

Modern scleral lenses can eliminate blurred and distorted vision, promote healing of the ocular surface, and protect the cornea from the surrounding environment and the eyelids. Careful documentation and baseline measurements, photography, and other ocular assessments can help improve success with scleral lenses. Frequent follow-up visits are recommended. Lens designs may require fenestration, notches, localized vault, or impression techniques. ■

1. Müller F, Müller A. *Das künstliche Auge*. Bergmann; 1910.
2. Thier PFX. Contactglazen, vervaardigd van harsproducten. Ned Tijdschr Geneeskd. 1939;83:4161.
3. Dallos J. Sattler's veil. *Br J Opthalmol*. 1946;30:607-613.
4. Tan DT, Pullum KW, Buckley RJ. Medical applications of scleral contact lenses: 1. A retrospective analysis of 343 cases. *Cornea*. 1995;14(2):121-129.
5. Ezekiel D. Gas permeable haptic lenses. *J Br Contact Lens Assoc*. 1983;6:158-161.
6. Visser R. Een nieuwe toekomst voor hoog-zuurstofdoorlatende scleralenzen bij verschillende pathologie. *Visus*. 1990;3:11-16.
7. Schein OD, Rosenthal P, Ducharme C. A gas-permeable scleral contact lens for visual rehabilitation. *Am J Ophthalmol*. 1990;109(3):318-322.
8. Rosenthal P, Cotter JM, Ducharme C. Gas permeable scleral contact lenses for irregular corneas. *Contact Lens Association of Ophthalmologists*. 1990;5:3.
9. Barr J, Rosenthal P. Scleral/haptic RGPs: the potential of these contact lenses for difficult cases is great. *Contact Lens Spectrum*. 1991;12:21-23.
10. Kok JH, Visser R. Treatment of ocular surface disorders and dry eyes with high gas-permeable scleral lenses. *Cornea*. 1992;11(6):518-522.
11. Rosenthal P, Cotter JM, Baum J. Treatment of persistent corneal epithelial defect with extended wear of a fluid-ventilated gas-permeable scleral contact lens. *Am J Ophthalmol*. 2000;130(1):33-41.
12. Rosenthal P, Croteau A. Fluid-ventilated, gas-permeable scleral contact lens is an effective option for managing severe ocular surface disease and many corneal disorders that would otherwise require penetrating keratoplasty. *Eye Contact Lens*. 2005;31(3):130-134.
13. Harthan J, Nau CB, Barr J, et al. Scleral lens prescription and management practices: The SCOPE Study. *Eye Contact Lens*. 2018;44(suppl 1):S228-S232.
14. Nau CB, Harthan J, Shorter E, et al. Demographic characteristics and prescribing patterns of scleral lens fitters: The SCOPE Study. *Eye Contact Lens*. 2018;44(suppl 1):S265-S272.
15. Pullum KW, Whiting MA, Buckley RJ. Scleral contact lenses. the expanding role. *Cornea*. 2005;24(3):269-277.
16. Montalt JC, Porcar E, España-Gregori E, Peris-Martínez C. Visual quality with corneo-scleral contact lenses for keratoconus management. *Cont Lens Anterior Eye*. 2018;41(4):351-356.
17. DeLoss KS, Fatteh NH, Hood CT. Prosthetic replacement of the ocular surface ecosystem (PROSE) scleral device compared to keratoplasty for the treatment of corneal ectasia. *Am J Ophthalmol*. 2014;158(5):974-982.
18. Picot C, Gauthier AS, Campolmi N, Delbosc B. Quality of life in patients wearing scleral lenses. Article in French. *J Fr Ophtalmol*. 2015;38(7):615-619.
19. Koppen C, Kreps EO, Anthonissen L, Van Hoey M, Dhubhghaill SN, Vermeulen L. Scleral lenses reduce the need for corneal transplants in severe keratoconus. *Am J Ophthalmol*. 2018;185:43-47.

ELISE KRAMER, OD, FAAO, FSLS, FBCLA

- Miami Contact Lens Institute, Florida
- elise@miamicontactlens.com

- Financial disclosure: Consultant (Allergan, Avellino, Contamac, Dompé, Orasis, RegenerEyes, RVL Pharmaceuticals, Visionary Optics)