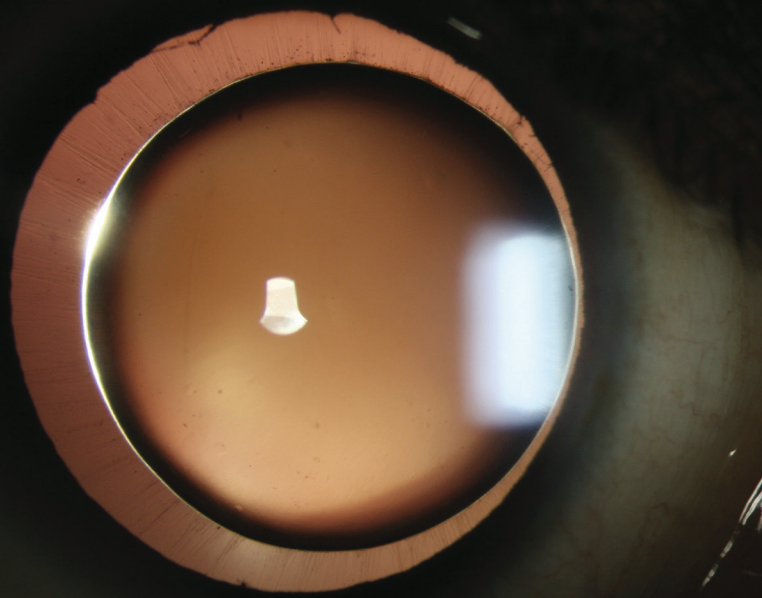

Courtesy of Haag-Streit USA; this image from Utpal Sarkar, BSC, won first prize in the 2022 Haag-Streit Slit Lamp Imaging Competition

Utpal Sarkar, Disha Eye Hospitals, India

# BILATERAL MICROSPHEROPHAKIA WITH HIGH MYOPIA



The increased anteroposterior thickness of the lens produced a diamond ring-like effect with retroillumination at the slit lamp.

BY UTPAL SARKAR, BSC, AND DEBASHISH BHATTACHARYA, CMD

A 30-year-old woman reported dim vision in both eyes. On examination, her BCVA was 6/9 OD with a manifest refraction of  $-24.00 -2.00 \times 50^\circ$  and 6/24 OS with a manifest refraction of  $-27.00 -1.50 \times 140^\circ$ .

A slit-lamp examination found microspherophakia (Figures), a deep

anterior chamber, and considerable phacodonesis in each eye. The IOP was 18 mm Hg OD and 20 mm Hg OS. Due to the increased anteroposterior thickness of the lens, the slit beam reflected off the posterior surface, producing a diamond ring-like effect with retroillumination that resembled a solar eclipse (main image).

The patient was referred to the retina department. An examination was normal and identified no peripheral retinal degeneration. A diagnosis of spontaneous lens dislocation and pupillary block glaucoma was made. A vitrectomy and lensectomy under local anesthesia were recommended, but the patient declined surgery. ■

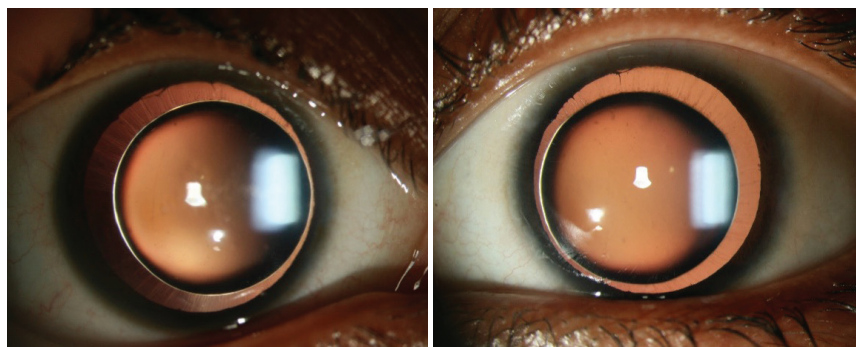


Figure. Bilateral microspherophakia with deep anterior chambers and considerable phacodonesis.

## DEBASHISH BHATTACHARYA, CMD

- Disha Eye Hospitals, Newtown Kolkata, India
- dbdish@gmail.com
- Financial disclosure: None

## UTPAL SARKAR, BSC

- Ophthalmic Technician, Disha Eye Hospitals, Newtown Kolkata, India
- utpalsarmi@gmail.com
- Financial disclosure: None