


**MINA A. FARAHANI, MD, MS, MS**

- Ophthalmic Consultants of Boston, Massachusetts
- [mina.a.farahani@gmail.com](mailto:mina.a.farahani@gmail.com)
- Financial disclosure: Consultant and speakers bureau (Oyster Point Pharma, Sight Sciences, Sun Pharma)



# OPTIMIZING THE Diseased Cornea

# Dry eye disease must be recognized and treated before cataract surgery.

By Mina A. Farahani, MD, MS, MS

Untreated ocular surface disease (OSD) can lead to inaccurate biometry measurements and refractive surprises after cataract surgery. Moreover, it can worsen significantly during the postoperative period. It is not uncommon for patients presenting to a dry eye clinic to state that cataract surgery caused their dry eye disease (DED). If DED is not discussed preoperatively, patients may view it as a surgical complication instead of a preexisting, chronic disease that waxes and wanes. A potential contributing factor is the frequent disconnect between OSD signs and symptoms.

All patients presenting for a cataract evaluation should be thoroughly assessed for OSD. They should also be educated that a healthy ocular surface promotes a successful refractive outcome and postoperative comfort. This article shares advice on DED diagnosis and management.

## IDENTIFYING DED

My technicians know that the initial workup at a cataract evaluation may turn into a dry eye consultation. In this situation, I see the patient before biometry measurements are obtained to ensure that the health of the ocular surface is adequate for testing and, ultimately, surgery. Administering a validated dry eye questionnaire such as the Standard Patient Evaluation of Eye Dryness or Ocular Surface Disease Index can help identify symptomatic individuals whose ocular surface may require optimization before cataract surgery.

Fluorescein staining is performed at the cataract consultation to identify preexisting keratopathy and increased tear breakup time (TBUT). Ideally, the assessment is performed before the patient receives a topical anesthetic or dilating drops, which may temporarily affect the ocular surface. When patients have risk factors for neurotrophic corneal disease or OSD signs that are out of proportion to their symptoms, this form of keratitis is part of the differential diagnosis.

Lid position and laxity are assessed because they can contribute to exposure keratopathy. A careful examination of the lids is crucial. Pay special attention to the lash margins and apply gentle pressure from a cotton-tipped applicator to diagnose meibomian gland dysfunction (MGD). Upper

lid collarettes can be missed if they are not looked for specifically (Figure). During the slit-lamp examination, the patient is instructed to look down, and the upper lid and lash margin are examined for collarettes that are characteristic of *Demodex* mites. The upper lid is then lifted and pressed on to characterize the meibum further.

## TREATMENT

For patients with visually significant cataracts, a rapid improvement in the health of the ocular surface is crucial to achieving a timely improvement in their vision and functioning. The ASCRS Clinical Cornea Committee 2019 algorithm outlines a streamlined approach to the diagnosis and treatment of OSD in the preoperative period.<sup>1</sup>

**Tear film homeostasis.** No matter the mechanism, a loss of tear film homeostasis is key to both aqueous deficient and evaporative DED. The loss leads to a cytokine cascade that must be addressed. A pulse early on of topical steroid eye drops such as loteprednol etabonate ophthalmic suspension 0.5% (Lotemax, Bausch + Lomb) or loteprednol etabonate ophthalmic suspension 0.25% (Eysuvis, Kala Pharmaceuticals) can help decrease ocular surface and tear film inflammation rapidly. This class of medication is not appropriate for the long-term management of DED owing to the risk of steroid-induced ocular hypertension and glaucoma. During the perioperative period, however,

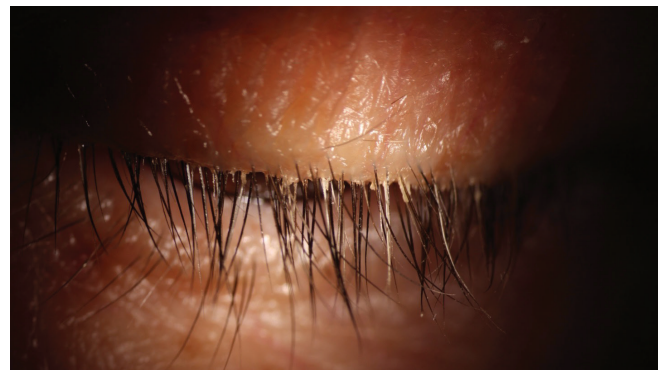

Figure. Collarettes along the upper lash line.

(Courtesy of Janssen Pharmaceuticals)

## “Identify OSD in patients before they are scheduled for cataract surgery and discuss the benefits of initiating treatment and optimizing the ocular surface.”

steroids can help restore the ocular surface so that patients may undergo cataract surgery more expeditiously.

DED is a chronic disease that requires long-term management after cataract surgery. I therefore typically prescribe steroids as a bridge to other treatments.

**Corneal staining and inflammation.** Eye drops or a nasal spray may be prescribed for the long-term management of DED in patients with corneal staining and inflammation. I prefer to start with cyclosporine ophthalmic emulsion 0.09% (Cequa, Sun Ophthalmics) because of its greater tolerability and quicker onset of action compared to cyclosporine ophthalmic emulsion 0.05% (Restasis, Allergan/AbbVie) and lifitegrast ophthalmic solution 5% (Xiidra, Novartis).<sup>2</sup>

I have found varenicline solution nasal spray 0.03 mg (Tyrvaya, Oyster Point Pharma) to be a helpful adjuvant, especially for patients with severe disease who have difficulty tolerating eye drops and individuals who may have difficulty instilling eye drops. The spray's exact mechanism of action is unknown, but it is believed to increase basal tear production and thereby decrease ocular cytokines via chemical neurostimulation, activating the parasympathetic pathway of the nasociliary branch of the trigeminal nerve in the nose. Varenicline nasal spray also has a quick onset of action. Studies have shown an increase in Schirmer scores 5 minutes after the first dose.<sup>3,4</sup>

**Tear evaporation.** A recently available targeted treatment for preoperative DED is perfluorohexyloctane ophthalmic solution (PFHO; Miebo, Bausch + Lomb). PFHO is indicated for the treatment of the signs and symptoms of DED with a focus on decreasing tear evaporation. The water-free, single-component, preservative-free drop is designed to create a monolayer within the lipid-to-air interface, spread rapidly across the ocular surface, and decrease tear evaporation. In clinical trials, PFHO significantly increased tear film and lipid layer thickness in 4 weeks compared to a control group.<sup>5</sup> The primary endpoints for the phase 3 clinical trials were a change in complete corneal staining and improvements in the visual analog scale for eye dryness. Patients who took PFHO experienced a clinical and statistical improvement in total corneal staining scores and symptoms of eye dryness as soon as day 15 and at the primary endpoint of day 57 when compared to patients in the control group. The product is administered four times per day and is expected to enter the US market before the end of the year.

**MGD and blepharitis.** Lid inflammation and obstruction can be addressed simultaneously to provide a meaningful benefit to patients with significant MGD. When discussing lid margin inflammation with them, I describe the options of drops, pills, and procedures. Topical steroids can help in the short term, as noted earlier.

Topical azithromycin can help decrease lid inflammation. Oral doxycycline, azithromycin, and omega-3 fatty acids all have a role in improving meibum quality and decreasing lid inflammation. Intense pulsed light therapy is a workhorse in my clinic for patients with significant inflammatory lid disease.

*Demodex* is a frequent cause of lid inflammation. As noted earlier, an examination of the upper lid margin is important to the proper diagnosis and management of blepharitis. In my practice, the mainstays of treatment for chronic *Demodex* are eyelid hygiene with procedures such as BlephEx (BlephEx) and cleansers containing tea tree oil such as Cliradex (Cliradex/Biotissue), Optase (Scope), and Oust (OcuSoft) to reduce collarettes and the mite population. Intense pulsed light therapy and, occasionally, the off-label use of topical ivermectin are offered to patients with significant *Demodex* blepharitis.

In July, the US FDA approved lotilaner ophthalmic solution 0.25% (Xdemy, Tarsus Pharmaceuticals) for *Demodex* blepharitis. Two randomized, multicenter, double-masked, vehicle-controlled studies, Saturn-1 and Saturn-2, demonstrated the product's efficacy in reducing collarettes, mites, and eyelid erythema.<sup>6,7</sup> Lotilaner ophthalmic solution is administered twice daily for 6 weeks. It has a favorable tolerability profile.

### **Meibomian gland obstruction.**

Warm compresses are the first-line treatment for relieving meibomian gland obstruction. Patient compliance and speed of resolution can be limiting factors, however, especially for individuals who wish to undergo cataract surgery soon. When discussing a home regimen, I often recommend The Best Ideal Temperature Dry Eye Relief Mask (Hammacher Schlemmer) to my patients.

Those of my patients who require a quicker improvement in MGD and TBUT have benefited from treatment with the TearCare system (Sight Sciences).

The ongoing randomized controlled SAHARA phase 1 clinical trial demonstrated a superior improvement in TBUT with the TearCare system compared to cyclosporine ophthalmic emulsion 0.05% at 6 months. TearCare was also noninferior to cyclosporine eye drops on the Ocular Surface Disease Index questionnaire.

My patients have tolerated TearCare treatment well. The system allows me to target meibomian gland obstruction more effectively and efficiently than

they can at home, even with an excellent heating mask and compliance with the prescribed treatment regimen.

### CONCLUSION

It is important to identify OSD in patients before they are scheduled for cataract surgery and make sure they understand the benefits of initiating treatment and optimizing the ocular surface. Patients should know they have a better chance of a successful refractive outcome and postoperative comfort if their ocular surface is healthy. ■

1. Starr CE, Gupta PK, Farid M, et al; ASCRS Cornea Clinical Committee. An algorithm for the preoperative diagnosis and treatment of ocular surface disorders. *J Cataract Refract Surg*. 2019;45(5):669-684.
2. de Oliveira RC, Wilson SE. Practical guidance for the use of cyclosporine ophthalmic solutions in the management of dry eye disease. *Clin Ophthalmol*. 2019;13:1115-1122.
3. Wirta D, Torkildsen GL, Boehmer B, et al. ONSET-1 phase 2b randomized trial to evaluate the safety and efficacy of OC-01 (varenicline solution) nasal spray on signs and symptoms of dry eye disease. *Cornea*. 2022;41(10):1207-1216.
4. Wirta D, Vollmer P, Paauw J, et al. Efficacy and safety of OC-01 (varenicline solution) nasal spray on signs and symptoms of dry eye disease: the ONSET-2 phase 3 randomized trial. *Ophthalmology*. 2022;129(4):379-387.
5. Tauber J, Berdy GJ, Wirta DL, Krösser S, Vittitow JL; GOBI Study Group. NOV03 for dry eye disease associated with meibomian gland dysfunction: results of the randomized phase 3 GOBI study. *Ophthalmology*. 2023;130(5):516-524.
6. Yeu E, Wirta DL, Karpecki P, Baba SN, Holdbrook M; Saturn I Study Group. Lotilaner ophthalmic solution, 0.25%, for the treatment of Demodex blepharitis: results of a prospective, randomized, vehicle-controlled, double-masked, pivotal trial (Saturn-1). *Cornea*. 2023;42(4):435-443.
7. Gaddie IB, Donnenfeld ED, Karpecki P, et al; Saturn-2 Study Group. Lotilaner ophthalmic solution 0.25% for Demodex blepharitis: randomized, vehicle-controlled, multicenter, phase 3 trial (Saturn-2). *Ophthalmology*. Published online June 5, 2023. doi:10.1016/j.ophtha.2023.05.030