

PERSISTENTLY BLURRED VISION AFTER LASIK

What are the options for a patient with extended depth of focus IOLs, open posterior capsules, and a history of refractive surgery?

BY AUDREY R. TALLEY ROSTOV, MD; BEN LAHOOD, MBCHB, PGDIPOPHTH, PHD, FRANZCO, FWCRS; AND RAHUL S. TONK, MD, MBA

CASE PRESENTATION

A 61-year-old man presents for a cataract evaluation. The patient, a physician, underwent LASIK using a mini-monovision strategy in 2005. His right eye was targeted for distance vision and his left eye for near.

After a discussion of his goals and options, the patient opts for an extended depth of focus (EDOF) IOL in each eye with a mini-monovision strategy targeting distance and midrange vision in the right eye and near vision in the left eye. The refractive aim is plano and -0.50 D in the right and left eyes, respectively. Uneventful delayed sequential bilateral laser cataract surgery with implantation of an AcrySof IQ Vivity IOL (Alcon) is performed on each eye 1 week apart.

Postoperatively, the patient experiences blurry vision at all distances that is worse in the right eye. His UCVA is 20/50- OD and 20/40 OS, and his uncorrected near visual acuity is J2 OU. His BCVA is 20/20 OD with a refraction of -1.25 + 0.75 x 120° and 20/20 OS with a refraction of -0.75 + 0.50 x 105°. He describes ghosting in the right eye (Figure 1).

Treatment with topical lifitegrast and preservative-free artificial tears is initiated. After 3 months of therapy, his refraction and measurements with the Pentacam (Oculus Optikgeräte) are unchanged. A slit-lamp examination reveals

mild posterior capsular opacification that is more severe in the right eye. Both eyes receive an Nd:YAG laser capsulotomy. Six months after cataract surgery, the patient undergoes topography-guided PRK on the right eye.

At 18 months after the initial cataract procedures, the patient's UCVA is 20/25 OD, and his BCVA is 20/20 with a refraction of -0.50 + 0.50 x 010° OD. A contact lens overrefraction achieves no improvement (Figure 2). On examination, both IOLs are well centered, and the capsule in each eye is open. Macular OCT and a retinal examination in each eye are normal. The ocular surface of each eye is also normal with no staining, and the patient continues to administer lifitegrast and preservative-free artificial tears. He is unhappy with his UCVA, particularly in his right eye. He states that the quality of his near vision is acceptable.

How would you proceed? Would you advise the patient to allow more time for neural adaptation? Recommend additional PRK? Perform an IOL exchange? How would you counsel the patient, who is anxious to improve his vision?

— Case prepared by Audrey R. Talley Rostov, MD

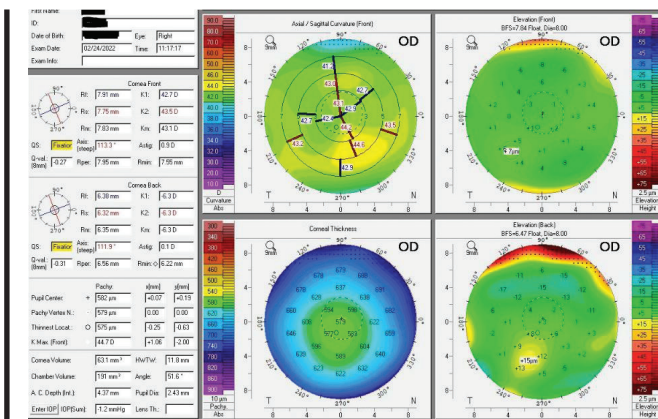


Figure 1. Measurements of the right eye with the Pentacam after cataract surgery.

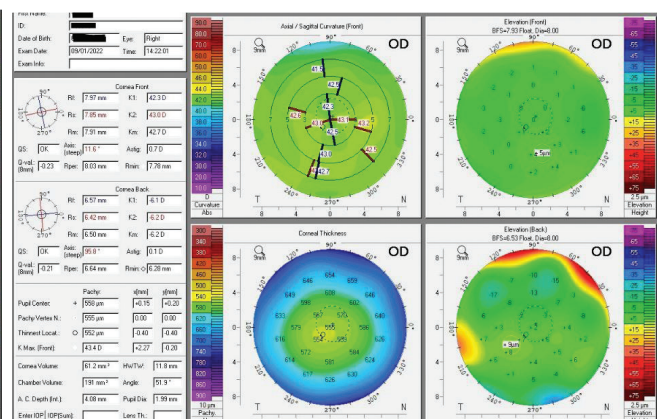


Figure 2. Measurements of the right eye with the Pentacam after a PRK enhancement.



**BEN LAHOOD, MBCHB, PGDIPOPHTH,
PHD, FRANZCO, FWCRS**

Corneal tomography shows a thick central cornea. I suspect the patient received hyperopic LASIK and then experienced regression. The asymmetry in the myopic surprise may coincide with the asymmetric degree of hyperopia treated with LASIK to provide monovision. Hyperopic LASIK often induces negative spherical aberration—a factor to consider during IOL selection. With an EDOF IOL, for example, aberrations must be combined in a positive way. I find it helpful to take the posterior-anterior curvature ratio into account when performing the IOL calculation for an eye that has undergone laser vision correction. It is unclear whether that occurred in this case.

Both corneas appear to be regular with no signs of ectasia. The contact lens overrefraction yielded no improvement in vision quality, leading me to suspect that the EDOF IOL is ill suited to the patient. An analysis of corneal higher-order aberrations would be obtained before a replacement IOL is selected. The refractive assessment would be conducted by either an experienced optometrist or myself.

The patient is satisfied with his near vision, so the left eye would be left alone. The vision in the distance eye, however, must be improved. An IOL exchange is indicated, but the open capsule may make surgery challenging. IOLs for sulcus and scleral fixation would be available in the OR. Monofocal distance vision would be targeted. Preoperatively, I would explain to the patient that he may require a laser enhancement in the future. Informed consent would be obtained before proceeding.

Thankfully, a toric IOL seems unnecessary. If possible, an IOL that can improve or at least will not worsen

the current corneal aberration profile would be implanted.



RAHUL S. TONK, MD, MBA

Cataract surgery can be challenging in eyes that previously underwent LASIK. Achieving a specific refractive target can be difficult, particularly if monovision is the objective. Presbyopia-correcting IOLs, moreover, may perform inconsistently in eyes with corneal aberrations.

I agree with the surgeon's initial course of action: optimize the ocular surface, promote neural adaptation, and reduce the residual refractive error and corneal aberrations with topography-guided PRK.

Despite his 20/25 UCVA, 20/20 BCVA, and minimal residual refractive error, the patient remains dissatisfied with the vision in his right eye. The lack of improvement with a rigid gas permeable contact lens overrefraction suggests intolerance of the EDOF IOL.

Options include an IOL exchange in the right eye, ideally for a Light Adjustable Lens (LAL; RxSight), or ongoing conservative management. An IOL exchange may increase the patient's need for glasses, especially at near. The open posterior capsule increases the risk of vitreoretinal complications.

I would attempt to dissuade the patient from undergoing surgery—perhaps by reimbursing the premium IOL fees or offering complimentary eyeglasses. If an IOL exchange is elected, infusion would be established through an anterior chamber maintainer. A pars plana trocar would be placed, through which the anterior vitreous would be prophylactically removed. Viscodissection would be performed to free the IOL from the capsular bag. If that fails, the haptics would be amputated and left behind. A three-piece LAL would then be placed

in the ciliary sulcus and the optic captured if possible. Postoperatively, light treatment(s) would be performed to achieve a plano refraction or the patient's preferred target.



**WHAT I DID: AUDREY R.
TALLEY ROSTOV, MD**

After a lengthy discussion with the patient and exhausting all options for improvement with his current EDOF IOL, an IOL exchange and vitrectomy were performed on the right eye, and an LAL was placed in the sulcus with optic capture.

Postoperatively, two light adjustments were performed. The patient's UCVA was 20/20 OD, and his BCVA was 20/15 OD with a -0.25 D refraction.

He is happy with his vision and has deferred IOL exchange in his left eye. ■

SECTION EDITOR AUDREY R. TALLEY ROSTOV, MD

- Private practice, Northwest Eye Surgeons, Seattle
- Affiliate surgeon, Himalayan Cataract Project/Cure Blindness
- Member, CRST Editorial Advisory Board
- atalleyrostov@nweyes.com
- Financial disclosure: Consultant (Alcon, Bausch + Lomb, Carl Zeiss Meditec)

**BEN LAHOOD, MBCHB, PGDIPOPHTH, PHD,
FRANZCO, FWCRS**

- Ophthalmic surgeon, The Queen Elizabeth Hospital, Adelaide, Australia
- Adelaide Eye & Laser Centre and Parkview Day Surgery, Adelaide, Australia
- Member, CRST Global Advisory Board
- ben@drbenlahood.com
- Financial disclosure: Consultant (Alcon, Carl Zeiss Meditec); Honoraria (Rayner)

RAHUL S. TONK, MD, MBA

- Assistant Professor of Clinical Ophthalmology, Associate Medical Director, and Cornea Fellowship Codirector, Bascom Palmer Eye Institute, Miami
- rtonk@med.miami.edu
- Financial disclosure: None