

BLEPHARITIS AND *DEMODEX*

Insights into the pathophysiology and management of these conditions.

BY ANNY M.S. CHENG, MD, AND ANAT GALOR, MD, MSPH

Blepharitis is a multifactorial condition with diverse clinical presentations, including lash debris and meibomian gland dysfunction (MGD).¹ Its etiologies include allergies, staphylococcal infection, seborrheic dermatitis, rosacea, and *Demodex* infestation.¹

The association between blepharitis and *Demodex* was first described in 1959,² and it remains well supported. A 2020 meta-analysis identified ocular *Demodex* in 29% to 90% of individuals with symptomatic blepharitis.³ The mites are more common in patients with blepharitis than in those without the condition (odds ratio, 2.5).⁴

This article explores the pathophysiology and management of *Demodex* blepharitis (DB).

EPIDEMIOLOGY AND RISK FACTORS FOR DB

DB affects patients of both sexes and all ethnicities. In a cross-sectional study of adults in South Florida (n = 119), DB was identified in 72%, 65%, and 69% of White, Black, and Hispanic individuals, respectively.⁵

The frequency of DB increases with age. A Polish hospital-based study of 435 patients identified DB in 95% of individuals 71 years of age or older, 87% of those 51 to 70 years of age, and 13% of those 3 to 15 years of age.⁶ Similar findings were reported in another Polish hospital-based study of 1,499 patients, which identified DB in 77% of individuals 70 years of age or older and 8% of those 25 years of age or younger.⁴

DB is uncommon in pediatric patients but is more prevalent among children with specific risk factors.⁷ A multisite (United States and China) study conducted in hospitals and private practices reported a 12% prevalence of DB among healthy children (n = 1,575; 3–14 years of age). The frequency was higher among immunocompromised children (n = 131), particularly those who were malnourished (25%) or had cancer (32%).⁸

CLINICAL PRESENTATION AND ASSOCIATED CONDITIONS

DB is associated with various skin, eyelid, and ocular surface conditions beyond eyelash debris, including rosacea,⁴ chalazia, MGD, and tear film instability.⁵ In a South Florida hospital-based population (n = 119), concurrent DB was identified in 70% of individuals diagnosed with dry eye disease based on a Schirmer test score of 5 mm or less in at least one eye or eyelid margin abnormalities (eg, vascular engorgement, plugged orifices, and poor meibum expression).⁵

Advanced DB may involve the conjunctiva and cornea and present as punctate epithelial erosions, infiltrates, corneal neovascularization, scarring, or blepharokeratoconjunctivitis. Patients with DB may be asymptomatic or report ocular pain, itching, burning, and/or a foreign body sensation. Additional symptoms include tearing, red eyes, crusting of the eyelids and eyelashes, and blurred vision. Itching is the symptom most closely associated with DB.^{5,9,10} A Japanese study of 553 individuals reported itching in 40% of patients with DB compared with 26% of those without it.⁹ A Turkish study of 67 patients reported rates of 64% and 14%, respectively.¹⁰ Positive correlations between the severity of itching and *Demodex* mite counts have also been documented.^{5,11}

The overlap of symptoms and signs between DB and other forms of ocular surface disease can delay its diagnosis and treatment. Including an assessment for DB signs is therefore recommended as part of routine ocular examinations.¹²

DIAGNOSTIC CHALLENGES

The gold standard for diagnosing DB is eyelash epilation with light microscopy.¹³ However, access to the necessary equipment in clinical settings is often limited, and no standardized techniques for sampling lashes exist.

Alternative methods include in vivo laser confocal microscopy¹⁴ and high-definition OCT.¹⁵ Challenges

with these approaches include the high reflectivity of the substantia propria and the potential for misinterpretation. Most cases of DB are diagnosed via slit-lamp observation of pathognomonic cylindrical dandruff (CD) alone (Figure 1).^{12,16}

The association between DB and CD—the most common clinical finding¹⁷—was first documented in 1963, when numerous *Demodex* mites were identified via microscopic examination in a patient with severe blepharitis.¹⁸ Subsequently, some eye care providers began referring to CD as *collarettes*.^{12,19} It is important to note, however, that collarettes are not specific to DB.²⁰ The term is also applied to *Staphylococcus*-related diseases. *Demodex* collarettes present as gelatinous scales encircling the lash root,¹⁷ whereas *Staphylococcus*-related collarettes appear as greasy scales clinging to the lash shaft, away from the root.²¹

CD is readily identifiable at the slit lamp. Directing patients to look downward or upward provides a clear view of the base of the upper and lower lash margins, respectively.

PATHOPHYSIOLOGY OF CD

CD is considered pathognomonic for DB due to several hypothesized mechanisms involving the behavior of *Demodex folliculorum* and *Demodex brevis*. *D folliculorum* is strongly

associated with anterior blepharitis, whereas *D brevis* is linked to MGD, recurrent chalazia, and refractory keratitis.^{7,13} Their distinct behaviors—mechanical irritation by *D folliculorum* and deeper glandular penetration by *D brevis*—are implicated in DB pathogenesis.

Pathogenic Mechanisms of *D Folliculorum*

D folliculorum resides in eyelash follicles and roots (Figure 2), where its claws mechanically irritate the follicular epithelium. This irritation induces epithelial hyperplasia around the lash base, leading to reactive hyperkeratinization. The accumulation of keratin and epithelial cells presents as CD. A histopathologic study of biopsied eyelid tissues confirmed associations between *D folliculorum*, eyelid hyperkeratinization, and perifollicular inflammation.²²

Pathogenic Mechanisms of *D Brevis*

Unlike *D folliculorum*, *D brevis* inhabits the deeper regions of meibomian and sebaceous glands. The mite's chitinous exoskeleton acts as a foreign body, eliciting granulomatous reactions within the meibomian glands. These reactions contribute to MGD and lipid tear insufficiency.²³

Role of Bacteria in DB

Bacteria carried by *Demodex* may also contribute to DB pathology. *Bacillus*

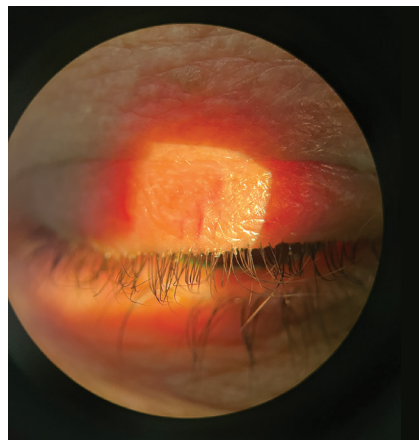


Figure 1. Slit-lamp image showing CD encircling the base of the eyelashes.

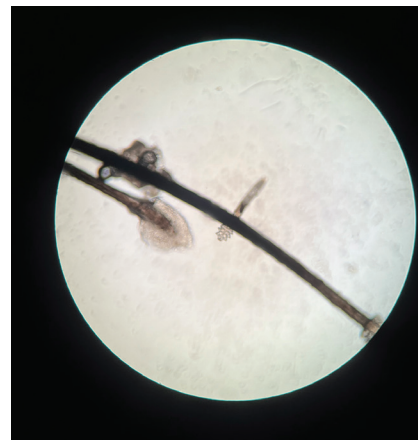

Figure 2. Microscopic view of *D folliculorum* attached to an eyelash.



oleronius, a bacterium found in the digestive tract of *Demodex*, has been implicated in immune responses. In one in vitro serum immunoreactivity experiment, human serum exposed to *B oleronius* protein extractions (83 kDa and 62 kDa) demonstrated positive immunoreactive bands, suggesting that bacteria associated with *Demodex* can trigger immune responses.²⁴ Another in vitro study showed that purified *B oleronius* proteins activated neutrophils, increasing inflammatory cytokine production and promoting neutrophil migration and degranulation.²⁵

Additionally, a polysaccharide biofilm produced by bacteria on periocular skin or eyelashes may protect *Demodex* from white blood cells, antibiotics, and povidone-iodine scrubs. This biofilm may also serve as a nutrient source for *Demodex*.²⁶

Demodex contributes to DB through direct mechanical and inflammatory damage as well as by serving as a vector for bacteria. Although these hypotheses provide biologic plausibility, further studies are necessary to elucidate the exact pathologic mechanisms underlying DB.

TREATMENT OPTIONS

Eyelid Hygiene

Eyelid hygiene is a foundational approach to managing DB. Regular cleansing of the eyelid margins removes debris and inflammatory secretions. Eyelid scrubs containing tea tree oil (TTO), particularly those with terpinen-4-ol as the active component, have demonstrated efficacy against DB due to their antifungal, antimicrobial, antiviral, acaricidal, and antiseptic properties.^{27,28} The precise mechanism of TTO's action on DB remains unknown. Although generally well tolerated, TTO can occasionally cause irritation, hypersensitivity, and conjunctivitis.

Ivermectin

Topical and systemic ivermectin works by blocking glutamate- or

gamma-aminobutyric acid-gated chloride channels, keeping them open, preventing synaptic electrical impulses, and ultimately paralyzing the organism.²⁹ Side effects of topical ivermectin include irritation and erythema, whereas systemic ivermectin may cause headache, pruritus, muscle pain, cough, dyspnea, nausea, vomiting, diarrhea, blurred vision, postural hypotension, confusion, and, in rare cases, serious skin reactions and swelling.³⁰

Intense Pulsed Light

Intense pulsed light (IPL) therapy, an in-office procedure, affects *Demodex* viability by delivering heat that induces coagulation necrosis. IPL also improves meibum quality and expressibility and may inhibit rosacea-like inflammatory reactions.³¹

Although eyelid hygiene, ivermectin, IPL, and other traditional therapies can reduce *Demodex* colonization, mites cannot be completely eradicated with a single treatment modality.³² A 2019 meta-analysis comparing topical TTO, topical terpinen-4-ol, pilocarpine gel, oral ivermectin, and oral metronidazole found local and systemic treatments had comparable efficacy.³³ The effect sizes for *Demodex* eradication rates were 0.37 versus 0.56 ($P > .05$), and for symptom improvement, they were 0.77 versus 0.67 ($P > .05$).³³

Lotilaner Ophthalmic Solution

The US FDA recently approved lotilaner ophthalmic solution 0.25% for treating *Demodex*. This gamma-aminobutyric acid-gated chloride channel inhibitor is specific to *Demodex* and causes paralysis and death of the organism.³⁴ The drug's efficacy was demonstrated in two phase 3 randomized, multicenter, double-masked, vehicle-controlled trials (SATURN-1 and SATURN-2). Patients were treated with lotilaner twice daily for 6 weeks, which achieved *Demodex* eradication rates of 67.9% in SATURN-1 and 51.8% in SATURN-2 compared to 17.6% and 14.6% in the control groups.

Side effects were generally mild, with transient eye irritation being the most commonly reported. At a 1-year follow-up visit, 23.5% of patients receiving lotilaner ($n = 128$) and 2.9% of controls ($n = 111$) had CD of two or lower. No serious ocular adverse events were reported, but one patient experienced mild treatment-related blurred vision.³⁵ Ongoing studies are evaluating the long-term safety, durability of treatment effects, and the drug's impact on associated ocular conditions.

THE FUTURE OF DEMODEX MANAGEMENT

DB is highly prevalent among older adults and has been associated with a variety of ocular surface conditions. Determining when *Demodex* acts as a benign colonizer versus a pathogenic contributor to ocular symptoms and signs remains challenging. Routine clinical assessment for DB signs, particularly CD, and heightened vigilance for the condition's hallmark symptom of itching are essential for accurate diagnosis and effective management.

Although lotilaner provides a targeted treatment option, ongoing research into *Demodex* pathophysiology, the environmental factors influencing mite proliferation, and new management strategies holds promise for further improving patient care. ■

1. Yeu E, Garg S, Ayres BD, et al; from the ASCRS Cornea Clinical Committee. Current state and future perspectives in the diagnosis of eyelid margin disease: clinical review. *J Cataract Refract Surg*. 2024;50(8):868-875.
2. Rodger FC, Farooqi HU. Lesions of the lid margins caused by ectoparasites in India. *Br J Ophthalmol*. 1959;43(11):676-680.
3. Zhang AC, Muntz A, Wang MTM, Craig JP, Downie LE. Ocular *Demodex*: a systematic review of the clinical literature. *Ophthalmic Physiol Opt*. 2020;40(4):389-432.
4. Sedzikowska A, Oseka M, Skopiński P. The impact of age, sex, blepharitis, rosacea and rheumatoid arthritis on *Demodex* mite infection. *Arch Med Sci*. 2018;14(2):353-356.
5. Cheng AM, Hwang J, Dermer H, Galor A. Prevalence of ocular demodicosis in an older population and its association with symptoms and signs of dry eye. *Cornea*. 2021;40(8):995-1001.
6. Czepita D, Kuźna-Grygiel W, Kosik-Bogacka D. Investigations on the occurrence as well as the role of *Demodex folliculorum* and *Demodex brevis* in the pathogenesis of blepharitis. Article in Polish. *Klin Oczno*. 2005;107(1-3):80-82.
7. Luo X, Li J, Chen C, Tseng S, Liang L. Ocular demodicosis as a potential cause of ocular surface inflammation. *Cornea*. 2017;36 suppl 1(suppl 1):S9-S14.
8. Kaya S, Selimoglu MA, Kaya DA, Ozgen U. Prevalence of *Demodex folliculorum* and *Demodex brevis* in childhood malnutrition and malignancy. *Pediatr Int*. 2013;55(1):85-89.
9. Biernat MM, Rusiecka-Ziółkowska J, Piątkowska E, Helemejko I, Biernat P, Gościński G. Occurrence of *Demodex* species in patients with blepharitis and in healthy individuals: a 10-year observational study. *Jpn J Ophthalmol*. 2018;62(6):628-633.
10. Kabatas N, Doğan AS, Kabatas EU, Acar M, Bicer T, Gürdal C. The effect of *Demodex* infestation on blepharitis and the ocular symptoms. *Eye Contact Lens*. 2017;43(1):64-67.
11. Gao YY, Xu DL, Huang U, Wang R, Tseng SC. Treatment of ocular itching associated with ocular demodicosis by 5% tea tree oil ointment. *Cornea*.

2012;31(0):14-17.

12. Ayres BD, Donnenfeld E, Farid M, et al. Clinical diagnosis and management of *Demodex* blepharitis: the *Demodex* Expert Panel on Treatment and Eyelid Health (DEPH). *Eye (Lond)*. 2023;37(15):3249-3255.

13. Cheng AM, Sheha H, Tseng SC. Recent advances on ocular *Demodex* infestation. *Curr Opin Ophthalmol*. 2015;26(4):295-300.

14. Sattler EC, Maier T, Hoffmann VS, Hegyi J, Ruzicka T, Berking C. Noninvasive in vivo detection and quantification of *Demodex* mites by confocal laser scanning microscopy. *Br J Dermatol*. 2012;167(5):1042-1047.

15. Maier T, Sattler E, Braun-Falco M, Ruzicka T, Berking C. High-definition optical coherence tomography for the in vivo detection of *Demodex* mites. *Dermatology*. 2012;225(3):271-276.

16. Trattler W, Karpecki P, Rapoport Y, et al. The prevalence of *Demodex* blepharitis in US eye care clinic patients as determined by collarettes: a pathognomonic sign. *Clin Ophthalmol*. 2022;16:1153-1164.

17. Gao YY, Di Pascuale MA, Li W, et al. High prevalence of *Demodex* in eyelashes with cylindrical dandruff. *Invest Ophthalmol Vis Sci*. 2005;46(9):3089-3094.

18. Post CF, Juhlín E. *Demodex* folliculorum and blepharitis. *Arch Dermatol*. 1963;88:298-302.

19. Rhee MK, Yeu E, Barnett M, et al. *Demodex* blepharitis: a comprehensive review of the disease, current management, and emerging therapies. *Eye Contact Lens*. 2023;49(8):311-318.

20. Cheng AM, Galar A, Banoub R, Gupta SK. The impact of ocular demodicosis on the eyes. *Eye (Lond)*. 2023;37(15):3061-3062.

21. Bitton E, Aumond S. *Demodex* and eye disease: a review. *Clin Exp Optom*. 2021;104(3):285-294.

22. Scheer MJ, Milman T, Steiner T, Shih C, Udell II, Steiner A. The association of *Demodex* with chalazia: a histopathologic study of the eyelid. *Ophthalmic Plast Reconstr Surg*. 2016;32(4):275-278.

23. Nicholls SG, Oakley CL, Tan A, Vote BJ. *Demodex* species in human ocular disease: new clinicopathological aspects. *Int Ophthalmol*. 2017;37(1):303-312.

24. Li J, O'Reilly N, Sheha H, et al. Correlation between ocular *Demodex* infestation

and serum immunoreactivity to *Bacillus* proteins in patients with facial rosacea. *Ophthalmology*. 2010;117(5):870-877.e1.

25. O'Reilly N, Bergin D, Reeves EP, McElvaney NG, Kavanagh K. *Demodex*-associated bacterial proteins induce neutrophil activation. *Br J Dermatol*. 2012;166(4):753-760.

26. Rynerson JM, Perry HD. DEBS - a unification theory for dry eye and blepharitis. *Clin Ophthalmol*. 2016;10:2455-2467.

27. Yin HY, Tighe S, Tseng SC, Cheng AM. Successful management of chronic blepharo-rosacea associated *Demodex* by lid scrub with terpinen-4-ol. *Am J Ophthalmol Case Rep*. 2021;23:101171.

28. Tighe S, Gao YY, Tseng SCG. Terpinen-4-ol is the most active ingredient of tea tree oil to kill *Demodex* mites. *Transl Vis Sci Technol*. 2013;2(7):2.

29. Choi Y, Eom Y, Yoon EG, Song JS, Kim IH, Kim HM. Efficacy of topical ivermectin 1% in the treatment of *Demodex* blepharitis. *Cornea*. 2022;41(4):427-434.

30. Campillo JT, Boussinesq M, Bertout S, Faillie JL, Chesnais CB. Serious adverse reactions associated with ivermectin: a systematic pharmacovigilance study in Sub-Saharan Africa and in the rest of the world. *PLoS Negl Trop Dis*. 2021;15(4):e0009354.

31. Niu X, Wu S, Xia G, Xu M. Evaluating the role of *Demodex* infestation and meibomian gland dysfunction in recurrent corneal erosion syndrome. *Sci Rep*. 2024;14(1):22180.

32. Chioveanu FG, Niculet E, Torlac C, Busila C, Tatu AL. Beyond the surface: understanding *Demodex* and its link to blepharitis and facial dermatoses. *Clin Ophthalmol*. 2024;18:1801-1810.

33. Navel V, Mulliez A, Benoist d'Azy C, et al. Efficacy of treatments for *Demodex* blepharitis: a systematic review and meta-analysis. *Ocul Surf*. 2019;17(4):655-669.

34. Page MR. Multidisciplinary perspectives in *Demodex* blepharitis: a new view of treatment from clinical, payer, and patient perspectives. *J Manag Care Spec Pharm*. 2024;30(10-a suppl):S1-S8.

35. Sadri E, Paauw JD, Ciolino JB, et al. Long-term outcomes of 6-week treatment of lotilaner ophthalmic solution, 0.25%, for *Demodex* blepharitis: a noninterventional extension study. *Cornea*. 2024;43(11):1368-1374.

ANNY M.S. CHENG, MD

- Department of Ophthalmology, Broward Health, Fort Lauderdale, Florida
- Department of Ophthalmology, Florida International University, Herbert Wertheim College of Medicine, Miami
- Financial disclosure: None

ANAT GALOR, MD, MSPH

- Department of Ophthalmology, Miami Veterans Administration Medical Center, Miami
- Department of Ophthalmology, Bascom Palmer Eye Institute, University of Miami, Miami
- agalar@med.miami.edu
- Financial disclosure: Consultant (Alcon, Bausch + Lomb, Dompé, Novaliq, Novartis, Tarsus Pharmaceuticals)