

REFRACTIVE TREATMENT OPTIONS AFTER RADIAL KERATOTOMY

Irregular corneal curvature and amblyopia add to the complexity.

BY SUPHI TANERI, MD, PHD, FEBOS-CR; ALFREDO BORGIA, MD, FEBO; AND MONTSERRAT GARCIA-GONZALEZ, MD, PHD, FEBOS-CR

CASE PRESENTATION

A 60-year-old woman presents for a refractive lens surgery consultation. The patient's manifest refraction is -6.25 $-2.25 \times 160^\circ = 0.63$ OD and -3.50 $-4.00 \times 154^\circ = 0.5$ OS. Her history is significant for an approximately -10.00 D radial keratotomy (RK) procedure performed on her left eye more than 30 years ago, and she says the eye is amblyopic.

An examination of the anterior segment of each eye reveals clear corneas. Eight radial cuts without epithelial ingrowth are observed in the left eye (Figure 1). Both crystalline lenses exhibit slight nuclear sclerosis. The optic

nerves and retinas are healthy. The patient reports no other ocular surgeries or diseases.

Imaging with the Pentacam AXL (Oculus Optikgeräte; Figure 2) shows a normal corneal anterior curvature in the right eye and an irregular cornea in the left eye, as expected after RK. The total corneal refractive power within the central 3-mm zone is 2.70 D OU.

How would you proceed?

—Case prepared by Suphi Taneri, MD, PhD, FEBOS-CR

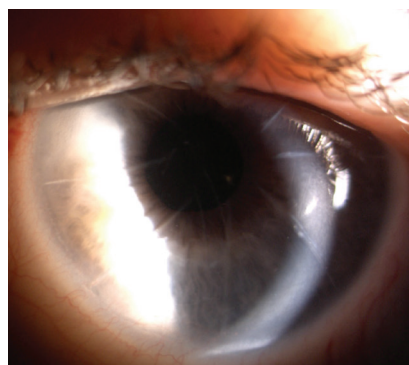


Figure 1. Eight RK incisions without epithelial ingrowth are visible in the left eye.

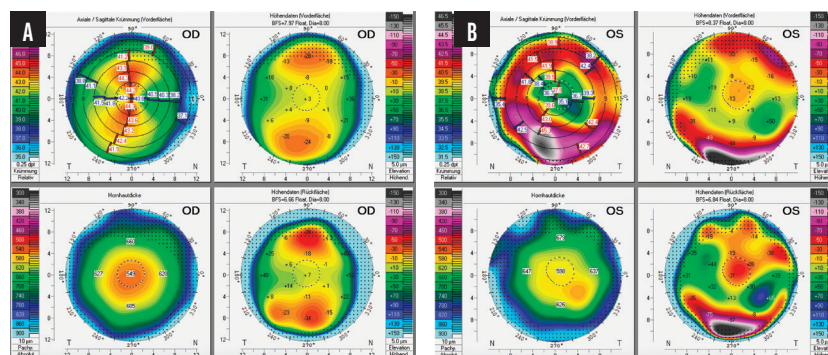


Figure 2. The anterior curvature of the cornea is normal in the right eye (A) and irregular in the left eye (B).



ALFREDO BORGIA, MD, FEBO

The refractive error in each eye is moderate to high, but the left eye has significant higher-order aberrations (HOAs) due to RK. The irregular cornea and possible ectasia in the left eye, as evidenced by high anterior and posterior elevation values and increased

corneal curvature at the thinnest point, necessitate a careful evaluation.

Lens surgery on a patient who has a history of RK warrants a detailed discussion, particularly regarding the risk of stromal wound dehiscence during surgery. An overrefraction with a rigid gas permeable (RGP) lens would be performed to assess the visual potential of the left eye and gauge the impact of HOA reduction on perceived vision quality.¹ If the patient's visual acuity is better than 0.5 LogMAR with an RGP contact lens, sequential customized

therapeutic keratectomy followed by flash CXL could improve the shape of the cornea.² After stabilization, the need for lens surgery in her left eye would be reassessed.

Surgical intervention could be considered for the right eye to manage anisometropia after treatment of the left eye. I would perform a refractive lens exchange with a toric IOL only if a posterior vitreous detachment is confirmed, given the approximately one in 50 risk of a retinal detachment in eyes that have an axial length greater

than 26 mm.³ Otherwise, if the patient's corrected distance visual acuity (CDVA) remains 0.0 LogMAR OD, a presbyopic femto-LASIK procedure could be considered.

Close monitoring, patient education, and staged intervention are essential for optimizing outcomes and mitigating risks in this complex situation.



MONTSERRAT GARCIA-GONZALEZ, MD, PHD, FEBOS-CR

In the right eye, topography shows with-the-rule regular astigmatism (Figure 2A) that could be corrected with a toric IOL. The patient's CDVA, however, seems quite low given that she has only slight nuclear sclerosis and the ocular examination is normal. A high preoperative refractive error may be inducing some degree of amblyopia. I would therefore recommend a toric monofocal IOL targeted for emmetropia.

Corneal irregularity in the left eye secondary to RK (Figure 2B) contraindicates the implantation of a toric or multifocal IOL, so I would recommend a nontoric monofocal IOL. Depending on the patient's final CDVA, an RGP contact lens fitting could be conducted to improve her visual acuity. Another option would be to implant a small-aperture IOL to enhance her quality of vision by reducing some of the corneal HOAs and improving her intermediate visual acuity by increasing the eye's depth of focus, especially if slight myopia is targeted.

The patient would be counseled on the reduced accuracy of IOL formulas in post-RK eyes and potentially slower visual rehabilitation.

During surgery, a 2.2-mm clear corneal incision could be made to avoid transecting the RK incisions. If, however, the space between RK incisions is too narrow to permit the safe creation of a

corneal incision, a scleral tunnel would be a better approach.



WHAT I DID: SUPHI TANERI, MD, PHD, FEBOS-CR

Prior RK for the reduction of anisometropia in the amblyopic left eye made this case remarkable. Fortunately, although additional surgical intervention was not required to address epithelial plugs or gaping, the RK incisions were nevertheless causing irregular astigmatism and poor subjective quality of vision. The decreased refractive predictability of refractive lens exchange and reduced postoperative vision expected in the left eye were thoroughly discussed with the patient.

A small-aperture lens (IC-8 Aphthera, Bausch + Lomb) with a -2.00 D refractive target was implanted in the left eye to optimize the retinal image (Figure 3). Intraoperatively, care was taken to place the 3.5-mm limbal tunnel incision between two RK incisions without touching them. Six weeks later, a toric monofocal IOL (Ankoris, PhysIOL) with a distance target was implanted in the right eye.

Five days after surgery on the second eye, the patient's corrected distance visual acuity was plano -0.25 x 13° = 0.8 OD and -0.50 -1.00 x 167° = 0.5 OS. She was happy with the result and reported a subjective improvement in her uncorrected and corrected binocular vision at all distances.

The Aphthera lens was originally designed to correct presbyopia by increasing depth of focus. Theoretically, the IOL's small aperture can improve quality of vision in eyes with irregular corneas due to RK, trauma, or keratoconus by allowing only paraxial light rays to reach the retina. The successful outcome in this case

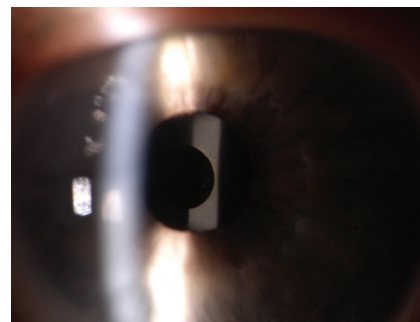


Figure 3. A small-aperture IOL reduces the effective pupil size and perceived HOAs in an eye with an irregular cornea from an RK procedure performed 30 years earlier. This slit-lamp photograph was obtained 10 days after implantation.

notwithstanding, my results with the Aphthera lens have been mixed in eyes with irregular corneas, and patient satisfaction has varied, as H. Burkhard Dick, MD, and I discuss in a chapter we contributed to the forthcoming third edition of the textbook *Multifocal Intraocular Lenses: The Art and the Practice*, edited by Jorge L. Alió, MD, PhD, FEBOPht. ■

1. Gu Y, Xie C, Tong J, Hong N, Shen Y. Pre-operative visual evaluation for implantable collamer lenses in highly myopic eyes. *Clin Exp Optom*. 2014;97(6):516-522.
2. Vinciguerra R, Catania F, Rosetta P, Archer TJ, Reinsteint DZ, Vinciguerra P. Sequential customized therapeutic keratectomy in patients with a history of radial keratotomy. *J Refract Surg*. 2023;39(12):808-816.
3. Sheu SJ, Ger LP, Ho WL. Late increased risk of retinal detachment after cataract extraction. *Am J Ophthalmol*. 2010;149(1):113-119.

SECTION EDITOR SUPHI TANERI, MD, PHD, FEBOS-CR

- Director, Center for Refractive Surgery, Münster, Germany
- Professor of Ophthalmology, Ruhr-University Bochum, Germany
- Member, CRST Global Editorial Advisory Board
- taneri@refraktives-zentrum.de
- Financial disclosure: Consultant (Bausch + Lomb)

ALFREDO BORGIA, MD, FEBO

- Cornea Unit, "Mons. Dimiccoli" Hospital, Barletta, Italy
- alfr.borgia@gmail.com
- Financial disclosure: None

MONTSERRAT GARCIA-GONZALEZ, MD, PHD, FEBOS-CR

- Cataract and refractive surgeon, Clínica Rementería, Madrid
- Cataract and Refractive Surgeon, Clínica Novovisión, Madrid
- montseggonz@gmail.com
- Financial disclosure: Consultant (Alcon)